

Three-dimensional printing of the fetal heart with complete atrioventricular septal defect based on ultrasound data

Paola Veronese¹, Francesco Bertelli², Claudia Cattapan², Matteo Andolfatto¹, Maria T. Gervasi¹, Vladimiro L. Vida¹

¹ Maternal-Fetal Medicine Unit, Department of Women's and Children's Health, Azienda Ospedaliera di Padova, Padua, Italy

² Paediatric and Congenital Cardiac Surgery Unit, Department of Cardiac, Thoracic, Vascular Sciences and Public Health, University of Padua, Padua, Italy

Three-dimensional (3D) printed heart models are innovative and interesting tools for improving the diagnosis of patients with cardiovascular diseases,¹ and their use has already been validated in planning the surgical treatment of complex congenital heart defects. However, in almost all cases, reconstruction and 3D printing were performed based on the anatomy of the already born children.² Thus, we sought to explore the possibility of reconstructing and printing a 3D model of the fetal heart affected by complete atrioventricular septal defect (cAVSD), based on prenatal ultrasound images.

The diagnosis of cAVSD was established in our Maternal-Fetal Medicine Unit at 24 weeks of gestational age, in the fetus of a 35-year-old Caucasian woman (FIGURE 1A). Due to the high risk of genetic and chromosomal abnormalities, amniocentesis was proposed, but the mother refused to undergo the examination. The 4D volume of the fetal heart was obtained from the apical 4-chamber view, using spatiotemporal image correlation technology³ and a curved array transducer (4–8 MHz). Transverse sweeps through the fetal chest at 27 weeks of gestational age were performed using the Voluson E8 echographer (General Electrics Healthcare, Chicago, Illinois, United States). Spatiotemporal image correlation provides a temporal resolution roughly equal to the B-mode frame rate (approximately 80 frames per second). However, due to the small size of the fetal heart, the B-mode frame rate during the acquisition of the volume scan was increased to 150 frames per second.²

A virtual 3D object was then generated and a stereolithography file was created using

the Mimics InPrint software (Materialise, Leuven, Belgium) (FIGURE 1B). The stereolithography files derived from the examined patient were finally 3D printed with clear resin, both in the original version (FIGURE 1C) and in the 5-fold magnification (FIGURE 1D) (Form2™ 3D printer, Formlabs, Somerville, Massachusetts, United States). In each model, 3D reconstruction (stereolithography file) took 3 hours, and post processing (preparation of the model to be printed) lasted an hour. Three-dimensional printing (including both models) eventually took about 9 hours (the process is fully autonomous and usually performed overnight). As the Form2™ 3D printer is available in our facility, the cost of each 3D printed heart (just considering the cost of the resin and 3D printer maintenance) ranges between approximately EUR 50 and EUR 75 (in the case of a 5-fold magnification).

To the best of our knowledge,^{4,5} this is the first 3D printed heart model of the fetus with cAVSD. Our 3D model proved to be very helpful in showing the basic anatomical features of fetal complex congenital heart diseases (CHDs). It represents another interesting diagnostic tool in the current standard imaging armamentarium, which improves the accuracy of prenatal diagnostic workup and potentially increases the CHD detection rate. In addition, the possibility of printing 3D models of complex CHD can also improve the quality of prenatal parental counseling, particularly in the case of cAVSD (showing the common atrioventricular valve, the inlet ventricular septal defect, and the complete absence, in this case, of the atrial septum).

Correspondence to:

Vladimiro L. Vida, MD, PhD,
Paediatric and Congenital Cardiac
Surgery Unit, Department of
Cardiac, Thoracic, Vascular
Sciences and Public Health,
University of Padua, Via
Giustiniani 2, 35128 Padua,
Italy, phone: +39 049 8212427,
email: vladimiro.vida@unipd.it
Received: April 10, 2020.

Revision accepted: June 3, 2020.

Published online: June 10, 2020.

Kardiol Pol. 2020; 78 (9): 930-931
doi:10.33963/KP.15429

Copyright by the Author(s), 2020

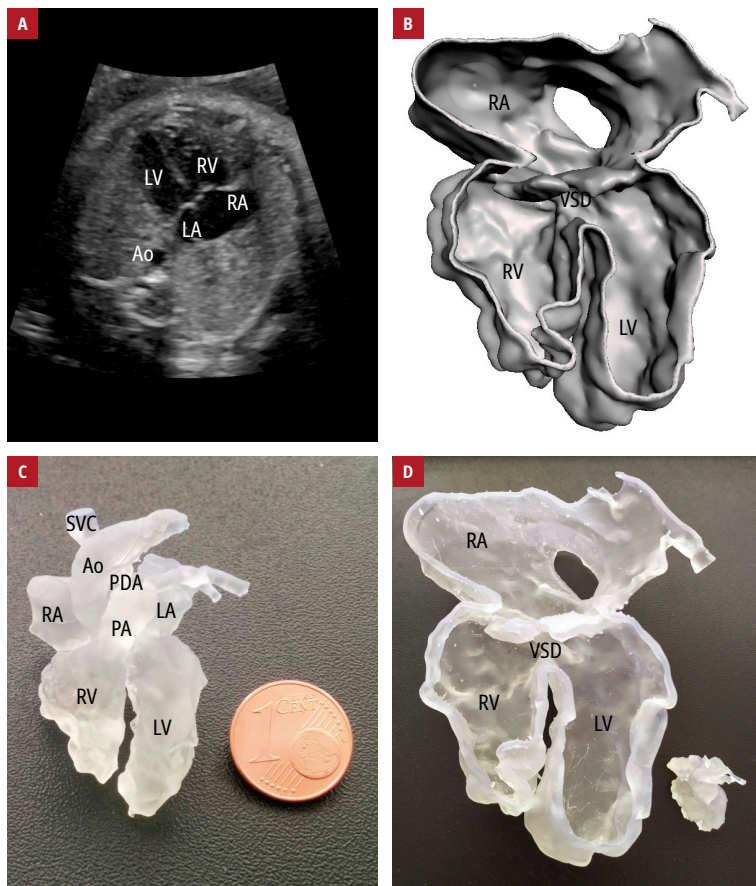


FIGURE 1 Prenatal imaging and heart models of a male fetus at 27 weeks of gestational age, diagnosed with complete atrioventricular septal defect: **A** – 2D cardiac ultrasound in a 4-chamber view; **B** – stereolithography reconstruction obtained from the 4D volume of the heart using spatiotemporal image correlation; **C** – a 3D printed model of the fetal heart in original size, with clear resin (the 1-cent Euro coin is to show the scale); **D** – a 5-fold magnified 3D printed model of the heart

Abbreviations: Ao, aorta; LA, left atrium; LV, left ventricle; PA, pulmonary artery; PDA, patent ductus arteriosus; RA, right atrium; RV, right ventricle; SVC, superior vena cava; VSD, ventricular septal defect

Indeed, with these models, it is possible to provide parents with a more realistic and detailed view of the fetal cardiac anatomy and a better understanding of the future therapeutic plan (ie, restoring normal biventricular circulation with complete intracardiac septation and achieving 2 separate and functioning atrioventricular valves). The possibility to use models printed with 5-fold magnification was greatly appreciated by the family and proved to be of great help during prenatal parental counseling. Moreover, these models are also interesting and useful teaching tools for healthcare professionals involved in the prenatal care of the fetus diagnosed with CHD.

ARTICLE INFORMATION

CONFLICT OF INTEREST None declared.

OPEN ACCESS This is an Open Access article distributed under the terms of the Creative Commons Attribution-NonCommercial-NoDerivatives 4.0 International License (CC BY-NC-ND 4.0), allowing third parties to download articles and share them with others, provided the original work is properly cited, not changed in any way, distributed under the same license, and used for

noncommercial purposes only. For commercial use, please contact the journal office at kardiologiapolska@ptkardio.pl.

HOW TO CITE Veronese P, Bertelli F, Cattapan C, et al. Three-dimensional printing of the fetal heart with complete atrioventricular septal defect based on ultrasound data. *Kardiol Pol.* 2020; 78: 930-931. doi:10.33963/KP.15429

REFERENCES

- 1 Costello JP, Olivieri LJ, Krieger A, et al. Utilizing three-dimensional printing technology to assess the feasibility of high-fidelity synthetic ventricular septal defect models for simulation in medical education. *World J Pediatr Congenit Heart Surg.* 2014; 5: 421-426.
- 2 Olejnik P, Nosal M, Havran T, et al. Utilisation of three-dimensional printed heart models for operative planning of complex congenital heart defects. *Kardiol Pol.* 2017; 75: 495-501.
- 3 Greil GF, Wolf I, Kuettner A, et al. Stereolithographic reproduction of complex cardiac morphology based on high spatial resolution imaging. *Clin Res Cardiol.* 2007; 96: 176-185.
- 4 Chen SA, Ong CS, Hibino N, et al. 3D printing of fetal heart using 3D ultrasound imaging data. *Ultrasound Obstet Gynecol.* 2018; 52: 808-809.
- 5 Guo YT, Hou N, Liang JH, et al. Three-dimensional printed multicolor normal and abnormal fetal hearts based on ultrasound imaging data. *Ultrasound Obstet Gynecol.* 2020; 55: 421-422.