

Multiple extremely high-risk endovascular interventions in aortic dissection in an infant with interrupted aortic arch

Piotr Weryński¹, Jacek Kołcz², Wanda Król-Jawień¹, Paweł Skorek¹,
Agnieszka Wójcik¹, Janusz H. Skalski², Andrzej Rudziński¹

¹ Department of Pediatric Cardiology, Polish-American Institute of Pediatrics (PAIP), Jagiellonian University Medical College, Kraków, Poland

² Department of Pediatric Cardiac Surgery, Polish-American Institute of Pediatrics (PAIP), Jagiellonian University Medical College, Kraków, Poland

A male newborn delivered at term, with a body weight of 3350 g and an Apgar score of 10, was admitted to our center due to suspicion of congenital heart defect. On infusion of alprostadil, the infant presented symptoms of tachypnea without cyanosis, pulse was absent on the femoral arteries, and systolic murmur was heard along the left sternal border. Because of unclear diagnosis on echocardiography, computed tomography angiography was performed and revealed interrupted aortic arch type A according to the Celoria–Patton classification with patent ductus arteriosus (PDA). Due to exacerbation of symptoms of heart failure, the 14-day-old infant was qualified for a hybrid cardiac procedure.

The first stage of the procedure involved pulmonary artery banding. Subsequently, a 10/17-mm stent was implanted into the PDA through the main pulmonary artery (MPA) access. However, follow-up angiography showed dissected and mobile endothelium in the descending aorta (AoD) under the implanted stent. Next attempts of stent implantation in the dissection site were unsuccessful and caused partial reposition of the first stent into the MPA. Eventually, the second stent was implanted into the nontargeted section and the procedure was terminated.

After 8 days, the second intervention was performed. An attempt to implant a 8/18-mm stent through the previously inserted stent into the PDA was unsuccessful and it was placed above the previous one in the AoD. Finally, a 8/15-mm stent was implanted into

the dissection site, overlapping the previous stent in the PDA. Follow-up angiography showed a satisfying procedure outcome, with a vestigial leak in the dissected area.

Despite interventions, the patient's general condition was still severe. A month later, due to large dissection in the AoD, the patient was qualified for high-risk cardiac catheterization (FIGURE 1A–1C; Supplementary material, *Video S1*) via the right femoral vein and the right femoral artery, with formation of an artery–vein loop. The catheter was guided from the right femoral vein through the inferior vena cava, right ventricle, and the PDA to the AoD. The first 9/38-mm stent graft was implanted in the lowest part of the dissection. Then, step by step, other 8–9/25–35-mm stent grafts were positioned with overlay (FIGURE 1D; Supplementary material, *Video S2*). During the procedure, 6 stent grafts and 1 stent were implanted in the PDA with good outcome.

Due to another leak near the diaphragm, the patient was qualified for a hybrid cardiac intervention through the MPA access (Supplementary material, *Video S3*). First, a stent graft was implanted in the area below and above the diaphragm, but bleeding was still observed. The operator implanted the next stent graft in the middle part of the old stent grafts and managed to perform 2 redilatations of them. During follow-up angiography, a subsequent leakage in the thoracic part of the AoD was observed and implantation of a covered stent was needed (FIGURE 1E and 1F). Two months later, next catheterization was performed due to increasing

Correspondence to:

Piotr Weryński, MD, PhD,
Department of Pediatric
Cardiology, Polish-American
Institute of Pediatrics (PAIP),
Jagiellonian University
Medical College,
ul. Wielicka 265, 30-663 Kraków,
Poland; phone: +48 12 658 13 90,
email: piotr.werynski@uj.edu.pl
Received: January 29, 2020.

Revision accepted:

March 13, 2020.

Published online: March 17, 2020.

Kardiol Pol. 2020; 78 (5): 472–473
doi:10.33963/KP.15238

Copyright by the Author(s), 2020

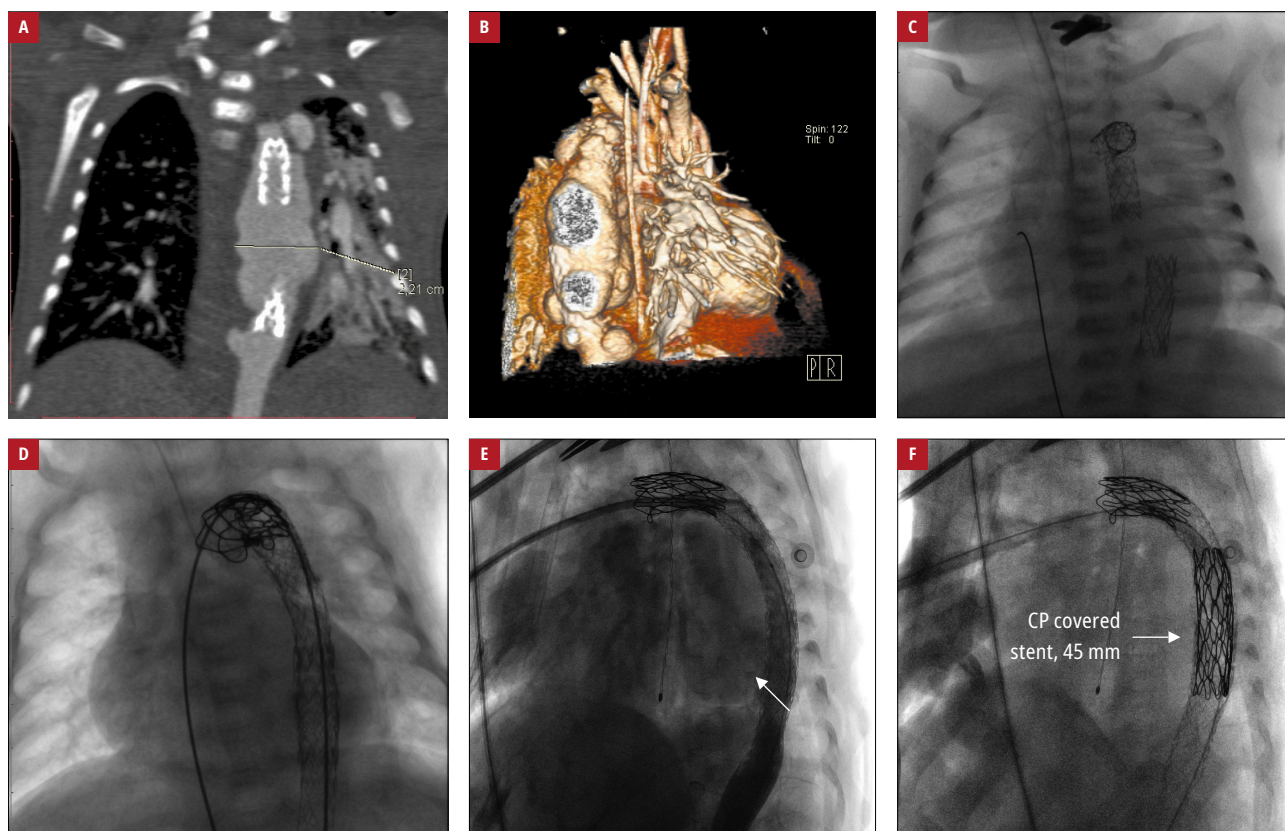


FIGURE 1 An infant with interrupted aortic arch type A and patent ductus arteriosus: **A, B** – computed tomography angiography conducted before the third catheterization, showing a large area of aortic dissection; **C, D** – angiography before (**C**) and after (**D**) the third very high-risk interventional procedure. Angiography during the last procedure: **E** – area of leakage (arrow), **F** – a covered stent implanted in the leakage area (arrow)
Abbreviations: CP, Cheatham Platinum

leakages. Unfortunately, 2 months after the last procedure, another redissection occurred and the patient died.

Aortic dissection is a rare yet life-threatening condition in the pediatric population. Congenital cardiovascular anomalies are one of the major risk factors.¹⁻³ Treatment, particularly in newborns, always carries a great risk of complications.^{4,5} Connective tissue disorders and genetic factors are also known to predispose to aortic dissection. To the best of our knowledge, similar descriptions of such demanding interventions have not appeared in the literature so far.

SUPPLEMENTARY MATERIAL

Supplementary material is available at www.mp.pl/kardiologiapolska.

ARTICLE INFORMATION

CONFLICT OF INTEREST None declared.

OPEN ACCESS This is an Open Access article distributed under the terms of the Creative Commons Attribution-Non Commercial-No Derivatives 4.0 International License (CC BY-NC-ND 4.0), allowing third parties to download articles and share them with others, provided the original work is properly cited, not changed in any way, distributed under the same license, and used for non-commercial purposes only. For commercial use, please contact the journal office at kardiologiapolska@ptkardio.pl.

HOW TO CITE Weryński P, Kotcz J, Król-Jawień W, et al. Multiple extremely high-risk endovascular interventions in aortic dissection in an infant with interrupted aortic arch. *Kardiol Pol.* 2020; 78: 472-473. doi:10.33963/KP.15238

REFERENCES

- 1 Zalstein E, Hamilton R, Zucker N, et al. Aortic dissection in children and young adults: diagnosis, patients at risk, and outcomes. *Cardiol Young.* 2003; 13: 341-344.
- 2 Fikar CR. Acute aortic dissection in children and adolescents: diagnostic and after-event follow-up obligation to the patient and family. *Clin Cardiol.* 2006; 29: 383-386.
- 3 Fikar CR, Koch S. Etiologic factors of acute aortic dissection in children and young adults. *Clin Pediatr (Phila).* 2000; 39: 71-80.
- 4 Tretter JT, Jones TK, McElhinney DB. Aortic wall injury related to endovascular therapy for aortic coarctation. *Circ Cardiovasc Interv.* 2015; 8: e002840.
- 5 Stankowski T, Aboul-Hassan SS, Fitzsche D, et al. Surgical closure of patent ductus arteriosus in extremely low birth weight infants weighing less than 750 grams. *Kardiol Pol.* 2018; 76: 750-754.