

Value of 384-row detector computed tomography imaging of a giant left atrial myxoma coexisting with a prominent flap valve of the foramen ovale

Michał Świerczewski¹, Kamil Zieliński¹, Łukasz Kalińczuk², Ilona Michałowska², Marcin Demkow²

¹ Medical University of Warsaw, Warsaw, Poland

² Department of Coronary and Structural Heart Diseases, Institute of Cardiology, Warsaw, Poland

A 66-year-old woman with unremarkable medical history was admitted due to orthopnea, light-headedness, and dyspnea. Dual-energy 384-row detector computed tomography (CT; SOMATOM® Force, Siemens Healthineers, Erlangen, Germany) confirmed initial transthoracic echocardiography findings (Supplementary material, *Figure S1*) of a large low-attenuation mass (size, 67 × 40 × 30 mm; volume, 42 ml) with a polypoid surface, occupying the left atrium and attached to the interatrial septum, with a wide peduncle, typical of a myxoma (*FIGURE 1A*). The CT revealed also a prominent flap valve of 2.1 mm in length, extending from the unfused septum primum (*FIGURE 1B* and *1C*). Moreover, a left-to-right shunt (grade 2 according to Saremi et al¹) located at the site of the adherence zone between the septum primum and the superior rim of the septum secundum indicated the presence of the patent foramen ovale (PFO), although without an apparent opening of its tunnel into the right atrium. The prominent flap valve together with the septum secundum formed a cone-shaped pocket structure (*FIGURE 1C–1E*). Also, there was a substantial shift of the atrial septum towards the right atrium, documenting volume overload with increased left atrial pressure, which might have triggered the shunt through the small (not visible on CT due to low resolution) opening of the PFO into the right atrium. Considering that the left-to-right shunts are more common when the flap valve is short,¹ with long PFO tunnels being more resistant to the occurrence of interatrial shunt, the “driving force” had to be exceptionally high in order to produce a relatively large shunt through the small PFO opening, as documented in our patient. Under normal

conditions, the blood flow from the right pulmonary veins is brisk and is immediately adjacent to the interatrial septum, but in the presence of functional myxoma-induced mitral stenosis, it is likely to be sluggish, and stasis may occur in the septal cone-shaped pocket structure with subsequent thrombosis. The myxoma itself is a well-known origin of distal embolism. It can be speculated that the risk of thromboembolic events might have been considerably increased because of the intra-atrial cone-shaped pocket structure together with the disturbed blood flow, which has clinical significance similar to that of a left atrial septal pouch (*FIGURE 1F*).^{2,3} The 384-row detector CT was used primarily to evaluate the coronary arteries and to exclude fistulas or coronary steal phenomenon, which were reported to coexist with a myxoma and could affect the approach to surgery. Apart from a detailed assessment of the interatrial septum anatomy, 384-row detector CT allowed a noninvasive visualization of the left-to-right shunt as well as differentiation between a myxoma and thrombus. Eventually, the tumor was excised, and the patient made an uneventful postoperative recovery.

SUPPLEMENTARY MATERIAL

Supplementary material is available at www.mp.pl/kardiologiapolska.

ARTICLE INFORMATION

CONFLICT OF INTEREST None declared.

OPEN ACCESS This is an Open Access article distributed under the terms of the Creative Commons Attribution-NonCommercial-NoDerivatives 4.0 International License (CC BY-NC-ND 4.0), allowing third parties to download articles and share them with others, provided the original work is properly cited, not changed in any way, distributed under the same license, and used for non-commercial purposes only. For commercial use, please contact the journal office at kardiologiapolska@ptkardio.pl.

Correspondence to:

Michał Świerczewski, Department of Coronary and Structural Heart Diseases, Institute of Cardiology, ul. Alpejska 42, 04-628 Warszawa, Poland, phone: +48 505 794 691, email: swierczewski.michal@yahoo.pl
Received: October 15, 2019.

Revision accepted:

November 2, 2019.

Published online:

November 4, 2019.

Kardiol Pol. 2020; 78 (1): 80-81
doi:10.33963/KP.15045

Copyright by the Author(s), 2020

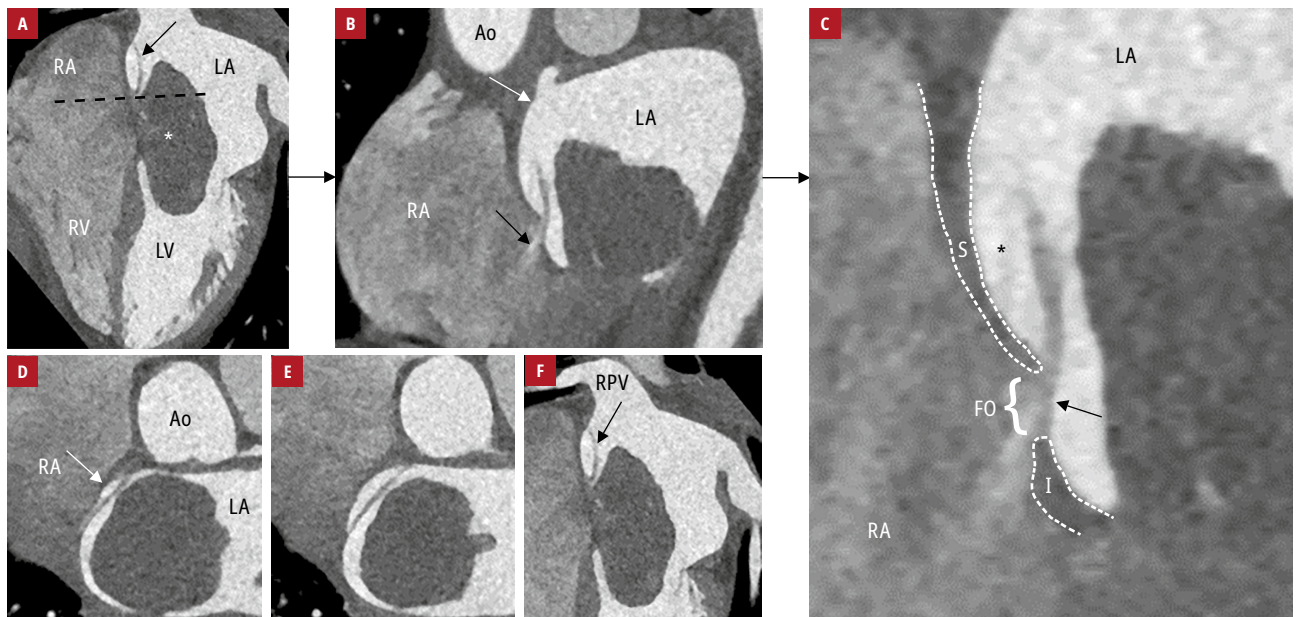


FIGURE 1 Computed tomography scans: **A** – a 4-chamber view demonstrating myxoma (asterisk) and flap valve (black arrow); **B** – a short-axis image obtained at the level of the foramen ovale (dashed line in panel **A**) demonstrating a shunt (black arrow) and diverticulum (white arrow); **C** – a magnified image showing the septum secundum (dashed line) and septum primum (arrow) fused to the inferior rim (I) of the fossa ovalis (FO), extending superiorly as a flap and forming a cone-shaped pocket (asterisk). A short-axis image perpendicular to the cone-shaped pocket shows its fundus (**D**) and superior margin (**E**). **F** – disturbed blood flow from the right pulmonary vein along the interatrial septum.

Abbreviations: Ao, aorta; LA, left atrium, LV, left ventricle; RA, right atrium; RPV, right pulmonary vein; RV, right ventricle; S, superior rim of the fossa ovalis

HOW TO CITE Świerczewski M, Zieliński K, Kalińczuk Ł, et al. Value of 384-row detector computed tomography imaging of a giant left atrial myxoma coexisting with a prominent flap valve of the foramen ovale. *Kardiol Pol.* 2020; 78: 80-81. doi:10.33963/KP.15045

REFERENCES

- 1 Saremi F, Channal S, Raney A, et al. Imaging of patent foramen ovale with 64-section multidetector CT. *Radiology.* 2008; 249: 483-492.
- 2 Gurudevan SV, Shah H, Tolstrup K, et al. Septal thrombus in the left atrium: is the left atrial septal pouch the culprit? *JACC Cardiovasc Imaging.* 2010; 3: 1284-1286.
- 3 Kucybała I, Ciuk K, Klimek-Piotrowska W. Clinical anatomy of human heart atria and interatrial septum – anatomical basis for interventional cardiologists and electrocardiologists. Part 1: right atrium and interatrial septum. *Kardiol Pol.* 2018; 76: 499-509.