

Zero-fluoroscopy approach to mapping and catheter ablation of atypical accessory pathways located at the right/left coronary cusp commissure

Sebastian Stec¹, Bartosz Ludwik², Janusz Śledź¹, Ewa Zaremba-Flis³, Sebastian Szmit⁴

1 ELMedica EP-Network, Skarżysko-Kamienna, Poland

2 Department of Cardiology, Regional Specialist Hospital, Centre for Research and Development, Wrocław, Poland

3 Cardiology Department, Voivodship Hospital of Pope John Paul II, Zamość, Poland

4 Department of Pulmonary Circulation, Thromboembolic Diseases and Cardiology, Centre of Postgraduate Medical Education, European Health Centre, Otwock, Poland

Accessory pathways (APs) are usually anomalous muscular atrioventricular connections outside the atrioventricular node. The diagnosis and treatment of atypical AP locations with intermittent preexcitation may be challenging,¹ especially when antidromic atrioventricular reentrant tachycardia (AAVRT) mimics ventricular tachycardia (VT).

We present a case of a 26-year-old white man with a 2-year history of undocumented regular palpitations lasting 1 to 10 minutes. Resting ambulatory 12-lead electrocardiography, cardiopulmonary exercise stress test, and echocardiography were normal. During 24-hour Holter monitoring, intermittent preexcitation was documented only during the night and sleep.

The patient was scheduled for elective electrophysiological study (EPS) and radiofrequency catheter ablation with zero-fluoroscopy approach (FIGURE 1A). The EPS confirmed retrograde decremental conduction. During proximal coronary sinus pacing, prolonged decremental conduction was observed with QRS-complex widening and delta waves in all leads (FIGURE 1B). The effective refractory period of the APs was about 350 ms. Both preexcitation and induced wide QRS tachycardia with maximum preexcitation were atypical of known major locations of atrioventricular APs (FIGURE 1C).

Using computer-based algorithms for the differential diagnosis for the right and left ventricular outflow tract VT,² the site of origin in the left aortic cusps was predicted and mapped via a retrograde approach. Mapping of the right/left coronary cusp (RCC-LCC) commissure revealed fragmented potentials preceded by 40 ms of the preexcited

QRS complex and their disappearance during the narrow QRS complex (FIGURE 1D). The first application (60°C/50W) was successful within the first 10 seconds. Bonus applications were performed in the RCC-LCC commissure without complications. During postablation EPS, preexcitation and AAVRT were no longer observed and were not induced by adenosine and isoproterenol challenge. The procedure lasted 45 minutes without fluoroscopy use. The patient remained asymptomatic for the next 4 months, with no signs of preexcitation on Holter monitoring and adenosine stress test.

Our case illustrates several challenges associated with an atypical AP location and a differential diagnosis of wide QRS complex and left ventricular outflow tract tachycardia in a patient with no overt preexcitation. Although ablation of preexcitation from the coronary cusps has already been reported,³ this is the first report on a successful ablation of preexcitation from the presumed region of the RCC-LCC commissure. Manifest preexcitation was recorded only during parasympathetic activity (associated with atrioventricular nodal Wenckebach periodicity) or in a short coupling interval of supraventricular ectopy or paced rhythm. Wide QRS complex tachycardia associated with the AP location in the RCC-LCC commissure could not be easily differentiated from idiopathic VT with retrograde conduction due to similar QRS morphology. However, electrocardiographic algorithms and simplified zero-fluoroscopy mapping may facilitate safe and fast ablation, as in typical VT.²

Correspondence to:

Bartosz Ludwik, MD, PhD,
Department of Cardiology,
Regional Specialist
Hospital, Centre for
Research and Development,
ul. Kamińskiego 73a,
51-126 Wrocław, Poland,
phone: +48 71 327 02 58,
email: bludwik@gmail.com
Received: October 7, 2019.

Revision accepted:

November 7, 2019.

Published online:

November 7, 2019.

Kardiologia Pol. 2019; 77 (12): 1200-1201
doi:10.33963/KP.15054

Copyright by the Author(s), 2019

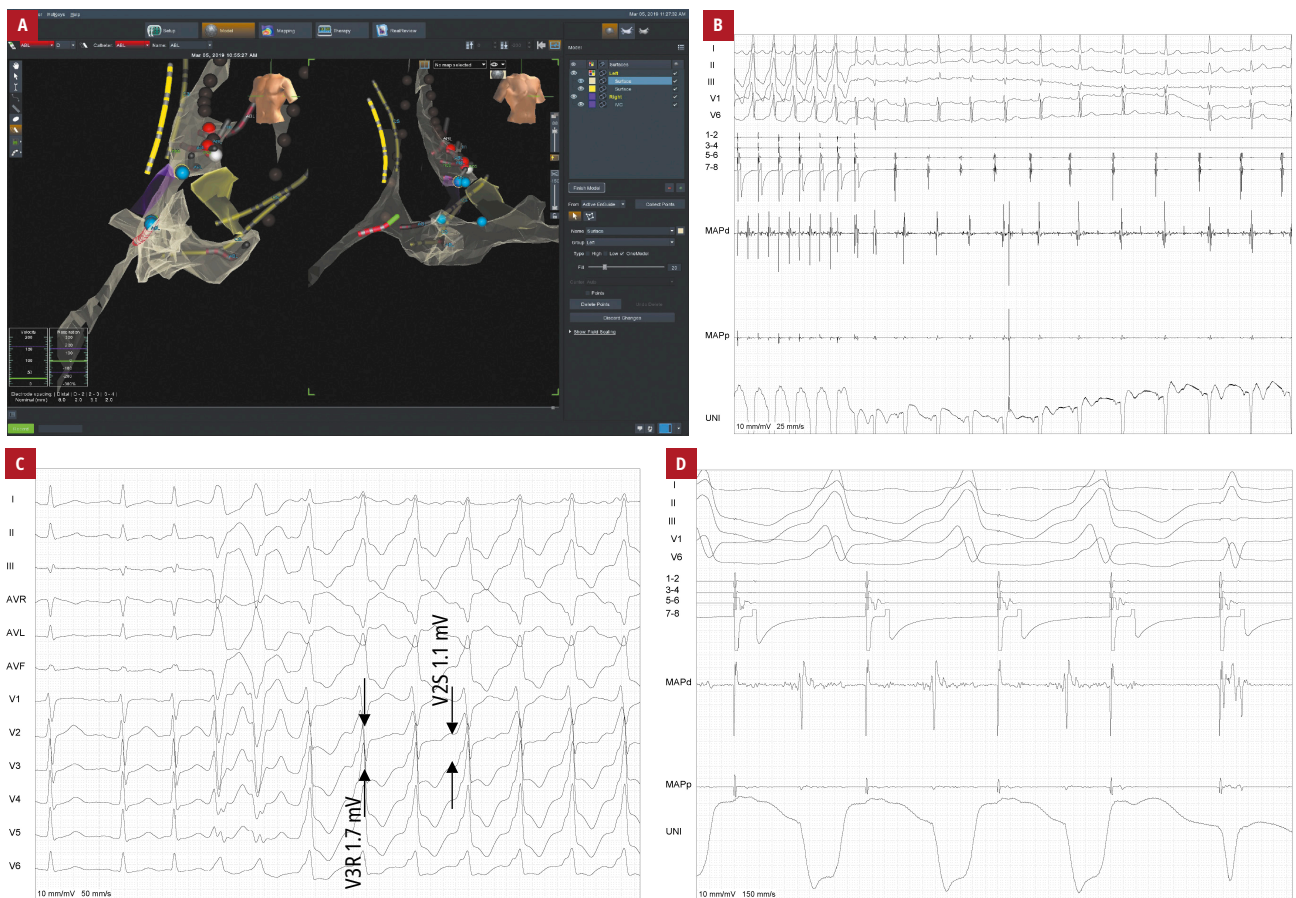


FIGURE 1 **A** – 3-dimensional model of the right atrium and aortic root (Esite Velocity, Abbot, United States); **B** – incremental atrial pacing and refraction of the accessory pathway; **C** – induction of antidromic atrioventricular reentrant tachycardia, with the results of TZ index and V2S/V3R algorithm calculations suggesting the origin of arrhythmia in the left ventricular outflow tract ($V2S/V3R = 1.1\text{ mV} / 1.7\text{ mV} = 0.65$; TZ index = -0.5); **D** – fragmented potentials (K) from the tip of the ablation catheter recorded from the right / left coronary cusp commissure just before a successful application

ARTICLE INFORMATION

CONFLICT OF INTEREST None declared.

OPEN ACCESS This is an Open Access article distributed under the terms of the Creative Commons Attribution-NonCommercial-NoDerivatives 4.0 International License (CC BY-NC-ND 4.0), allowing third parties to download articles and share them with others, provided the original work is properly cited, not changed in any way, distributed under the same license, and used for non-commercial purposes only. For commercial use, please contact the journal office at kardiologiapolska@ptkardio.pl.

HOW TO CITE Stec S, Ludwik B, Śledź J, et al. Zero-fluoroscopy approach to mapping and catheter ablation of atypical accessory pathways located at the right / left coronary cusp commissure. *Kardiol Pol.* 2019; 77: 1200-1201. doi:10.33963/KP.15054

REFERENCES

- Page RL, Joglar JA, Caldwell MA, et al; Evidence Review Committee Chair. 2015 ACC/AHA/HRS guideline for the management of adult patients with supraventricular tachycardia: executive summary: a report of the American College of Cardiology/American Heart Association Task Force on Clinical Practice Guidelines and the Heart Rhythm Society. *Circulation.* 2016; 133: e471-e505.
- Ludwik B, Deutsch K, Mazij M, et al. Electrocardiographic algorithms to guide the management strategy of idiopathic outflow tract ventricular arrhythmias. *Pol Arch Intern Med.* 2017; 127: 749-757.
- Karbarz D, Stec PJ, Deutsch K, et al. Zero-fluoroscopy catheter ablation of symptomatic pre-excitation from non-coronary cusp during pregnancy. *Kardiol Pol.* 2017; 75: 1351.