

Presence and characteristics of coronary artery fistulas among patients undergoing coronary angiography

Jakub Podolec^{1*}, Łukasz Wiewiórka^{1*}, Zbigniew Siudak², Krzysztof Malinowski³,
Krzysztof Bartuś⁴, Dariusz Dudek⁵, Krzysztof Żmudka¹, Jacek Legutko¹

1 Department of Interventional Cardiology, Institute of Cardiology, Jagiellonian University Medical College, John Paul II Hospital, Kraków, Poland

2 Faculty of Medicine and Health Sciences, Jan Kochanowski University in Kielce, Kielce, Poland

3 Faculty of Health Sciences, Jagiellonian University Medical College, Kraków, Poland

4 Department of Cardiovascular Surgery and Transplantology, Institute of Cardiology, Jagiellonian University Medical College, John Paul II Hospital, Kraków, Poland

5 Department of Clinical Cardiology and Cardiovascular Interventions, University Hospital, Kraków, Poland

KEY WORDS

angiography, coronary artery fistula, Classification of Rare Cardiovascular Diseases and Disorders, Ogólnopolski Rejestr Procedur Kardiologii Interwencyjnej

EDITORIALS

by Said, see p. 1007;
by Romano and Petroni, see p. 1009

Correspondence to:

Jakub Podolec, MD, PhD,
Department of Interventional
Cardiology, Institute of Cardiology,
Jagiellonian University Medical
College, John Paul II Hospital,
ul. Prądnicka 80, 31-202 Kraków,
Poland, phone: +48 12 614 35 01,
email: jipodolec@gmail.com
Received: May 2, 2019.

Revision accepted:

September 5, 2019.

Published online:

September 5, 2019.

Kardiologia Pol. 2019; 77 (11): 1034-1039
doi:10.33963/KP.14963

Copyright by the Author(s), 2019

*JP and ŁW contributed equally to this work.

ABSTRACT

BACKGROUND Coronary artery fistula is defined as a connection between one or more coronary artery and a heart chamber.

AIMS The aim of the study was to determine the overall incidence of coronary artery fistulas in Polish patients undergoing diagnostic coronary artery angiography as well as the frequency of particular origin and draining sites.

METHODS The data were obtained from the Polish National Registry of Invasive Cardiology Procedures among patients hospitalized between January 1, 2014 and December 31, 2016 in invasive cardiology departments in Poland.

RESULTS The study included 298 558 patients. A coronary artery fistula was present in 261 patients (0.087%). There were 131 women (50.19%) and 130 men (49.81%). The most frequent origin of a coronary artery fistula was the left anterior descending artery (167 cases, 59.22%). The pulmonary artery was the most frequent drainage site for fistulas originating from the left anterior descending artery and the right coronary artery (84 cases, 50.30% and 25 cases, 31.65%, respectively). Fistulas originating from the circumflex artery most frequently drained into another artery (10 cases, 27.78%).

CONCLUSIONS The left anterior descending coronary artery was the origin site for more than half of all detected coronary artery fistulas. The pulmonary artery was the most frequent origin and drainage site for coronary artery fistulas.

INTRODUCTION Coronary artery fistulas are defined as abnormal connections between one or more coronary artery and a heart chamber (coronary cameral fistula) or with the great thoracic vessel (coronary artery or arteriovenous fistula) bypassing the capillary bed.¹ The vast majority of these are congenital but can also appear after trauma, infection, or iatrogenic injury following intracardiac congenital heart operations or cardiac biopsy following heart transplantation.¹⁻³ Available sources also report the presence of a coronary artery fistula as a complication

of percutaneous coronary intervention of a totally occluded coronary vessel⁴ or Kawasaki disease.⁵ The incidence in the general population stands at 0.002% but is higher among patients who have undergone coronary angiography and varies from 0.05% to 0.25%.⁶⁻⁸ Interestingly, the incidence of coronary artery fistulas detected with coronary computed tomography angiography is even higher and amounts to 0.9%.⁷

Management of coronary artery fistulas is a challenging task, especially in asymptomatic patients. Some sources recommend to close

WHAT'S NEW?

The aim of the study was to evaluate the prevalence of coronary artery fistulas in Polish patients who were diagnosed using coronary angiography. The study included 298 558 patients and the presence of a coronary artery fistula was noted in 261 patients (0.087%). This is the largest Polish registry of coronary artery fistulas. Our study showed that the left anterior descending artery is the most frequent origin of coronary artery fistulas in contrast to the previously published results. The study also indicated that pulmonary artery was the most frequent drainage site for fistulas; however, prior angiographic evaluations revealed the right atrium and the right ventricle to be more common drainage sites.

the fistula in asymptomatic patients to prevent long-term complications.^{3,8,9} Onset of typical symptoms such as dyspnea or chest pain, large left to right overload, myocardial ischemia, left ventricular systolic dysfunction or its overload, and as a consequence, progression of congestive heart failure, are primary indications for closure of a fistula.^{1,6} Detailed recommendations for the management of coronary artery fistulas are provided by the 2008 American College of Cardiology / American Heart Association Guidelines for the Management of Adults With Congenital Heart Disease.¹⁰ According to the recommendations, large coronary artery fistulas should be closed using transcatheter or surgical methods after estimation of its course. Closing small or moderate coronary artery fistulas should be reserved for cases where myocardial ischemia, unexplained systolic or diastolic impairment, or arrhythmia have been documented (recommendations class I, level of evidence C).¹⁰

According to the Clinical Classification of Rare Cardiovascular Diseases and Disorders released in 2018, coronary artery fistulas are assigned to Class IV, Group I (rare congenital cardiovascular diseases, abnormalities of the position, and connection of the heart and vessels).¹¹

In our study, we present the results obtained from the Polish National Registry of Invasive Cardiology Procedures (Polish, Ogólnopolski Rejestr Procedur Kardiologii Inwazyjnej). This is a national registry of all percutaneous procedures in interventional cardiology in Poland, operated by the Jagiellonian University Medical College. The presence of coronary artery fistulas is noted during diagnostic coronary artery angiography. Records from the registry were presented in previous studies.¹²

The aim of our study was to determine the overall incidence of coronary artery fistulas among Polish patients undergoing diagnostic coronary artery angiography, frequency of particular origin and draining sites, and determination of potential predisposing factors.

METHODS The study group included 298 558 patients admitted to Polish hospitals who had undergone coronary artery angiography

between January 1, 2014 and December 31, 2016. The presence of a coronary artery fistula was assessed during diagnostic coronary angiography. Three main coronary arteries were considered as the origin of coronary artery fistulas: the left anterior descending artery, the circumflex artery, and the right coronary artery. Possible drainage sites were the left ventricle, right ventricle, right atrium, pulmonary artery, or another artery. Invasive diagnostic workup was performed due to different indications such as stable coronary artery disease, acute coronary syndromes (unstable angina, non-ST-segment elevation myocardial infarction, ST-segment elevation myocardial infarction), cardiac arrest, congenital heart defects, and other indications. Additionally, the frequency of the following risk factors of atherosclerosis was assessed: diabetes, smoking status, hypertension, other comorbidities including previous stroke, myocardial infarction, percutaneous coronary intervention, coronary artery bypass graft, and coexisting kidney disease, or chronic obstructive pulmonary disease.

Statistical analysis Descriptive analysis was performed. Nominal variables were presented as numbers and percentages, and compared using the likelihood ratio test, while continuous variables were presented as means and standard deviations and compared using the *t* test. *P* values of less than 0.05 were assumed to indicate significance; however, clinical significance of obtained results should be interpreted with respect to expert knowledge of the particular parameter. The analyses were conducted in the JMP software, version 14.0.0 (SAS Institute Inc., Cary, North Carolina, United States, 2018).

RESULTS The presence of a coronary artery fistula was noted in 261 patients (0.087%) in our study group. The mean (SD) age of patients with a coronary artery fistula was 65.27 (10.99) years, ranging from 19 to 88 years. Mean (SD) weight was 76.57 (15.77) kg, ranging from 30 to 145 kg. Among patients without a coronary artery fistula, mean (SD) age was 66.59 (10.86) years, ranging from 15 to 105 years. Mean (SD) weight was 80.64 (16.42) kg. The study population consisted of 182 873 men (61.25%) and 112 212 women (37.58%). Gender was not recorded in 3473 patients (1.16%). The exact number of patients with multiple fistulas was not determined.

There was no difference in mean (SD) age between groups with and without a coronary artery fistula (65.27 [10.00] years vs 66.59 [10.86] years; *P* = 0.05). There were 131 women (50.19%) and 130 men (49.81%) with a coronary artery fistula. In the context of the whole study group, the presence of coronary artery fistulas was more frequent among women (0.12%) than men (0.07%;

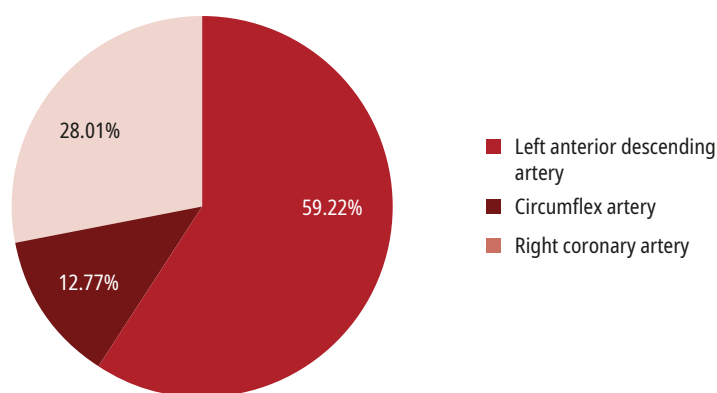


FIGURE 1 Percentage values of coronary artery fistula origin

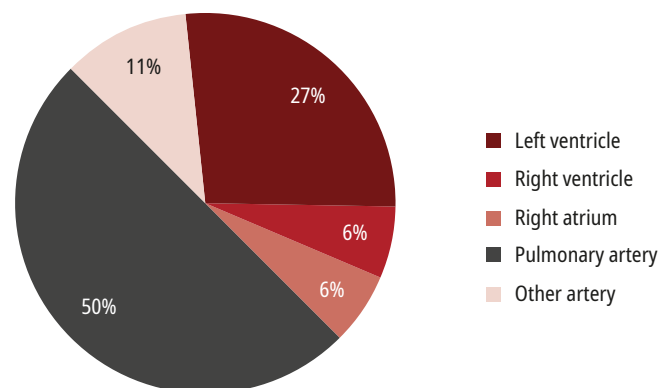


FIGURE 2 Percentage values of drainage sites for fistulas originating from the left anterior descending coronary artery

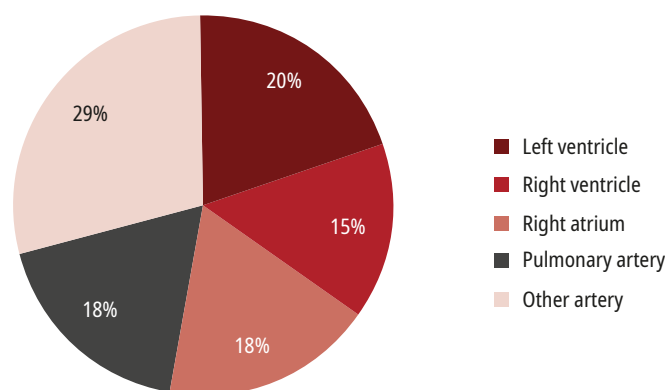


FIGURE 3 Percentage values of drainage sites for fistulas originating from the circumflex coronary artery

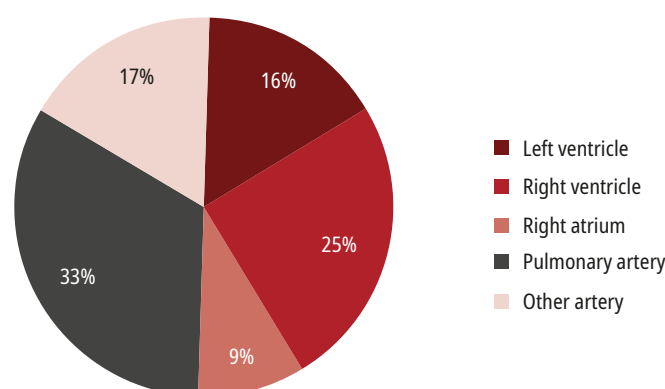


FIGURE 4 Percentage values of drainage sites for fistulas originating from the right coronary artery

$P < 0.001$). Moreover, patients with coronary artery fistulas weighed less than other patients (76.57 [15.77] kg vs 80.64 [16.42] kg, respectively; $P < 0.001$).

The most frequent origin of a coronary artery fistula was the left anterior descending artery (167 cases; 59.22%). The right coronary artery was affected in 79 cases (28.01%) and circumflex artery in 36 cases (12.77%). Percentage values for individual fistula origin sites are shown in [FIGURE 1](#).

The pulmonary artery was the most frequent drainage site for fistulas originating from the left anterior descending and right coronary artery (84 cases, 50.30% and 25 cases, 31.65%, respectively). Fistulas originating from the circumflex artery most frequently drained into another artery (27.78%). Percentage values of drainage sites for analyzed coronary artery fistulas significance are presented in [FIGURES 2–4](#).

Acute coronary syndrome occurred in 171 112 patients (57.31%). The presence of a coronary artery fistula was described in 97 of those patients (0.06%) and was less frequent than in the group of patients diagnosed due to other indications (164; 0.13%; $P < 0.001$). In the group with unstable angina, fistulas were noted in 63 cases (0.06%; $P = 0.002$). In patients with acute myocardial infarction, fistulas were present in 24 cases (0.06%; $P = 0.05$) diagnosed due to non-ST-segment elevation myocardial infarction and 10 cases (0.03%) treated due to ST-segment elevation myocardial infarction ($P < 0.001$). In the entire study group and in the context of all indications to perform coronary angiography, fistulas were the most common finding among patients diagnosed due to indications classified as other and comprised 0.17% of the cases. Exact details of fistula presence and its incidence are shown in [TABLE 1](#).

Interestingly, taking into account comorbidities, only chronic obstructive pulmonary disease was associated with coronary artery fistulas more frequently than other groups. Coronary artery fistulas were present in 18 cases (0.23% of patients with chronic obstructive pulmonary disease) and incidence was higher than among the rest of patients (243 patients; 0.08%; $P < 0.001$). Coronary artery fistulas were also diagnosed more frequently among patients suffering from hypertension, kidney disease, and those who smoked cigarettes, but these results did not reach statistical significance. The exact details of investigated comorbidities are shown in [TABLE 2](#).

DISCUSSION Most patients with coronary artery fistulas remain asymptomatic in the first 2 decades of life, but as the size of the fistula increases, symptoms may appear. Clinical presentation and symptoms depend on the size, shunt

TABLE 1 Comparison of indications to perform coronary angiography and incidence of coronary artery fistula

Indication	Stable angina	Unstable angina	NSTEMI	STEMI	Cardiac arrest	Congenital heart defect	Other
Total number of patients	111 241	97 719	38 917	34 476	1734	8546	5924
Coronary artery fistula present	138 (0.12)	63 (0.06)	24 (0.06)	10 (0.03)	2 (0.12)	14 (0.16)	10 (0.17)
Coronary artery fistula absent	111 103 (99.88)	97 656 (99.94)	38 893 (99.94)	34 466 (99.97)	1732 (99.88)	8532 (99.84)	5914 (99.83)

Data are presented as number (percentage).

Abbreviations: NSTEMI, non-ST-segment elevation myocardial infarction; STEMI, ST-segment elevation myocardial infarction

TABLE 2 Occurrence of comorbidities in the presence of coronary artery fistulas

Comorbidity	Present	Absent	Total occurrence	P value
Diabetes	41 (0.06)	220 (0.09)	64 403	0.02
Previous stroke	6 (0.07)	255 (0.09)	8796	0.71
Previous MI	41 (0.06)	220 (0.09)	65 322	0.02
Previous PCI	40 (0.05)	221 (0.10)	76 892	<0.001
Previous CABG	3 (0.02)	258 (0.09)	16 740	<0.001
Smokers	53 (0.11)	208 (0.08)	50 398	0.15
Hypertension	192 (0.09)	69 (0.07)	205 703	0.1
Kidney disease	17 (0.11)	244 (0.09)	14 979	0.29
COPD	18 (0.23)	243 (0.08)	7977	<0.001

Data are presented as number (percentage).

Abbreviations: CABG, coronary artery bypass graft; COPD, chronic obstructive pulmonary disease; MI, myocardial infarction; PCI, percutaneous coronary intervention

direction, and location of the fistula. Typically, patients experience exertional dyspnea, fatigue, angina, or palpitations.^{1,3,13} Angina occurs in the presence of the coronary steal phenomenon, which appears when systemic to pulmonary blood flow lowers the distal diastolic pressure and leads to ischemia of adjacent myocardium, even in the absence of coronary artery disease. In some cases, coronary fistulas may coexist with atherosclerotic changes of an artery and cause ischemia simultaneously.¹³ Other studies showed that fistulas originating from the proximal part of the coronary artery can even increase the likelihood of atherosclerotic coronary artery disease,¹⁴ but in most cases, symptoms are more likely to be associated with the steal phenomenon. Large left-to-right shunts predispose patients to congestive heart failure through volume overload of the heart chambers and pulmonary vascular bed. Other relatively rare complications of fistulas are thrombosis or embolism, which may lead to acute ischemia and cause myocardial infarction.¹ Moreover, progressive enlargement of a fistula may result in aneurysm formation and can put patients at risk of rupture and occurrence of hemopericardium

and cardiac tamponade.^{3,15-17} Coronary artery fistulas also predispose patients to infective endocarditis and some sources suggest that as long as the shunt persists, proper endocarditis prophylaxis should be considered.^{3,13,17}

The most common finding on the physical examination is the presence of a continuous murmur induced by systolic-diastolic flow in large fistulas. Diagnostic investigations include basic tests such as electrocardiogram, which can reveal left ventricular volume overload or ischemic changes, and chest X-ray, which may reveal cardiomegaly in the case of a significant left-to-right shunt; however, these findings are not pathognomonic.^{1,3,17} In some cases, coronary artery fistulas can be visualized on transthoracic echocardiography and Doppler imaging which may disclose the enlargement of the heart chamber or coronary artery, origin site, and drainage site. It is not, however, a suitable tool for functional assessment.^{1,3,8,17} Other noninvasive techniques, such as magnetic resonance imaging and computed tomography, provide excellent anatomical delineation and are useful in confirming the origin site and patency of a fistula. Additionally, a myocardial perfusion scan could be useful in the assessment of myocardial ischemic territory and determining whether invasive treatment should be undertaken among asymptomatic patients.¹⁷ The noninvasive diagnosis is sometimes difficult, especially in symptomatic patients. Therefore, in some cases, fractional flow reserve was used for clinical evaluation of the fistula severity and significance. Data from such cases, especially with long-term follow-up, are limited and further investigation is needed. Coronary angiography remains the principal diagnostic technique for the precise evaluation of hemodynamic significance of the fistula, its origin, course, presence of stenosis or aneurysm, and drainage site.¹⁷ Both coronary arteries should be visualized selectively to confirm diagnosis, exact anatomy, and presence of multiple fistulas.¹

Coronary artery fistulas are a rare finding. The overall incidence of coronary artery fistulas reported in our study is in line with previous

studies.^{6,7,14} Large reports from various study groups and angiographic evaluations demonstrate the presence of coronary artery fistulas of around 0.1%.^{18,19} On the other hand, one of the largest reports that assessed 126 595 angiograms suggested a higher incidence of coronary artery fistulas and puts this number at 0.18% of patients.²⁰ However, the data was collected between the years 1960 and 1988, and since then, diagnostic techniques, imaging quality, and the ability to delineate anatomical structures have significantly improved. The incidence of coronary artery congenital anomalies revealed by angiographic evaluations was also estimated in a central European population, and coronary artery fistula was present on 5 angiograms (0.065%).²¹ Interestingly, a study conducted in Turkey revealed a much higher incidence, on the level of 0.37%.²²

An even higher incidence of coronary artery fistulas was reported via coronary computed tomography angiography studies and reached 0.9%.⁷ This discrepancy may be explained by limitations of coronary angiography such as difficulties in cannulation of arteries with a fistulous origin and in reliable assessment of anatomic relations of complex, anomalous vessels based on 2-dimensional fluoroscopic images.⁷

Previous studies reported the right coronary artery as the most frequent origin site for coronary artery fistulas (52%), with the left anterior descending coronary artery being involved in 30% of cases, and the circumflex artery affected in approximately 18% of cases.¹ Other reports, which provide a wide range of percentages, also describe the right coronary artery as the most frequent origin site.¹⁷ These results are in opposition to our findings, which revealed the left anterior descending coronary artery as the origin site for more than half of all detected coronary artery fistulas (59.22%). The results regarding the drainage sites are also surprising, since prior angiographic evaluations showed the right atrium and right ventricle to be more common drainage sites of coronary artery fistulas (right atrium, 19%–26% and right ventricle, 14%–40%).¹⁷ In our study, the most common drainage site was the pulmonary artery, and some previous reports also support this finding.⁷ Moreover, a study by Verdini et al²³ also suggests the left anterior descending coronary artery and the pulmonary artery as the most frequent origin and drainage sites for coronary artery fistulas, respectively. Some cases describe also the superior vena cava as one of the possible drainage sites.²⁴

Acute coronary syndrome is a rare clinical presentation in patients with coronary artery fistulas. However, it is more likely that thrombi form in coronary artery fistulas due to turbulent blood flow. Thrombi originating from coronary artery fistulas may cause systemic and coronary embolization.²⁵

In our study, we determined that female sex could be a predisposing factor for coronary artery fistulas. This finding is also contradictory to prior evaluations that suggested a higher incidence of coronary artery anomalies among women, but, at the same time, cited differences in occurrence of fistulas that were not connected to sex.^{17,26} The correlation between higher incidence of chronic obstructive pulmonary disease in patients with fistulas and its influence on drainage site need further investigation.

Study limitations The greatest limitation of the current study is its retrospective character. Data was submitted by all interventional centers in Poland with different grade of completeness and was not monitored. All data regarding comorbidities was based on medical records, and no additional laboratory tests or long-term follow-up including type of treatment were performed during data collection. Coronary angiograms were not assessed directly for the conducted study, but written descriptions were analyzed.

Conclusions In our study, we investigated a large population of patients who had undergone coronary angiography and we determined the incidence of coronary artery fistulas to be 0.087%. Additionally, our report sheds light on the most frequent sites of origin and drainage of coronary fistulas and suggests that female sex could be a predisposing factor. With regard to assessed comorbidities, only chronic obstructive pulmonary disease was more frequent in patients with coronary artery fistulas, while other factors require further investigation.

ARTICLE INFORMATION

CONTRIBUTION STATEMENT JP and ŁW contributed equally to the paper and are first authors of the publication.

CONFLICT OF INTEREST None declared.

OPEN ACCESS This is an Open Access article distributed under the terms of the Creative Commons Attribution-NonCommercial-NoDerivatives 4.0 International License (CC BY-NC-ND 4.0), allowing third parties to download articles and share them with others, provided the original work is properly cited, not changed in any way, distributed under the same license, and used for noncommercial purposes only. For commercial use, please contact the journal office at kardiologiapolska@ptkardio.pl.

HOW TO CITE Podolec J, Wiewiórka Ł, Siudak Z, et al. Presence and characteristics of coronary artery fistulas among patients undergoing coronary angiography. *Kardiol Pol.* 2019; 77: 1034-1039. doi:10.33963/KP.14963

REFERENCES

- 1 Qureshi SA. Coronary arterial fistulas. *Orphanet J Rare Dis.* 2006; 1: 51.
- 2 Somers JM, Verney GL. Coronary cameral fistulae following heart transplantation. *Clin Radiol.* 1991; 44: 419-421.
- 3 Mangukia CV. Coronary artery fistula. *Ann Thorac Surg.* 2012; 93: 2084-2092.
- 4 Cheng TO. Coronary artery fistula related to dilatation of totally occluded vessel. *Clin Cardiol.* 1994; 17: 166.
- 5 Koenig PR, Kimball TR, Schwartz DC. Coronary artery fistula complicating the evaluation of Kawasaki disease. *Pediatr Cardiol.* 1993; 14: 179-180.
- 6 Raju MG, Goyal SK, Punnam SR, et al. Coronary artery fistula: a case series with review of the literature. *J Cardiol.* 2009; 53: 467-472.
- 7 Lim JJ, Jung JJ, Lee BY, Lee HG. Prevalence and types of coronary artery fistulas detected with coronary CT angiography. *AJR Am J Roentgenol.* 2014; 203: W237-W243.

- 8 Angelini P. Coronary artery anomalies – current clinical issues: definitions, classification, incidence, clinical relevance, and treatment guidelines. *Tex Heart Inst J*. 2002; 29: 271-278.
- 9 Dodge-Khatami A, Mavroudis C, Backer CL. Congenital Heart Surgery Nomenclature and Database Project: anomalies of the coronary arteries. *Ann Thorac Surg*. 2000; 69 (suppl 4): S270-S297.
- 10 Warnes CA, Williams RG, Bashore TM, et al. ACC/AHA 2008 guidelines for the management of adults with congenital heart disease: executive summary. A report of the American College of Cardiology/American Heart Association Task Force on Practice Guidelines (writing committee to develop guidelines for the management of adults with congenital heart disease). *Circulation*. 2008; 118: 2395-2451.
- 11 Podolec P, Kopeć G, Rubiś P. Clinical classification of rare cardiovascular diseases and disorders: 2018 update. *Journal of Rare Cardiovascular Diseases*. 2018; 3: 230-235.
- 12 Januszek R, Siudak Z, Dziewierz A, et al. Predictors of in-hospital effectiveness and complications of rotational atherectomy (from the ORPKI Polish National Registry 2014–2016). *Catheter Cardiovasc Interv*. 2018; 92: E278-E287.
- 13 Melfi R, Di Gioia G, Di Sciascio G. Congenital coronary artery fistulas: three different presentations in catheterization laboratory and review of literature. *Medical Imaging and Interventional Radiology*. 2015; 1: e1035.
- 14 Zhou K, Kong L, Wang Y, et al. Coronary artery fistula in adults: evaluation with dual-source CT coronary angiography. *Br J Radiol*. 2015; 88: 20140754.
- 15 Manghelli J, Blitzer D, Leidenfrost J, et al. Fistulous communication between the circumflex artery and right atrium: diagnostic imaging and surgical repair. *Case Reports in Surgery and Invasive Procedures*. 2017; 1: 1-3.
- 16 Liberthson RR, Sagar K, Berkoben JP, et al. Congenital coronary arteriovenous fistula. Report of 13 patients, review of the literature and delineation of management. *Circulation*. 1979; 59: 849-854.
- 17 Challoumas D, Pericleous A, Dimitrakaki I. Coronary arteriovenous fistulae: a review. *Int J Angiol*. 2014; 23: 1-10.
- 18 Vavuranakis M, Bush CA, Boudoulas H. Coronary artery fistulas in adults: incidence, angiographic characteristics, natural history. *Cathet Cardiovasc Diagn*. 1995; 35: 116-120.
- 19 Said SA, Landman GH. Coronary-pulmonary fistula: long-term follow-up in operated and non-operated patients. *Int J Cardiol*. 1990; 27: 203-210.
- 20 Yamanaka O, Hobbs RE. Coronary artery anomalies in 126,595 patients undergoing coronary arteriography. *Cathet Cardiovasc Diagn*. 1990; 21: 28-40.
- 21 Kardos A, Babai L, Rudas L, et al. Epidemiology of congenital coronary artery anomalies: a coronary arteriography study on a central European population. *Cathet Cardiovasc Diagn*. 1997; 42: 270-275.
- 22 Erdem K, Ozbay Y. Prevalence and characteristics of coronary artery anomalies using invasive coronary angiography in 6237 consecutive patients in a single center in Turkey. *Arch Iran Med*. 2018; 21: 240-245.
- 23 Verdini D, Vargas D, Kuo A, et al. Coronary-pulmonary artery fistulas: a systematic review. *J Thorac Imaging*. 2016; 31: 380-390.
- 24 Wichrowska A, Niklas A, Frankiewicz M, et al. Fistula between the right coronary artery and the superior vena cava as a cause of anginal symptoms. *Kardiol Pol*. 2016; 74: 86.
- 25 Wolny R, Pręgoski J, Cyran K, Witkowski A. Acute myocardial infarction due to embolisation from the thrombosed coronary artery fistula between the right coronary artery and the left atrium. *Kardiol Pol*. 2017; 75: 720.
- 26 Aydar Y, Yazici HU, Birdane A, et al. Gender differences in the types and frequency of coronary artery anomalies. *Tohoku J Exp Med*. 2011; 225: 239-247.