

A 47-year-old woman with multifocal fibroelastoma and coronary artery disease

Artur Pawlik¹, Rafał Januszek¹, Renata Rajtar-Salwa¹, Dariusz Dudek², Stanisław Bartuś²

¹ 2nd Department of Cardiology and Cardiovascular Interventions, University Hospital in Kraków, Kraków, Poland

² Department of Interventional Cardiology, Institute of Cardiology, Jagiellonian University Medical College, Kraków, Poland

A 47-year-old woman was admitted to our department for evaluation of chest pain. Symptoms often occurred at rest and were not related to physical exercise or high blood pressure. Medical history revealed recently diagnosed hypertension, hyperlipidemia, hypothyroidism, past smoking, and radiation therapy for Hodgkin lymphoma in childhood. Transthoracic echocardiography and physical examination were unremarkable. Coronary computed tomography angiography (CCTA) demonstrated significant narrowing in the ostial segment of the right coronary artery (RCA). The patient was referred for percutaneous coronary angiography, which confirmed significant stenosis in the proximal RCA (FIGURE 1A). Multiple attempts at crossing the stenosis with several types of guidewires and angioplasty were ineffective. Afterwards, the results of CCTA were reassessed and 2 round myxomatoses were confirmed in the left atrium (FIGURE 1B). Moreover, a small nodule on the ventricular side of the aortic valve leaflet was visualized. The presence of myxomatoses was confirmed by transeptophageal echocardiography (FIGURE 1C). The patient was consulted by a heart team and referred for a surgical procedure including revascularization of the RCA and excision of the 3 masses. During the procedure, 3 frond-like papillary structures from the free wall of the left atrium were successfully removed and an aortocoronary venous bypass was inserted. Based on a histologic examination of the resected specimen, a clinical diagnosis of the papillary fibroelastoma (PFE) was made. The 12-month follow-up was negative for relapse.

With the advances in imaging techniques, the detection of primary cardiac tumors has significantly increased, with an estimated rate

of approximately 0.02% of the general population.¹ Among the primary cardiac tumors, PFE is the third most common type. It usually arises from the valvular endocardium as a solitary lesion. Multifocal, atrial appearance is less frequent.² Although PFE is a benign tumor, its fragile structure may be life-threatening, given its propensity for embolization. Other clinical manifestations described in the literature include heart failure, acute coronary syndromes, and arrhythmia. Therefore, it is generally accepted that even in asymptomatic cases, surgical excision should be promoted, especially if a myxomatous etiology is suspected.³ For that reason, a precise analysis of imaging studies such as CT is crucial in the diagnostic workup. It may help avoid an unnecessary percutaneous coronary intervention (PCI), which is followed by the use of 2 antiplatelet agents that increase bleeding risk and lead to delay in surgical management.

The angiographic anatomy of the RCA is particularly important, as it is unfavorable for PCI and typical for patients who have been irradiated.⁴ This type of ostial lesions could be linked to serious procedural complications such as dissection, including aortic root or occlusion of the artery, making the attempt at PCI dangerous and, in view of the coexistence of a cardiac tumor, unnecessary. On the other hand, if the surgical risk is too high, PCI and long-term anticoagulation should be considered.

In conclusion, our case emphasizes the importance of proper and detailed preprocedural assessment, which is essential to avoid serious complications of unnecessary procedures and to perform a cardiac surgery at the right time with no risk linked to the use of dual antiplatelet therapy after coronary artery stenting.

Correspondence to:

Artur Pawlik, MD,
2nd Department of Cardiology
and Cardiovascular Interventions,
University Hospital in Kraków,
ul. Kopernika 17, 31-501 Kraków,
Poland, phone: +48 12 424 7170,
email: arturo.pawlik@gmail.com
Received: May 31, 2019.

Revision accepted: July 25, 2019.

Published online: July 29, 2019.

Kardiologia Pol. 2019; 77 (9): 888-889
doi:10.33963/KP.14912

Copyright by the Author(s), 2019

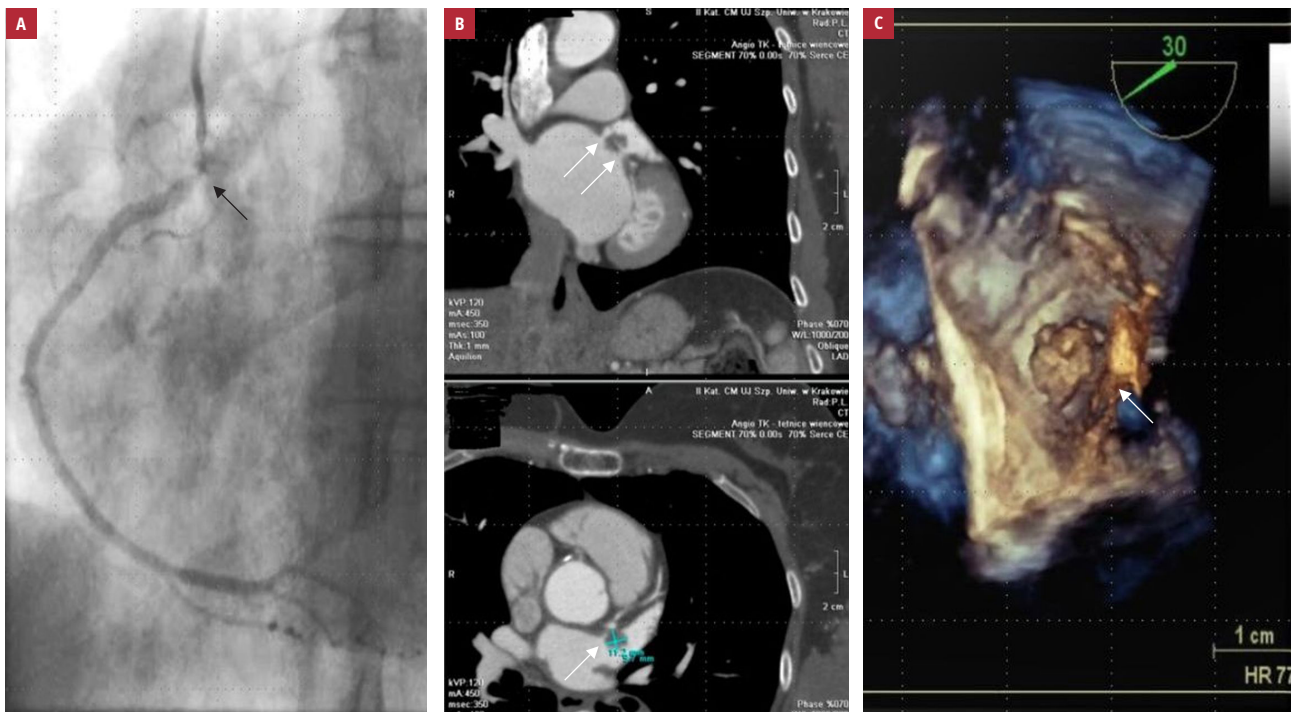


FIGURE 1 **A** – initial coronary angiogram of the right coronary artery, showing significant stenosis in the proximal part of the vessel (arrow); **B** – cardiac computed tomography angiography showing multiple masses in the left atrium (arrows); **C** – transthoracic echocardiogram showing a solid mass in the right atrium (arrow)

ARTICLE INFORMATION

CONFLICT OF INTEREST None declared.

OPEN ACCESS This is an Open Access article distributed under the terms of the Creative Commons Attribution-NonCommercial-NoDerivatives 4.0 International License (CC BY-NC-ND 4.0), allowing third parties to download articles and share them with others, provided the original work is properly cited, not changed in any way, distributed under the same license, and used for non-commercial purposes only. For commercial use, please contact the journal office at kardiologiapolska@ptkardio.pl.

HOW TO CITE Pawlik A, Januszek R, Rajtar-Salwa R, et al. A 47-year-old woman with multifocal fibroelastoma and coronary artery disease. *Kardiol Pol.* 2019; 77: 888-889. doi:10.33963/KP.14912

REFERENCES

- 1 Reynen K. Frequency of primary tumors of the heart. *Am J Cardiol.* 1996; 77: 107.
- 2 Kanarek SE, Wright P, Liu J, et al. Multiple fibroelastomas: a case report and review of the literature. Review. *J Am Soc Echocardiogr.* 2003; 16: 373-376.
- 3 Domenech A, de Arenaza DP, Rivello HG, et al. Surgery for papillary fibroelastoma with uncommon location in left ventricle. *Asian Cardiovasc Thorac Ann.* 2010; 18: 174-176.
- 4 Yusuf SW, Venkatesulu B, Mahadevan LS, et al. Radiation-induced cardiovascular disease: a clinical perspective. *Front Cardiovasc Med.* 2017; 4: 66.