

Anomalous origin of the right coronary artery from the left Valsalva sinus in a patient presenting with syncope, ventricular tachycardia, and electrocardiographic early repolarization pattern

Jacek Majewski¹, Rhidian Shelton¹, Madhusudhan Varma¹, Gershan Davis^{1,2}

¹ North Cumbria University Hospitals NHS Trust, Carlisle, United Kingdom

² University of Central Lancashire, Preston, United Kingdom

An anomalous aortic origin of the right coronary artery (AORCA) with a malignant course between the aorta and pulmonary artery is a rare congenital abnormality, which carries an increased risk of sudden cardiac death (SCD). However, the identification of patients at the highest risk of potentially lethal arrhythmias remains challenging.¹ Syncope may be the first manifestation of AORCA, especially in patients with interarterial compression of the right coronary artery (RCA).²

We present a case of a 62-year-old patient who was referred to the cardiology clinic following an episode of syncope. He was a very fit person, who ran about 20 miles a week. He had never complained of chest pain, palpitations, or any exertional symptoms. The syncopal episode occurred when he was on a gentle walk. He experienced a transient loss of consciousness with complete recovery after only a brief period of confusion. He was assessed by a neurologist, and the results of brain magnetic resonance imaging and electroencephalography were normal. Twelve-lead electrocardiogram (ECG) showed a sinus rhythm of 47 bpm, first-degree atrioventricular block, and early repolarization pattern (ERP) (ST-segment elevations in leads V_3 – V_6 and terminal QRS notching in lead V_6 ; FIGURE 1A). Transthoracic echocardiogram was normal. A treadmill exercise test was performed according to the Bruce protocol.

The patient exercised for 16 minutes and 9 seconds, achieving a maximum heart rate of 151 bpm. There were no symptoms or ECG abnormalities. Twenty-four hour ambulatory ECG monitoring did not reveal any significant arrhythmias, and a cardiac loop recorder was implanted. The patient remained asymptomatic; however, interrogation of the recorder on a routine follow-up visit revealed a nocturnal episode of nonsustained ventricular tachycardia (FIGURE 1B). Coronary computed tomography angiography showed the RCA originating from the left Valsalva sinus, with a malignant course between the aorta and pulmonary artery (FIGURE 1C and 1D). It is likely that the syncope was caused by ventricular arrhythmia triggered by compression of the RCA. In line with the current guidelines, the patient was referred for surgery.³

Interestingly, in our patient, AORCA coexisted with the ERP. An ERP is a common ECG finding, occurring in up to 10% of the general population. It may be a normal ECG variant in athlete patients. However, a small proportion of individuals with an ERP are at risk of SCD. A history of syncope suggestive of arrhythmogenic pathogenesis raises suspicion of a malignant ERP. An ERP is considered a marker of arrhythmogenesis that requires a proarrhythmic trigger.⁴ It is possible that in our patient, transient ischemia caused by the interarterial compression of the RCA precipitated the arrhythmia. Our

Correspondence to:

Jacek Majewski, MD, PhD,
North Cumbria University,
Hospitals NHS Trust,
Cumberland Infirmary,
Department of Cardiology,
Newtown Road CA2 7HY,
Carlisle, United Kingdom,
phone: +44 1228523444,
email: jmajewski@interia.pl
Received: May 30, 2019.

Revision accepted: July 22, 2019.

Published online: July 25, 2019.

Kardiol Pol. 2019; 77 (9): 883-885
doi:10.33963/KP.14909

Copyright by the Author(s), 2019

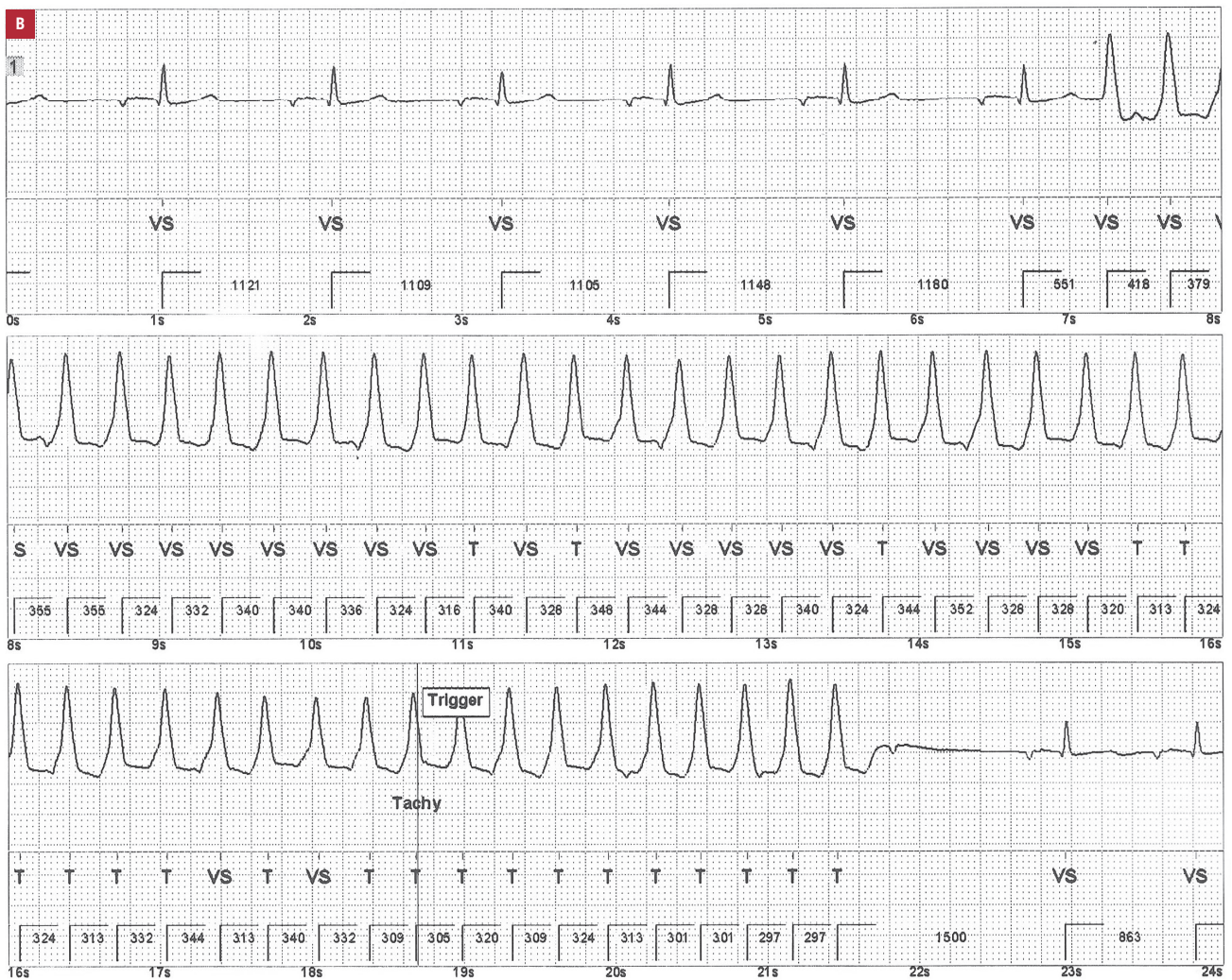
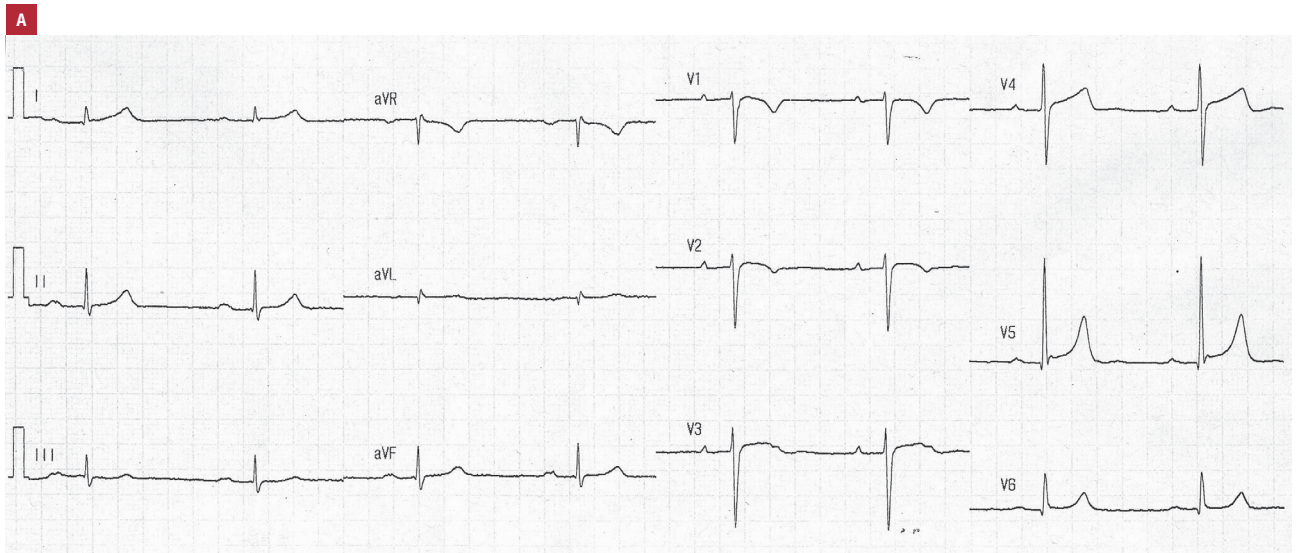
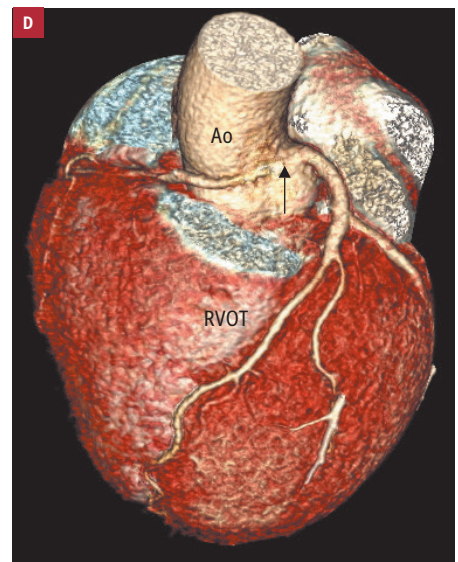
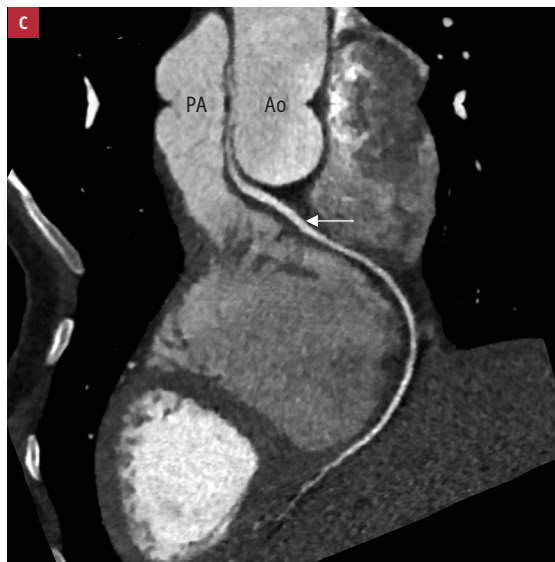

FIGURE 1 A – 12-lead electrocardiogram in a 62-year-old patient with an anomalous origin of the right coronary artery; B – ventricular tachycardia recorded by an implantable loop recorder

FIGURE 1 C, D – coronary computed tomography angiography: right coronary artery originating from the left Valsalva sinus (arrows)

Abbreviations: Ao, aorta; PA, pulmonary artery; RVOT, right ventricular outflow tract



case supports literature data concerning the limited value of stress testing in risk stratification in patients with AORCA.⁵ Further research is needed to evaluate the ERP as a potential ECG marker of SCD in patients with an anomalous origin of a coronary artery.

ARTICLE INFORMATION

CONFLICT OF INTEREST None declared.

OPEN ACCESS This is an Open Access article distributed under the terms of the Creative Commons Attribution-NonCommercial-NoDerivatives 4.0 International License (CC BY-NC-ND 4.0), allowing third parties to download articles and share them with others, provided the original work is properly cited, not changed in any way, distributed under the same license, and used for non-commercial purposes only. For commercial use, please contact the journal office at kardiologiapolska@ptkardio.pl.

HOW TO CITE Majewski J, Shelton R, Varma M, Davis G. Anomalous origin of the right coronary artery from the left Valsalva sinus in a patient presenting with syncope, ventricular tachycardia, and electrocardiographic early repolarization pattern. *Kardiol Pol.* 2019; 77: 883-885. doi:10.33963/KP.14909

REFERENCES

- 1 Cheezum MK, Liberthson RR, Shah NR, et al. Anomalous aortic origin of a coronary artery from the inappropriate sinus of Valsalva. *J Am Coll Cardiol.* 2017; 69: 1592-1608.
- 2 Opolski MP, Pregowski J, Kruk M, et al. Prevalence and characteristics of coronary anomalies originating from the opposite sinus of Valsalva in 8,522 patients referred for coronary computed tomography angiography. *Am J Cardiol.* 2013; 111: 1361-1367.
- 3 Brothers JA, Frommelt MA, Jaquiss RDB, et al. Expert consensus guidelines: anomalous aortic origin of a coronary artery. *J Thorac Cardiovasc Surg.* 2017; 153: 1440-1457.
- 4 Patton KK, Ellinor PT, Ezekowitz M, et al. Electrocardiographic early repolarization. A scientific statement from the American Heart Association. *Circulation.* 2016; 133: 1520-1529.
- 5 Basso C, Maron BJ, Corrado D, et al. Clinical profile of congenital coronary artery anomalies with origin from the wrong aortic sinus leading to sudden death in young competitive athletes. *J Am Coll Cardiol.* 2000; 35: 1493-1501.