

Decompression of suprasystemic right ventricular pressure as palliative treatment for a child with tetralogy of Fallot

Jacek Kuźma, Paweł Skorek, Maciej Pitak, Katarzyna Konarska, Piotr Weryński

Department of Pediatric Cardiology, University Children's Hospital, Jagiellonian University Medical College, Kraków, Poland

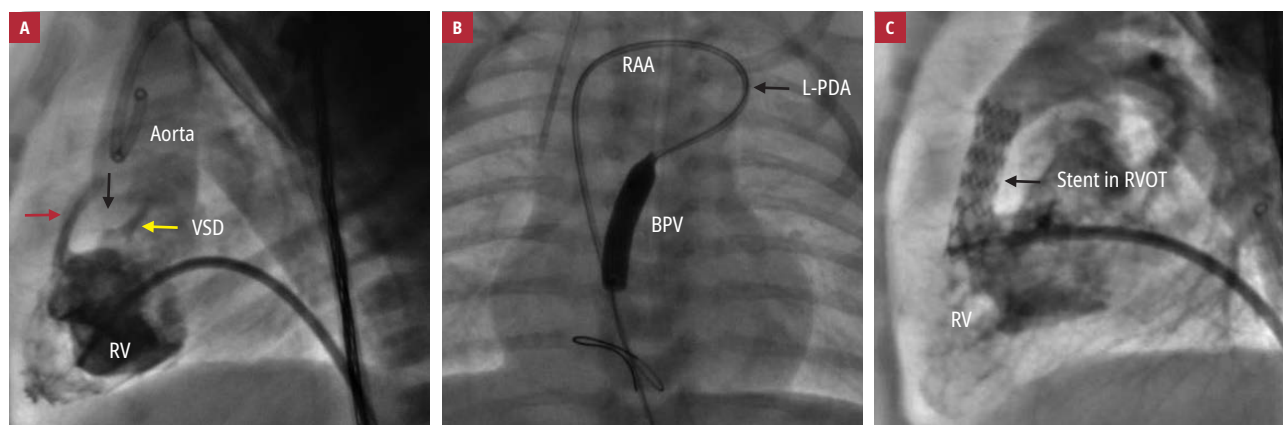


FIGURE 1 **A** – right ventriculography (90° lateral view): severe subpulmonary stenosis (red arrow) due to the thick conal septum (black arrow); ventricular septal defect (yellow arrow) extremely restricted by the additional tricuspid valve tissue; **B** – balloon pulmonary valvuloplasty (anteroposterior view): the arterial access through the right aortic arch, left patent arterial duct, pulmonary trunk, and, finally, right ventricular outflow tract; **C** – right ventriculography (90° lateral view): wide outflow tract with an implanted stent

Patients with tetralogy of Fallot (TOF) have impaired pulmonary flow due to an obstructed right ventricular outflow tract (RVOT), pulmonary valve or supra-valvular stenosis, or hypoplastic pulmonary arteries. In newborns, alprostadil infusion provides the patency of the arterial duct, ensuring adequate pulmonary flow. As the next stage of treatment, some children may be referred for Blalock–Taussig or central aortopulmonary anastomosis as well as Brock operation with relief of RVOT obstruction.¹⁻³ However, in some cases, interventional procedures including balloon valvuloplasty, RVOT, or arterial duct stent implantation seem to be the best option.

Conventionally, the RVOT stenting pathway is from the side of the severely hypertrophied

right ventricle (RV); however, in patients at high risk of cardiac surgery, we offer an alternative interventional approach that involves stenting of significant subpulmonary stenosis. This is achieved by utilizing an arterial approach through the right aortic arch, patent arterial duct, and, finally, through the RVOT.

We present a case of a newborn delivered at term, with a body weight of 2900 g. A pulse oximetry test showed a mild desaturation of 85%, and transthoracic echocardiography revealed a diagnosis of TOF, for which prostaglandin E1 infusion was initiated. The patient was then transferred to our center, where we confirmed the diagnosis of TOF with restrictive ventricular septal defect, significant subpulmonary stenosis with suprasystemic RV pressure, right

Correspondence to: Jacek Kuźma, MD, PhD, Department of Pediatric Cardiology, University Children's Hospital, Jagiellonian University Medical College, ul. Wielicka 265, 30-663 Kraków, Poland, phone: +48 512 170 838, email: kuzmajacek@yahoo.com
Received: March 3, 2019.

Revision accepted: March 19, 2019.

Published online: May 24, 2019.
Kardiologia Pol. 2019; 77 (5): 578-579
doi:10.33963/KP.14849

Copyright by Polskie Towarzystwo Kardiologiczne, Warszawa 2019

aortic arch with a wide patent left arterial duct from the left innominate artery, and coronary artery anomaly crossing the RVOT. The risk of cardiac surgery was considered high, and the patient was referred for interventional treatment. The access was through the right femoral artery (4/5-F sheath) and femoral vein (5/6-F sheath). Hemodynamic evaluation revealed suprasystemic RV pressure with increased RV end-diastolic pressure (13 mm Hg), significant RVOT obstruction (FIGURE 1A and Supplementary material, *Video S1*), and restrictive ventricular septal defect with a gradient pressure of 60 mm Hg.

The RVOT was extremely stenotic, which meant that the wire could not be passed through. Therefore, we used an alternative arterial approach through the right aortic arch, left patent arterial duct, pulmonary trunk, and, finally, the RV, with a Berenstein 4–100 catheter and a Terumo 0.014–150 wire. Initially, pulmonary balloon valvuloplasty was performed (FIGURE 1B and Supplementary material, *Video S2*) with a Terumo 6 mm/2 cm balloon catheter in order to proceed the stent forward. Finally, a Palmaz Blue 6 mm/15 mm stent was implanted into the RVOT, decompressing the suprasystemic RV and thus providing adequate pulmonary flow. On right ventriculography, the outflow tract was wide and the stent was stable (FIGURE 1C and Supplementary material, *Video S3*). The RV pressure dropped to the systemic value. The patient was discharged home and underwent the cardiosurgical correction at the age of 10 months, with an adequate final result.

In conclusion, RVOT stenting is an optimal palliative solution for children with low body weight and multiple organ defects when the surgery seems to be of high risk.

SUPPLEMENTARY MATERIAL

Supplementary material is available at www.mp.pl/kardiologiapolska.

ARTICLE INFORMATION

CONFLICT OF INTEREST None declared.

HOW TO CITE Kuźma J, Skorek P, Pitak M, et al. Decompression of suprasystemic right ventricular pressure as palliative treatment for a child with tetralogy of Fallot. *Kardiol Pol.* 2019; 77: 578–579. doi:10.33963/KP.14849

REFERENCES

- 1 Sandoval JP, Chaturvedi RR, Benson L, et al. Right ventricular outflow tract stenting in Tetralogy of Fallot infants with risk factors for Early Primary Repair. *Circ Cardiovasc Interv.* 2016; 9: e003979.
- 2 Dryżek P, Moszura T, Górecki S, Michalak KW. Stenting of the right ventricular outflow tract in a symptomatic newborn with tetralogy of Fallot. *Postępy Kardiologii Interwencyjnej.* 2015; 11: 44–47.
- 3 Dohlen G, Chaturvedi RR, Benson LN, et al. Stenting of the right ventricular outflow tract in the symptomatic infant with tetralogy of Fallot. *Heart.* 2009; 95: 142–147.