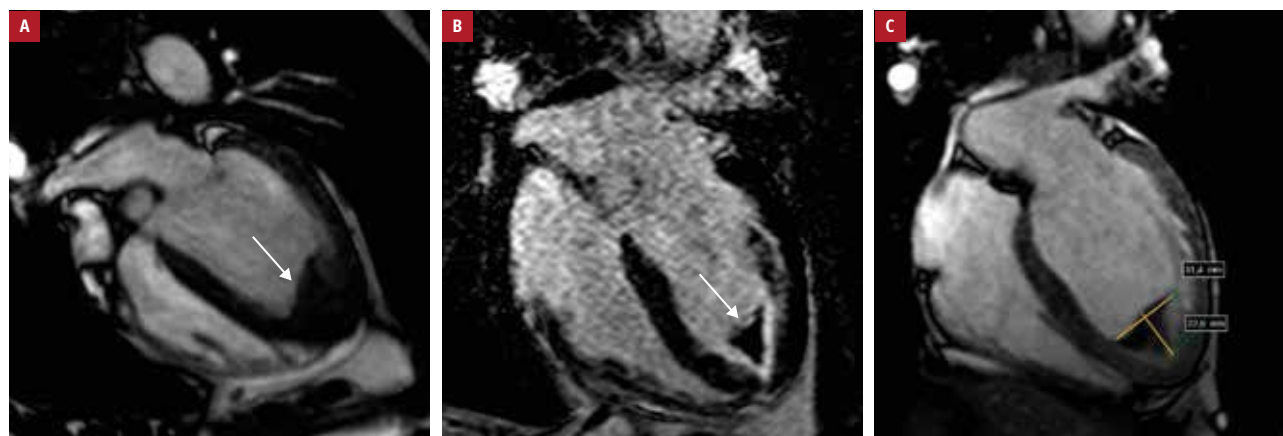


# Intraventricular thrombus progression due to poor compliance with anticoagulant treatment in a patient with hypereosinophilic and antiphospholipid syndromes

Karolina Szymańska, Marcin Książczyk, Agnieszka Dębska-Kozłowska, Tomasz Grycewicz, Andrzej Lubiński

Department of Interventional Cardiology and Cardiac Arrhythmias, Medical University of Lodz, Łódź, Poland



**FIGURE 1** An initial cardiac magnetic resonance: an apical left ventricular thrombus (arrow) and areas of endocardial fibrosis; **A** – cinematographic sequence; **B** – late gadolinium enhancement sequence; **C** – early gadolinium enhancement sequence in the 4-chamber view

Hypereosinophilic syndrome is an uncommon disorder defined as persistent eosinophilia (absolute eosinophil count  $>1500/\mu\text{l}$ ) associated with single or multiple organ dysfunction, where other causes of hypereosinophilia have been excluded. Cardiac involvement occurs in more than 50% of cases and is a major cause of morbidity and mortality in this patient group.<sup>1-3</sup> The outcome depends on the development of endocardial fibrosis and related complications; therefore, early diagnosis and proper medical treatment are crucial to prevent disease progression.

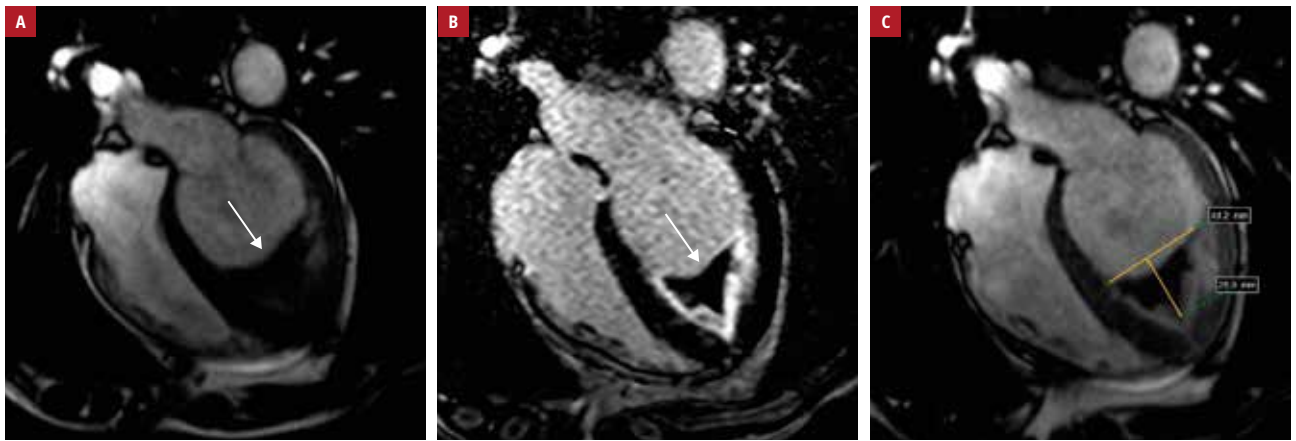A 63-year-old man was referred to our department due to exacerbation of heart failure symptoms and atypical chest pain. Six months earlier he was diagnosed with hypereosinophilic

syndrome and antiphospholipid syndrome involving the heart and leading to endocardial fibrosis and apical thrombus formation in the left ventricle (LV), as shown on cardiac magnetic resonance (FIGURE 1). Because of a mental disorder, the patient presented poor compliance with anticoagulant (low-molecular-weight heparin [LMWH]) and immunosuppressive treatment since the last hospitalization.

Transthoracic echocardiography on admission showed an extremely large thrombus almost occluding the LV from the mid to apical segments, with an impairment of LV contractility. A comparative cardiac magnetic resonance confirmed thrombus enlargement from  $22 \times 31$  mm to  $29 \times 44$  mm and revealed a more advanced

**Correspondence to:**  
Marcin Książczyk, MD, Department of Interventional Cardiology and Cardiac Arrhythmias, Medical University of Lodz, ul. Żeromskiego 113, 90-549 Łódź, Poland, phone: +48 42 639 35 63, email: marcin\_książczyk@interia.pl  
Received: January 10, 2019.  
Revision accepted: January 30, 2019.

Published online: April 25, 2019.  
Kardiologia Polska. 2019; 77 (4): 480-481  
doi:10.33963/KP.14802  
Copyright by Polskie Towarzystwo Kardiologiczne, Warszawa 2019



**FIGURE 2** A comparative cardiac magnetic resonance at 6 months after a period of poor compliance to anticoagulant treatment: an extremely large thrombus (arrow) in the apical to mid segments of the left ventricle and more extended areas of advanced endocardial fibrosis; **A** – cinematographic sequence; **B** – late gadolinium enhancement sequence; **C** – early gadolinium enhancement sequence in the 4-chamber view

endocardial fibrosis (FIGURE 2). Evidence-based therapy was administered with LMWH, azathioprine, and glucocorticoids, and the patient was finally discharged to a nursing home where he received optimal medical treatment to improve his compliance.

Follow-up transthoracic echocardiography at 3 months showed a significant decrease in the thrombus size without complete dissolution; LMWH was switched to acenocumarol dosed according to the recommended therapeutic international normalized ratio range of 2 to 3.

#### ARTICLE INFORMATION

**CONFLICT OF INTEREST** None declared.

**HOW TO CITE** Szymańska K, Książczyk M, Dębska-Kozłowska A, et al. Intraventricular thrombus progression due to poor compliance with anticoagulant treatment in a patient with hypereosinophilic and antiphospholipid syndromes. *Kardiologia Pol.* 2019; 77: 480-481. doi:10.33963/KP.14802

#### REFERENCES

- 1 Kleinfeldt T, Nienaber CA, Kische S, et al. Cardiac manifestations of the hypereosinophilic syndrome: new insights. *Clin Res Cardiol.* 2010; 99: 419-427.
- 2 Beedupalli J, Modi K. Early-stage Loeffler's endocarditis with isolated right ventricular involvement: management, long-term follow-up, and review of literature. *Echocardiography.* 2016; 33: 1422-1427.
- 3 Sivasankaran S, Harikrishnan S, Tharakan JM. Left ventricular thrombi in the presence of normal left ventricular function. *Indian Heart J.* 2002; 54: 196-198.