

Every percent matters: pitfalls in the mapping and ablation of arrhythmogenic foci arising from the right coronary cusp or right ventricular outflow tract

Piotr Gardziejczyk, Aleksander Maciąg, Michał M. Farkowski, Mariusz Pytkowski

2nd Department of Coronary Artery Disease, Institute of Cardiology, Warsaw, Poland

There is a close anatomical relationship between the right ventricular outflow tract (RVOT) and right coronary aortic cusp. We present a 28-year-old patient with frequent, highly symptomatic, drug-refractory premature ventricular contractions (PVCs) (FIGURE 1A). On 72-hour Holter electrocardiogram (ECG) monitoring, frequent monomorphic PVCs were shown (136 000 PVCs; approximately 45 000 PVCs/d). There were no abnormalities on transthoracic echocardiography. The specific features of arrhythmias of the RVOT are as follows: inferior axis of QRS PVC (R waves in leads II, III, aVF), left bundle branch block morphology, late precordial transition below lead V₃ (transition from negative QRS PVC [r < S] to positive QRS PVC [R > S]). The early precordial transition zone (V₁–V₂) of QRS PVC favors the left outflow tract site or coronary cusps.^{1–3} In our case, the precordial transition zone was between leads V₃ and V₄, and it was a rare case when ECG algorithms failed to localize the arrhythmogenic foci. It should be kept in mind that there may be numerous possible arrhythmogenic sites of origin: in more than half of the cases, it will be the RVOT or the pulmonary trunk. However, other arrhythmogenic sites of origin should also be considered, such as aortic valve, epicardiac space between aorta and RVOT, or space localised epicardially along cardiac veins.³

The electroanatomical mapping was made using the 3-dimensional mapping system (EnSite Velocity, Abbott, St. Paul, Minnesota, United States). Paced QRS concordance was analyzed by an electrophysiological system with automated

template matching software (LABSYSTEM Pro, Boston Scientific, Lowell, Massachusetts, United States). We started mapping from the RVOT and pulmonary trunk using a standard 4-mm nonirrigated tip catheter (Marinr, Medtronic, Minneapolis, Minnesota, United States). At an initial site, the local ventricular activation preceded the onset of the PVC by 28 ms (Supplementary material, Figure S1A) and the mean concordance of paced QRS was 97% (Supplementary material, Figure S2C), but radiofrequency (RF) application was unsuccessful. In the next step, mapping of the aortic valve was performed with slightly better concordance than in the RVOT (98% on pace-mapping) (Supplementary material, Figure S2B), but the local ECG preceded the onset of the PVC by 40 ms (Supplementary material, Figure S1B).⁴ Before RF applications, a nonselective angiography of the aortic root was performed. This time the RF application was successful and allowed for localization and complete elimination of arrhythmogenic foci in the right coronary sinus of Valsalva. The number of RF applications was 10, the total ablation time was 322 seconds, fluoroscopy time was 10 minutes and 9 seconds, and procedure time was 140 minutes.

This case is an example of possible difficulties in localization of arrhythmogenic foci in 2 anatomical structures of the heart, which are very close to each other (FIGURE 1B). In those regions of the heart, detailed intracardiac mapping is essential to properly localize the arrhythmogenic foci. Our patient with normal heart ventricular arrhythmia represents a group of patients in whom ECG algorithms are less useful

Correspondence to:

Piotr Gardziejczyk, MD,
2nd Department of Coronary Artery
Disease, Institute of Cardiology,
ul. Alpejska 42, 04-628 Warsaw,
Poland, phone: +48 22 343 40 02,
email: pgardziejczyk@ikard.pl
Received: December 17, 2018.

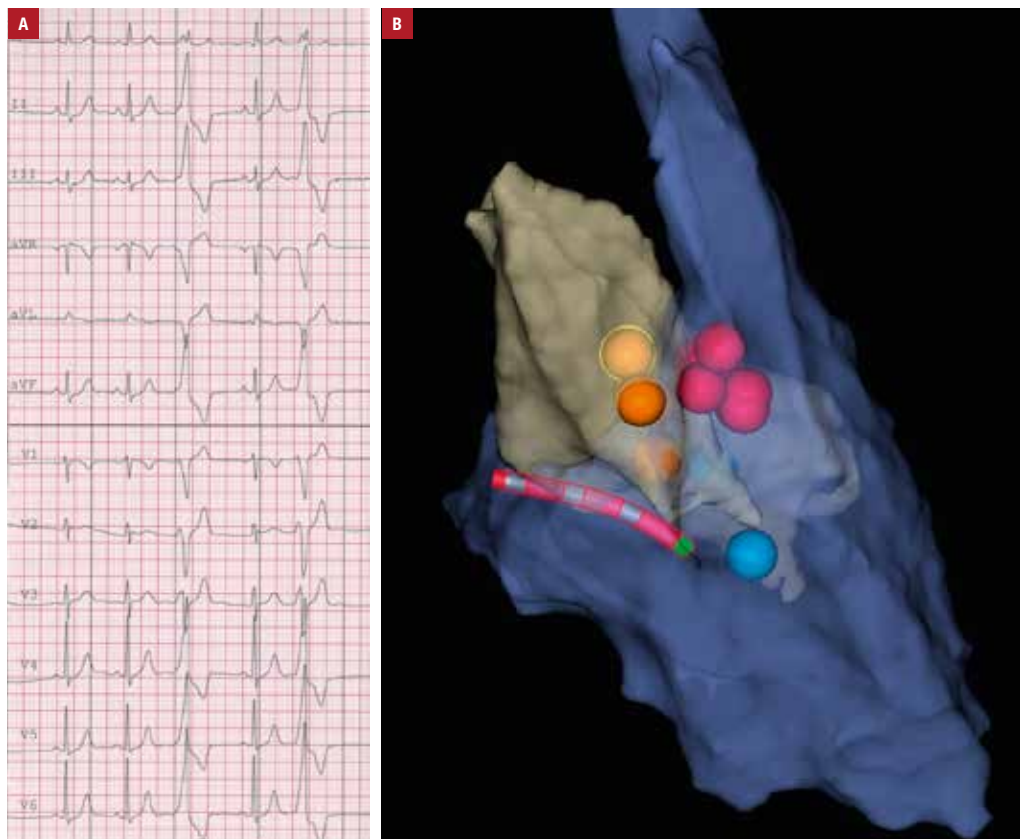
Revision accepted:

January 28, 2019.

Published online: April 25, 2019.
Kardiologia Pol. 2019; 77 (4): 478–479
doi:10.33963/KP.14800

Copyright by Polskie Towarzystwo
Kardiologiczne, Warszawa 2019

FIGURE 1 **A** – 12-lead electrocardiogram showing morphology of premature ventricular contractions; **B** – electroanatomical 3-dimensional map. Points of radiofrequency applications: orange, applications in the right coronary cusp; pink, applications in the right ventricular outflow tract



in the localization of arrhythmogenic foci. Those patients have typical ECG morphology of arrhythmia, with the transition zone in the precordial leads located in lead V₃.

The patient remained asymptomatic and 24-hour Holter ECG monitoring showed no ventricular arrhythmias, only a few premature supraventricular contractions within 4 months of follow-up.

SUPPLEMENTARY MATERIAL

Supplementary material is available at www.mp.pl/kardiologiapolska.

ARTICLE INFORMATION

CONFLICT OF INTEREST None declared.

HOW TO CITE Gardziejczyk P, Maciąg A, Farkowski MM, Pytkowski M. Every percent matters: pitfalls in the mapping and ablation of arrhythmogenic foci arising from the right coronary cusp or right ventricular outflow tract. *Kardiol Pol.* 2019; 77: 478-479. doi:10.33963/KP.14800

REFERENCES

- Ouyang F, Fotuhi P, Ho SJ, et al. Repetitive monomorphic ventricular tachycardia originating from the aortic cusp: electrocardiographic characterization for guiding catheter ablation. *J Am Coll Cardiol.* 2002; 39: 500-508.
- Pytkowski M, Maciąg A, Sterliński M, et al. Novel algorithm for arrhythmogenic focus localization in patients with right ventricular outflow tract arrhythmias. *Cardiology J.* 2014; 21: 284-292.
- Noheria A, Deshmukh A, Asirvatham SJ. Ablating premature ventricular complexes: justification, techniques, and outcomes. *Methodist Debaquey Cardiovasc J.* 2015; 11: 109-120.
- Kuteszko R, Pytkowski M, Farkowski MM, et al. Utility of automated template matching for the interpretation of pace mapping in patients ablated due to outflow tract ventricular arrhythmias. *Europace.* 2015; 17: 1428-1434.