

The role of tissue colour Doppler imaging in diagnosis of segmental pulmonary embolism in congestive heart failure patients

Leszek Gromadziński, Ryszard Targoński

Department of Cardiology and Internal Diseases, City Hospital, Olsztyn, Poland

Abstract

Background: Tissue Doppler imaging enables qualitative and quantitative assessment of myocardial function of the left and right ventricles.

Aim: To compare systolic longitudinal mitral and tricuspid annular velocities in a congestive heart failure (CHF) patient group with clinical suspicion of pulmonary embolism (PE).

Methods: Fifty-five consecutive CHF patients with a history of abrupt onset of resting dyspnoea, elevated >35 mmHg right ventricular systolic pressure (RVSP) and positive D-dimer test were included in the study. Patients underwent standard echocardiography and tissue colour Doppler imaging with post-processing analysis (Echopack 6.3, GE Vingmed) and spiral computed tomography (SCT) within 24 hours from admission. Mitral and tricuspid annular longitudinal systolic and diastolic velocities were measured at their lateral sites in a 4-chamber apical view. According to the results of the SCT examination patients were classified into groups: PE positive (group 1 – 25 patients) and PE negative (group 2 – 30 patients).

Results: Tricuspid annular lateral systolic velocity (SmRV) was 6.5 ± 2.6 cm/s in group 1 and 7.0 ± 2.5 cm/s in group 2 ($p=NS$). Mitral annular lateral systolic velocity (SmLV) was 6.4 ± 3.0 cm/s and 4.3 ± 2.0 cm/s in group 1 and group 2 respectively ($p=0.003$). Patients diagnosed as PE cases showed statistically significant higher mitral annular lateral systolic velocity. Using a cut-off value of >5.5 cm/s derived from receiver operating characteristics curve analysis, patients were separated from those without PE with sensitivity of 60% and specificity of 86.7%. The ratio of SmRV/SmLV was 1.1 ± 0.4 and 1.73 ± 0.87 in group 1 and group 2, respectively ($p=0.001$). Using a cut-off value ratio of ≤ 1.2 derived from receiver operator characteristic curve analysis, patients were separated from those without PE with a sensitivity of 76% and a specificity of 93.3%.

Conclusion: Mitral annular lateral systolic velocity above 5.5 cm/s and ratio of systolic lateral tricuspid annular velocity to systolic lateral mitral annular velocity ≤ 1.2 are useful parameters of pulmonary embolism in congestive heart failure patients.

Key words: tissue colour Doppler imaging, pulmonary embolism, congestive heart failure

Kardiologia Polska 2007; 65: 1433–1439

Introduction

Tissue Doppler imaging is a short, bedside and non-invasive echocardiographic examination. Due to selective recording of velocity from the myocardial area but not from cardiac chambers it enables complete quantitative and objective assessment of regional myocardial performance [1]. Several studies have confirmed the hypothesis that myocardial damage is associated with decreased velocity within the mitral or tricuspid annulus as well as cardiac wall segments. By evaluating systolic velocity of the mitral annulus in tissue Doppler examination the impairment of both systolic and diastolic left ventricular (LV) function can

be detected [2-5]. Right ventricular (RV) performance is assessed by means of measurement of the tricuspid annular velocity [6, 7]. In patients with chronic heart failure (CHF), a reduction in maximal systolic velocities of both annuli in tissue Doppler imaging has been observed [8]. It was shown that right heart overload, e.g. caused by primary pulmonary hypertension (PPHT), led to decreased tricuspid annular systolic velocity. Pulmonary thromboembolism (PE) may also cause RV overload, thus leading to the reduction of RV free wall as well as tricuspid annular systolic velocities. Patients with CHF very often manifest increased RV pressure that may result from either CHF or PE.

Address for correspondence:

Leszek Gromadziński MD, Oddział Kardiologiczno-Internistyczny, Miejski Szpital Zespolony, ul. Niepodległości 44, 10-045 Olsztyn, tel.: + 48 89 527 22 35, +48 89 532 62 86, faks: +48 89 527 22 35, e-mail: lgol@op.pl

Received: 16 May 2007. **Accepted:** 06 September 2007.

Pulmonary thromboembolism in patients with CHF is associated with adverse prognosis resulting also from limitations of rapid bedside diagnostic procedures.

The purpose of this study was to assess the velocity of tricuspid and mitral annular motion in patients with CHF accompanied by PE.

Methods

Patients

This prospective study involved 55 patients with CHF found in functional NYHA classes III and IV admitted to hospital due to acute resting dyspnoea.

Inclusion criteria were as follows:

- 1) increased right ventricular systolic pressure (RVSP) exceeding 35 mmHg in transthoracic echocardiography,
- 2) positive D-dimer test (higher than 0.5 µg/ml measured by means of ELISA Liatest method),
- 3) spiral single-row chest computed tomography (CT) to detect PE within 24 hours after admission to hospital,
- 4) colour tissue Doppler imaging including a calculation of tricuspid and mitral annular motion velocities carried out within 24 hours after admission to hospital.

Based on CT result, patients were split into two groups: group with confirmed PE (25 patients), and group without PE (30 patients). The groups did not differ with respect to age, gender or CHF aetiology. In the PE(+) group 11/25 (44%) presented with systolic CHF [LV ejection fraction (LVEF) <45%], compared to 15/30 (50%) in the PE(-) group; in the remaining patients diastolic CHF was detected. The study was approved by the Local Bioethical Committee, a section of Warmińsko-Mazurska Izba Lekarska, Olsztyn.

Table I. Clinical and echocardiographic variables in patients with or without pulmonary thromboembolism (PE)

Variable	PE(+) n=25	PE(-) n=30	p
Age	75±10	73±11	NS
Males	12 (48%)	16 (53%)	NS
Systolic HF	11 (44%)	15 (50%)	NS
LVDD [mm]	52±10	55±10	NS
RVDD [mm]	35±5	34±5	NS
RVSP [mmHg]	58±17	54±18	NS
LVEF [%]	49±13	45±15	NS
IVC diameter [mm]	25±3	26±4	NS
D-dimer [µg/ml]	7.8±11	3.2±3.8	0.02
Sinus rhythm	13 (52%)	15 (50%)	NS
Atrial fibrillation	12 (48%)	15 (50%)	NS

Abbreviations: LVDD – left ventricular diastolic dimension, RVDD – right ventricular diastolic dimension, RVSP – right ventricular systolic pressure, LVEF – left ventricular ejection fraction, IVC – inferior vena cava

Echocardiographic examination

In all patients, standard echocardiographic study (System 5, Vingmed General Electric) and colour tissue Doppler imaging with computer analysis of the recorded images (post-processing analysis Echopack 6.3 GE Vingmed) equipped with a 2.5 MHz probe was performed. Recording of Doppler images was performed during normal breathing. In the standard echocardiography, several parameters including LV diastolic dimension (LVDD), right ventricular diastolic dimension (RVDD), right ventricular systolic pressure (RVSP) and LVEF were evaluated.

Moreover, in order to assess RV performance, tricuspid annular plane systolic excursion (TAPSE) was measured as well as Tei index for both RV and LV. Measurement of systolic LV function was based on the modified Simpson method. Simplified Bernoulli method with approximation of right atrial pressure to 10 mmHg was used to evaluate RVSP in all patients independently from inferior vena cava diameter and its reaction to deep breathing. Colour tissue Doppler imaging was performed in all patients in the left lateral position during normal breathing. Inserting a gate of spectral Doppler to the lateral portion of the mitral annulus of the posterior mitral leaflet, velocity profile was recorded. The RV function in the longitudinal axis was assessed in a similar manner, measuring the lateral segment of tricuspid annulus motion close to the anterior tricuspid leaflet. The following parameters were evaluated: peak systolic velocity skipping, mitral annular isovolumetric systole peak velocity (SmLV) and tricuspid annular one (SmRV), peak velocity of early diastole (Em), peak velocity of late diastole (Am) of both examined annuli. All measured parameters were assessed as the mean of 2 to 3 consecutive cardiac cycles.

Computed tomography

Spiral single-row CT to detect PE with additional high resolution CT assessment was performed in all patients within the first 24 hours after hospital admission.

Statistical analysis

Clinical and echocardiographic data are presented as mean±standard deviation. The χ^2 test was used to compare categorical variables and Student's t-test for continuous variables, respectively. A p value <0.05 was considered statistically significant. Optimal cut-off values for the selected variables were calculated by means of ROC (receiver operator characteristic) curves.

Results

Examined group characteristics

Clinical and standard echocardiographic variables for both groups of patients are presented in Table I.

The groups were similar with respect to age, gender, LVEF, RVSP and other parameters calculated in standard

transthoracic echocardiography. Only D-dimer concentrations were higher in the group with confirmed PE (7.8 ± 11 vs. 3.2 ± 3.8 $\mu\text{g/ml}$, $p=0.02$). Optimal cut-off point calculated in the ROC analysis for this parameter was >3.2 . For this D-dimer concentration, sensitivity was 62.5% and specificity 79.3% in the group of patients with confirmed diagnosis of PE.

Tricuspid annular plane systolic excursion (TAPSE) in patients with PE was decreased in comparison to group without PE (1.38 ± 0.3 vs. 1.65 ± 0.28 cm, respectively; $p=0.002$). The optimal cut-off value calculated in the ROC analysis for TAPSE was ≤ 1.4 cm. For this value of TAPSE, sensitivity was 68% and specificity 73.3% in the group with PE. The Tei RV index in group with PE was significantly higher than in group PE(-) (0.62 ± 0.1 vs. 0.56 ± 0.08 , respectively; $p=0.04$). The optimal cut-off value of this parameter assessed in the ROC analysis was >0.62 . This value separated patients with confirmed PE and those without PE with a sensitivity of 54.5% and a specificity of 75.9%. The Tei LV index did not differ significantly between the examined groups of patients.

Among 25 patients with PE, in 18 of them PE was classified as non-massive, in another 6 as submassive and in 1 as massive treated with streptokinase. In all patients of both groups, troponin T concentration was also measured. In patients with confirmed PE elevated troponin T >0.04 ng/ml was observed in 7 patients, whereas in group PE(-) in 4 patients. Patients with PE and increased troponin T concentration, probably associated with RV injury, presented slower SmRV than the subjects with troponin T concentrations found within the normal range (5.9 ± 2.0 and 6.6 ± 3.0 cm/s, respectively, NS). Similar findings were revealed for SmLV (5.2 ± 2 and 6.5 ± 3.0 cm/s, respectively, NS).

Both examined groups differed significantly with respect to the parameters of tissue colour Doppler imaging such as SmLV, AmLV, Em/AmLV, Em/AmRV but not regarding other evaluated parameters, i.e. SmRV, EmRV, AmRV and EmRV. The results of echocardiographic imaging are presented in Table II. The optimal cut-off value assessed in the ROC analysis for SmRV/SmLV parameter was ≤ 1.2 . For this value, sensitivity of this index in group PE(+) was 76%, and specificity 93.3% (Figure 1). The optimal cut-off value for SmLV was >5.5 cm/s and this value separated patients with PE from patients without PE with a sensitivity of 60% and a specificity of 86.7% (Figure 2).

Patients presenting both systolic and diastolic CHF were also evaluated. In group PE(+) the number of patients with systolic CHF was 11/25 (44%), while in group PE(-) it was 15/30 (50%). In the remaining pts. diastolic form of CHF was diagnosed. Patients with systolic and diastolic CHF were analysed separately. In the group of patients with diastolic CHF, the lateral portion of the tricuspid valve annular systolic velocity (SmRV) was 7.6 ± 2.6 cm/s in the PE(+) group and 8.8 ± 2.2 cm/s in

Table II. Variables evaluated in colour tissue Doppler imaging in the group of patients with confirmed diagnosis of pulmonary thromboembolism (group 1; $n=25$) and in the group of patients without pulmonary thromboembolism (group 2; $n=30$).

Variable	Group 1	Group 2	p
SmLV [cm/s]	6.4 ± 3.0	4.3 ± 2.0	0.003
EmLV [cm/s]	4.2 ± 3.0	4.3 ± 2.1	NS
AmLV [cm/s]	8.3 ± 3.3	3.9 ± 2.4	0.0004
Em/AmLV	0.5 ± 0.2	1.7 ± 1.5	0.006
SmRV [cm/s]	6.5 ± 2.6	7.0 ± 2.5	NS
EmRV [cm/s]	4.6 ± 2.9	6.4 ± 2.6	NS
AmRV [cm/s]	8.7 ± 3.3	6.1 ± 3.5	NS
Em/AmRV	0.7 ± 0.7	1.6 ± 1.4	0.04
SmRV/SmLV	1.1 ± 0.4	1.73 ± 0.87	0.001
TAPSE [cm]	1.38 ± 0.3	1.65 ± 0.28	0.002
Tei RV index	0.62 ± 0.1	0.56 ± 0.08	0.04
Tei LV index	0.56 ± 0.11	0.55 ± 0.06	NS

Abbreviations: SmLV – peak systolic velocity of the mitral annulus lateral portion, EmLV – peak early diastolic velocity of the mitral annulus lateral portion, AmLV – peak late diastolic velocity of the mitral annulus lateral portion, Em/AmLV – ratio of early to late diastolic velocity of the mitral valve lateral portion, SmRV – peak systolic velocity of the tricuspid annulus lateral portion, EmRV – peak early diastolic velocity of the tricuspid annulus lateral portion, AmRV – peak late diastolic velocity of the tricuspid annulus lateral portion, Em/AmRV – ratio of early to late diastolic velocity of the tricuspid valve lateral portion, SmRV/SmLV – ratio of peak systolic velocity of the tricuspid annulus lateral portion to peak systolic velocity of the mitral annulus lateral portion, TAPSE – tricuspid annular plane systolic excursion

patients without PE (NS). The lateral portion of SmLV was 7.7 ± 2.6 cm/s and 5.2 ± 1.5 cm/s, in group PE(+) and group PE(-), respectively ($p=0.003$). The optimal cut-off value for SmLV was >5.5 cm/s and was found at the same level for the whole group of patients. The sensitivity and specificity of this parameter in group PE(+) was 78.6 and 80%, respectively. The SmRV/SmLV parameter was 1.76 ± 0.43 in patients without PE and 1.04 ± 0.33 in group with PE ($p=0.00003$). The optimal value of cut-off point for the whole examined population regarding this parameter was ≤ 1.16 , with a sensitivity of 78%, and a specificity of 100%, respectively.

In the group of patients with systolic CHF, systolic velocities of either tricuspid or mitral annulus were decreased in comparison to patients with diastolic CHF. The value of SmRV was 5.2 ± 2.0 in group PE(+) and 6.1 ± 2.3 cm/s in group PE(-) (NS). The value of SmLV was 4.7 ± 2.0 and 3.1 ± 1.3 cm/s in these groups respectively ($p=0.02$) and the optimal cut-off value calculated in the ROC analysis for SmLV was 4.8 cm/s. For this value, sensitivity and specificity in group PE(+) were 45% and 93%, respectively. Meanwhile, SmRV/SmLV index was 1.19 ± 0.47 in group PE(+) and 2.2 ± 1.1 in group PE(-) ($p=0.008$). The optimal cut-off value for this parameter

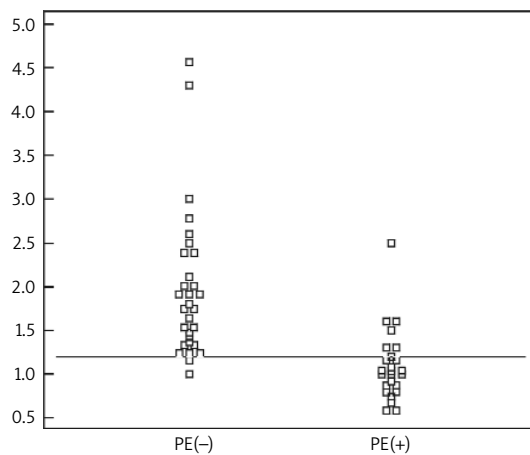


Figure 1. Individual values of the SmRV/SmLV parameter in patients with or without PE. The value of this parameter ≤ 1.2 identified patients with PE with a sensitivity of 76%, and a specificity of 93.3%

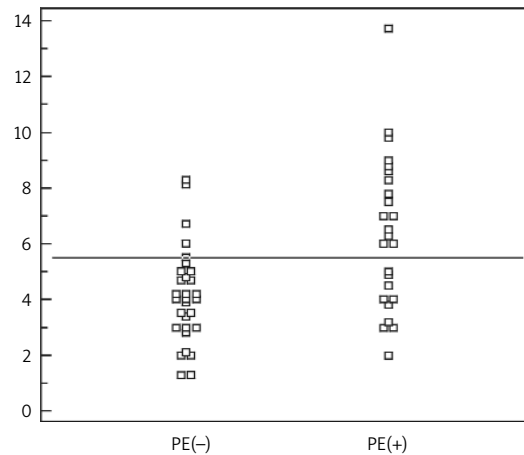


Figure 2. Individual values of the SmLV parameter in patients with or without PE. The value of this parameter > 5.5 cm/s identified patients with PE with a sensitivity of 60%, and a specificity of 86.7%

was ≤ 1.3 . For this value, sensitivity was 90.9% and specificity 80% in the group of patients with PE.

Discussion

Colour tissue Doppler imaging is a method that enables evaluation myocardial systolic and diastolic function. The role of this technique has been confirmed in several echocardiographic studies [9-15]. Most of them were based on examinations assessing regional myocardial systolic and diastolic performance. Additionally, measuring velocity by means of this method enables the recording of motion velocity in the selected myocardial area, and also in the annuli of the mitral or tricuspid valves. Kaul et al. [16] showed a close correlation between systolic excursion of the tricuspid annulus, measured with pulse wave tissue Doppler, and RV ejection fraction (RVEF) calculated by means of radionuclide angiography. Similarly, in the report of Ozdemir et al. [7] pulse tissue Doppler was applied and decreased tricuspid valve systolic motion velocity < 12 cm/s was considered an index of RV systolic dysfunction. Meluzin et al. [17] noted that decreased tricuspid valve systolic motion velocity < 11.5 cm/s characterised patients with impaired RVEF $< 45\%$ with a sensitivity of 90% and a specificity of 85%. Yu et al. [18] evaluated regional systolic as well as diastolic velocities for individual segments of LV myocardium by means of tissue colour Doppler imaging method. Peak systolic velocity was decreased significantly in all examined myocardial segments in patients with systolic CHF in comparison to healthy individuals and in 8 of 12 evaluated segments in patients with systolic CHF in comparison to healthy subjects. The LV systolic velocity in the group with systolic CHF was lower than in the group

with diastolic CHF. Patients with both forms of CHF presented decreased early diastolic velocity (Em) compared with healthy individuals.

In our report, the study group comprised patients with CHF accompanied by PE and the control one involved CHF patients without confirmed PE but with increased right ventricular systolic pressure (RVSP > 35 mmHg). Tricuspid annular systolic velocities evaluated with tissue colour Doppler imaging were similar (without significant differences) in both groups. Absolute values were comparable to the values of patients with CHF in the study of Witte et al. [8] (6.5 ± 2.5 cm/s). In our study, mean SmRV was 6.5 ± 2.6 cm/s and 7.0 ± 2.5 cm/s in group PE(+) and group PE(-), respectively. Patients with PE differed significantly with respect to mitral annular peak systolic velocity from the group of patients without PE. The SmLV value in the group without PE was comparable to the value reported in the study of Yu et al. [18]. In this report, systolic velocities were 3.3 ± 1.5 cm/s and 4.7 ± 1.7 cm/s, respectively, for patients with systolic and diastolic CHF. However, in patients with confirmed diagnosis of PE, mitral annular peak systolic velocity approximated to the systolic velocity value noted by Yu et al. [18] (7.1 ± 1.8 cm/s) in the healthy subjects examined as a control group.

Recently, two reports dealing with the use of colour tissue Doppler echocardiographic imaging technique in diagnosis of patients with PE have been published [19, 20]. In the study of Kjaergaard et al. [19], the authors evaluated systolic velocities of RV basal and medial free RV wall segments in 3 groups of patients. The first one comprised patients with PE confirmed in perfusion-ventilatory scintigraphy, the second one – patients with intermediate scintigraphic result, and the third one – healthy individuals. Peak systolic velocities of free RV wall motion in the

aforementioned segments did not differ significantly between patients with confirmed PE and healthy subjects.

In the report published by Hsiao et al. [20] investigators assessed patients with PHT detected in echocardiography and defined as RVSP >40 mmHg, applying pulse wave tissue Doppler imaging technique to diagnose PE. The study involved 150 patients presenting with signs of PHT. In all patients chest multi-slice computed tomography was carried out and diagnosis of PE was established in 50 patients. An additional 150 healthy individuals were enrolled in the study without either any cardio-pulmonary disease or any signs of PHT in echocardiography. Pulse tissue Doppler velocities were measured at the lateral portion of the tricuspid valve and basal segment of the ventricular septum (IVS) in the apical four-chamber view. In that study [20], patients with confirmed PE had significantly slower early systolic velocity of mitral inflow than both patients with PHT and healthy individuals, 56 ± 18 , 76 ± 25 and 84 ± 21 cm/s, respectively ($p < 0.0001$). In the lateral portion of the tricuspid annulus, both time periods of isovolumetric systole and isovolumetric diastole were prolonged significantly in patients with PE compared with the two other examined groups ($p < 0.0001$ and $p < 0.0001$, respectively). The Tei RV index in the group with diagnosed PE was also significantly higher ($p < 0.0001$) than in the other groups and its value of >0.55 detected PE with a sensitivity of 85% and a specificity of 78%. Similarly, Index-M, a ratio of early diastolic mitral inflow velocity to Tei RV index, was significantly lower in the group with PE compared to the groups either with PHT or the healthy subjects and was 88 ± 36 , 164 ± 51 , 190 ± 49 , respectively ($p < 0.0001$). The research also estimated Index-M value of <112 as enough to diagnose PE with a sensitivity of 92% and a specificity of 92%.

In our study we applied the TAPSE and Tei RV index to assess RV function. Patients with confirmed PE presented significantly lower TAPSE than those without PE. In the study of Kjaergaard et al. [19], in the group of patients with PE, TAPSE was also decreased to 1.9 cm. Another report published by Hsiao S-H et al. [20] indicated that TAPSE in the group of patients with PE was 1.6 ± 0.5 , in those with PHT 1.8 ± 0.6 and in a control group 2.2 ± 0.5 , respectively. The Tei RV index in our group was significantly higher in patients with PE compared to those without PE ($p=0.04$) and its value >0.62 distinguished patients with confirmed clinically PE from those without PE with a sensitivity of 54.5% and a specificity of 75.9%.

In the study presented by Hsiao et al. [20], attention should be paid to the velocities of the tricuspid annular lateral portion and IVS basal segment motion. Tricuspid annular velocities were lower in patients with PE and PHT compared to healthy individuals (11.5 ± 2.6 , 11 ± 3 , and 12.6 ± 2.9 cm/s, respectively) [20]. This phenomenon may be a result of myocardial damage and/or overload that leads to decrease in velocities of both valvular annuli and cardiac wall segments. Among examined patients no

significant differences in the tricuspid annular lateral portion velocity were noted between the groups of patients with PE and PHT. This confirms the findings in our examined patient population with CHF. Velocities within the basal IVS segment in the group with PHT did not differ significantly from the group of healthy subjects, 7.2 ± 2.4 and 7.5 ± 1.9 cm/s, respectively. Meanwhile, in the group with PE velocities increased and were 8.2 ± 2.0 cm/s ($p=0.047$) [20].

The increase in velocity of basal IVS segment excursion may be explained by an additional impact of systolic LV performance on IVS function that may have resulted from increased mitral annular systolic velocity during PE course observed in our study. Hsiao et al. [20] and Kjaergaard et al. [19] evaluated the lateral portion of tricuspid annular systolic velocities during PE course and found no significant differences in comparison to patients with PHT. Our patients with CHF and confirmed PE had significantly higher mitral annular lateral portion systolic velocity motion than patients without PE ($p=0.003$). In the study of Hsiao et al. [20], velocities measured in the basal IVS segment in patients with PE were significantly higher than in patients with PHT. Right and LV function had an impact on velocity measurements in the basal IVS segment. In the case of our assays, significantly higher systolic velocity determined in the mitral annular lateral portion additionally enhanced hyperkinetic LV function. Thus it seems that quantitative evaluation of LV performance plays an important role in PE detection. Decreased early diastolic mitral inflow assessed by means of spectral Doppler study, found by Hsiao et al. [20], justifies speculation that hyperkinetic LV performance results from diminished preload in PE course. Thus, we may hypothesise that in patients with PE hyperkinetic LV systole is present and leads to an increase in the lateral portion of mitral annular velocity motion (observed in our study) compared to patients with PHT in the course of CHF.

Conclusions

Systolic velocity of mitral annular lateral portion (SmLV) >5.5 cm/s and the ratio of systolic motion velocity of tricuspid annular lateral portion to systolic motion velocity of mitral annular lateral portion (SmRV/SmLV) ≤ 1.2 are sensitive and specific indices of segmental PE in patients with CHF.

References

1. Sutherland GR, Stewart MJ, Groundstroem WE, et al. Color Doppler myocardial imaging: a new technique for the assessment of myocardial function. *J Am Soc Echocardiogr* 1994; 7: 441.
2. Zhang SD, Zhang SL, Zhou HY, et al. Assessment of left ventricular systolic and diastolic function by Doppler tissue imaging in patients with chronic heart failure. *Zhong Nan Da Xue Xue Bao Yi Xue Ban* 2005; 30: 60-3.
3. Garcia EH, Perna ER, Farias EF, et al. Reduced systolic performance by tissue Doppler in patients with preserved and abnormal

- ejection fraction: new insights in chronic heart failure. *Int J Cardiol* 2006; 108: 181-8.
4. Nikitin NP, Loh PH, De Silva R, et al. The prognostic value of systolic mitral annular velocity measured with Doppler tissue imaging in patient with chronic failure due to left ventricular systolic dysfunction. *Heart* 2005, doi:10.1136: heart.bmj.com/cgi/content/abstract/hrt.2005.067140v1
 5. Jarnert C, Mejhert M, Ring M, et al. Doppler tissue imaging in congestive heart failure patients due to diastolic or systolic dysfunction: a comparison with Doppler echocardiography and the atrio-ventricular plane displacement technique. *Eur J Heart Fail* 2000; 2: 151-60.
 6. Tüller D, Steiner M, Wahl A, et al. Systolic right ventricular function assessment by pulsed wave tissue Doppler imaging of the tricuspid annulus. *Swiss Med Wkly* 2005;135: 461-8.
 7. Ozdemir K, Altunkeser BB, Içli A, et al. New parameters in identification of right ventricular myocardial infarction and proximal right coronary artery lesion. *Chest* 2003; 124: 219-26.
 8. Witte KK, Nikitin NP, de Silva R, et al. Exercise capacity and cardiac function assessed by tissue Doppler imaging in chronic heart failure. *Heart* 2004; 90: 1144-50.
 9. Oki T, Tabata T, Yamada H, et al. Clinical application of pulsed Doppler tissue imaging for assessing abnormal left ventricular relaxation. *Am J Cardiol* 1997; 79: 921-8.
 10. Derumeaux G, Ovize M, Loufoua J, et al. Doppler tissue imaging quantitates regional wall motion during myocardial ischemia and reperfusion. *Circulation* 1998; 97: 1970-7.
 11. Severino S, Caso P, Galderisi W, et al. Use of pulsed Doppler tissue imaging to assess regional left ventricular diastolic dysfunction in hypertrophic cardiomyopathy. *Am J Cardiol* 1998; 82: 1394-8.
 12. Garcia-Fernández MA, Azevedo J, Moreno M, et al. Regional diastolic function in ischaemic heart disease using pulsed wave Doppler tissue imaging. *Eur Heart J* 1999; 20: 496-505.
 13. Mishiro Y, Oki T, Yamada H, et al. valuation of left ventricular contraction abnormalities in patients with dilated cardiomyopathy with the use of pulsed tissue Doppler imaging. *J Am Soc Echocardiogr* 1999; 13: 913-20.
 14. Sohn DW, Song JM, Zo JH, et al. Mitral annulus velocity in the evaluation of left ventricular diastolic function in atrial fibrillation. *J Am Soc Echocardiogr* 1999; 12: 927-31.
 15. Meluzin J, Spinarova L, Dusek L, et al. Prognostic importance of the right ventricular function assessed by Doppler tissue imaging. *Eur J Echocardiog* 2003; 4: 262-71.
 16. Kaul S, Tei Ch, Hopkins JM, et al. Assessment of right ventricular function using two-dimensional echocardiography. *Am Heart J* 1984; 107: 526-31.
 17. Meluzin J, Spinarová L, Bakala J, et al. Pulsed Doppler tissue imaging of the velocity of tricuspid annular systolic motion; a new, rapid, and non-invasive method of evaluating right ventricular systolic function. *Eur Heart J* 2001; 22: 340-8.
 18. Yu CM, Lin H, Yang H, et al. Progression of systolic abnormalities in patients with 'isolated' diastolic heart failure and diastolic dysfunction. *Circulation* 2002; 105: 1195-201.
 19. Kjaergaard J, Schaadt BK, Lund J, et al. Quantitative measures of right ventricular dysfunction by echocardiography in the diagnosis of acute nonmassive pulmonary embolism. *J Am Soc Echocardiogr* 2006; 19: 1264-71.
 20. Hsiao SH, Chang SM, Lee CY, et al. Usefulness of tissue doppler parameters for identifying pulmonary embolism in patients with signs of pulmonary hypertension. *Am J Cardiol* 2006; 98: 685-90.

Znaczenie kolorowego dopлера tkankowego w rozpoznaniu segmentalnej zatorowości płucnej u chorych z przewlekłą niewydolnością serca

Leszek Gromadziński, Ryszard Targoński

Oddział Kardiologiczno-Internistyczny, Miejski Szpital Zespolony, Olsztyn

Streszczenie

Wstęp: Tkankowe badanie doplerowskie jest szybkim, przytóżkowym, nieinwazyjnym badaniem echokardiograficznym. Obrazowanie prędkości regionalnej w obrębie segmentów ścian mięśnia sercowego pozwala na jakościową i ilościową ocenę zaburzeń kurczliwości.

Cel: Ocena prędkości ruchu pierścienia mitralnego i trójdzielnego u chorych z przewlekłą niewydolnością serca (CHF) z towarzyszącą zatorowością płucną (PE).

Metodyka: Praca o charakterze prospektywnym, do której włączono 55 chorych z HF w III i IV klasie wg NYHA, przyjętych do szpitala z powodu nagłej duszności spoczynkowej, z podwyższonym ciśnieniem skurczowym w prawej komorze serca (RVSP >35 mmHg) i dodatnim wynikiem badania D-dimeru wykonanego metodą Elisa. U chorych wykonano standardowe badanie echokardiograficzne, badanie doplerowskie tkankowe znakowane kolorem oraz spiralną jednorzędową tomografię komputerową klatki piersiowej (CT). Zgodnie z wynikiem CT chorych podzielono na 2 grupy: grupę 1. – z potwierdzoną PE (25 chorych) i grupę 2. – bez PE (30 chorych). Obie badane grupy nie różniły się statystycznie między sobą pod względem wieku, płci, etiologii HF. W grupie 1. liczba chorych ze skurczową HF wynosiła 11/25 (44%), w grupie 2. – wynosiła 15/30 (50%), u pozostałych chorych występowała rozkurczowa postać HF. Grupa 1. obejmowała 12 mężczyzn i 13 kobiet, średnia wieku wynosiła 75±10 lat, w grupie 2 było 16 mężczyzn i 14 kobiet. Średnia wieku wynosiła 73±11 lat. Szczytowe prędkości ruchu części bocznej pierścienia mitralnego i trójdzielnego były mierzone w osi podłużnej w projekcji 4-jamowej.

Wyniki: Prędkość skurczowa części bocznej pierścienia trójdzielnego (SmPK) wynosiła 6,5±2,6 cm/s w grupie 1. i 7,0±2,5 cm/s w grupie 2. (p=NS). Prędkość skurczowa części bocznej pierścienia mitralnego (SmLV) wynosiła 6,4±3,0 cm/s w grupie 1. i 4,6±2,0 cm/s w grupie 2. (p=0,003). Optymalna wartość odcięcia określona w analizie ROC dla parametru SmLV wynosiła >5,5 cm/s. Przy tej wartości czułość w grupie 1. wynosiła 60%, a swoistość 86,7%. Stosunek prędkości skurczowej pierścienia trójdzielnego do mitralnego (SmRV/SmLV) wynosił 1,1±0,4 i 1,73±0,87, odpowiednio w grupie 1. i 2. (p=0,001). Optymalna wartość odcięcia dla tego wskaźnika określona w analizie ROC wynosiła ≤1,2. Wartość ta oddzielała chorych z potwierdzoną PE od chorych bez PE z czułością 76% i specyficznością 93,3%.

Wnioski: Prędkość skurczowa ruchu bocznej części pierścienia mitralnego >5.5 cm/s oraz stosunek SmRV/SmLV ≤1.2 są przydatnymi wskaźnikami PE u chorych z CHF.

Słowa kluczowe: tkankowe badanie doplerowskie znakowane kolorem, zatorowość płucna, przewlekła niewydolność serca

Kardiologia Pol 2007; 65: 1433–1439

Adres do korespondencji:

lek. med. Leszek Gromadziński, Oddział Kardiologiczno-Internistyczny, Miejski Szpital Zespolony, ul. Niepodległości 44, 10-045 Olsztyn, tel.: + 48 89 527 22 35. +48 89 532 62 86, faks: +48 89 527 22 35, e-mail: lgol@op.pl

Praca wpłynęła: 16.05.2007. Zaakceptowana do druku: 06.09.2007.