

A case of mitral stenosis with achalasia

Współistnienie stenozы mitralnej i achalazji przełyku – opis przypadku

Kumar Ashutosh¹, Majumdar Biswakes², G. Bhawani³, Ghoshdashtidar Dipankar², Aggrawal Binod², Mondal Saroj², Singh Rupesh², Sarkar Achyut²

¹ GSL Medical College, Rajahmundry, Andhra Pradesh, India

² Institute of Postgraduate Medical Education and Research, Kolkata, India

³ KPC Medical College, Kolkata, India

Abstract

A 65-year-old woman with rheumatic heart disease and severe mitral stenosis developed dysphagia. As her dysphagia could not be directly attributed to an enlarged left atrium, she underwent barium swallow, which established the diagnosis of achalasia. This case report shows two unrelated diseases present in the same patient which individually can cause dysphagia.

Key words: achalasia, mitral stenosis, dysphagia

Kardiologia Pol 2009; 67: 1374-1376

Introduction

Achalasia of the oesophagus is a motor disorder of oesophageal smooth muscle and involves thoracic and abdominal parts of the oesophagus. In achalasia, the oesophageal body loses peristaltic contraction and the lower oesophageal sphincter does not relax normally in response to swallowing. It is an important cause of dysphagia affecting all age groups and both genders. Dysphagia due to achalasia is distinctive in that it occurs early with both liquids and solids and is worsened by emotional stress and hurried eating.

Mitral stenosis usually presents with dyspnoea on exertion. Compression of the recurrent laryngeal nerve can lead to hoarseness of voice. Dysphagia in the case of mitral stenosis has been attributed to an enlarged atrium compressing the oesophagus but its actual mechanism is still a matter of debate.

We describe a case of mitral stenosis presenting with dysphagia in addition to other usual symptoms. The dysphagia was unique in that it was caused both by solid and liquid meals, which on evaluation was found to be due to achalasia. This is the first case report of two unrelated diseases present in the same patient which individually can cause dysphagia.

Case report

A 65-year-old female who was known to have rheumatic heart disease with mitral stenosis presented to us with increasing dysphagia with a sensation of food sticking to the mid-thorax for the past one month. The patient reported difficulty in swallowing both solid and liquid foods for the past one year. She had decreased her meal quantity and took a long time to finish her meal. She also vomited undigested food taken one day earlier. For two days from admission she had breathlessness at rest and was obtunded on the day of admission.

On examination she was malnourished and emaciated with foul smelling breath and with irregularly irregular pulse of rate 96 beat per minutes and BP of 100/70 mmHg. The patient was pale, with no clubbing, cyanosis or oedema. JVP was raised and pulsatile.

The ECG showed atrial fibrillation with ventricular rate of 98/min with right axis deviation and features of right ventricular hypertrophy.

Echocardiography revealed severe mitral stenosis with left atrial dilatation and a large left atrial thrombus of size 8/9 mm with tricuspid regurgitation.

As the patient's dysphagia was provoked by both solid and liquid meals, it could not be explained by left atrium

Address for correspondence:

Kumar Ashutosh MD, GSL Medical College, Lakshmiapuram Godavari Distt, Rajahmundry, East Godavari, Andhra Pradesh, India, PIN 533294, tel.: +883 2484999, e-mail: ashutoshvani@yahoo.co.in

Received: 21 March 2009. **Accepted:** 15 April 2009.

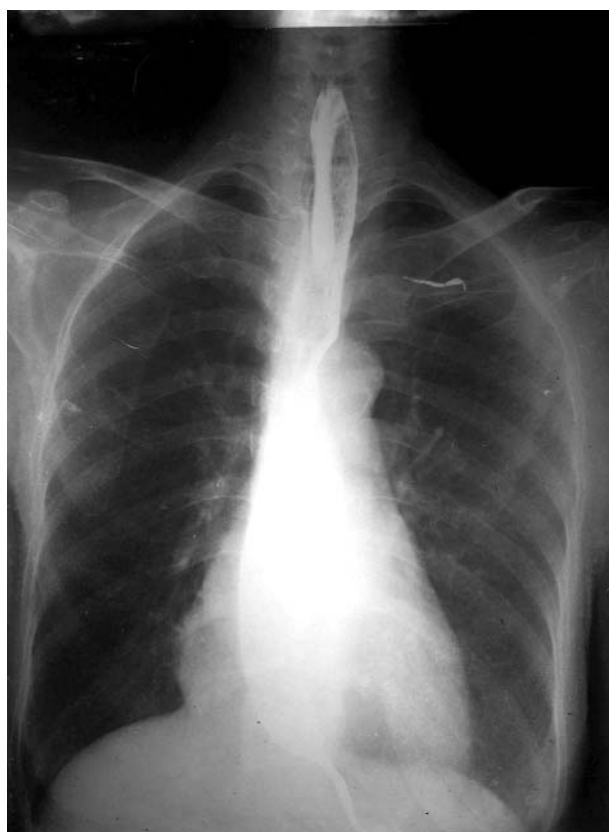


Figure 1. Chest radiogram with barium swallow showing dilated oesophagus with rat tail appearance of terminal oesophagus (PA view)

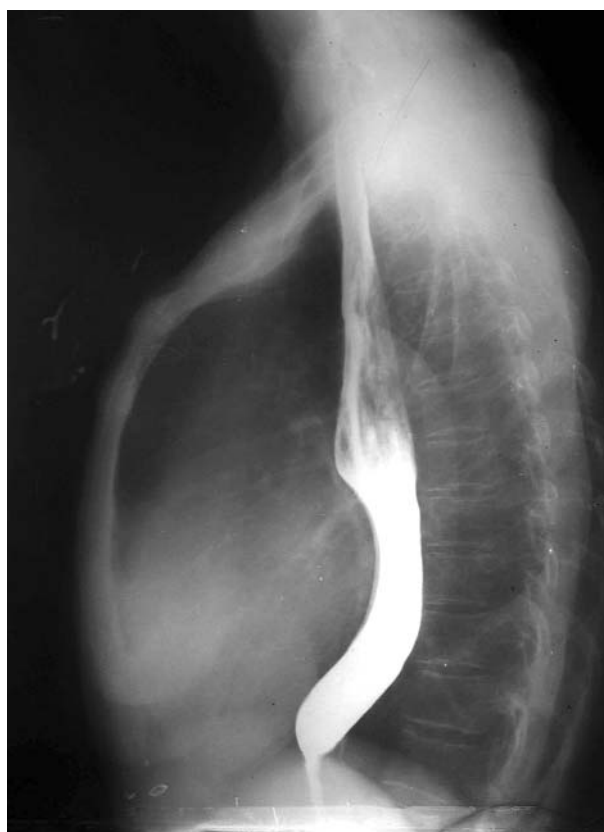

Figure 2. Chest radiogram with barium swallow showing dilated oesophagus with rat tail appearance of terminal oesophagus (lateral view)

enlargement. The patient underwent upper GI endoscopy which revealed a dilated distal segment of the oesophagus with no mass lesion and with abrupt narrowing of the distal segment.

The patient underwent barium swallow/meal examination which showed the left atrium compressing and displacing the mid-segment of the oesophagus (Figure 1), while the distal segment was dilated (enlarged or widened), with a characteristic tapered narrowing of the lower end, sometimes likened to a 'bird's beak' classically described in achalasia (Figure 2). On oesophageal manometry, no peristaltic waves were seen in the lower half of the oesophagus, and the pressure within the contracted lower oesophageal sphincter did not fall with the swallow.

This is the first case report of such an association of cardiac and oesophageal lesions which individually can cause dysphagia. In our patient dysphagia was primarily due to achalasia.

Discussion

Achalasia is an idiopathic primary oesophageal motor disorder characterised by insufficient relaxation of the lower oesophageal sphincter muscle and the absence of

oesophageal peristalsis. Decreased and/or diminished myenteric ganglia have been reported in the lower oesophagus [1, 2]. Achalasia is known as a risk factor of oesophageal carcinoma [3-5].

The diagnosis of achalasia is often suspected on the basis of the history. Patients usually describe a progressive worsening of dysphagia for solid and liquid food over a period of many months to years. They may report regurgitation of food, chest pain, or loss of weight. Rarely, the first symptom is aspiration pneumonia. Because patients typically learn to compensate for their dysphagia by taking smaller bites, chewing well, and eating slowly, the diagnosis of achalasia is often delayed by months or even years. The delay in diagnosis of achalasia is unfortunate because it is believed that early treatment before marked dilatation of the oesophagus occurs can prevent oesophageal dilation and its complications.

Dysphagia due to cardiac causes has been reported in only a small number of patients [6-9]. The mechanism of dysphagia in association with mitral disease is less certain. Normal swallowing is controlled and co-ordinated by autonomic nerve plexuses in the oesophagus. These plexuses derive their nerve supply from the vagus nerves and thoracic sympathetic outflow: fibres from the posterior

pulmonary plexuses from which four or five cords pass posteriorly to the middle of the oesophagus. The cords then divide into the oesophageal plexus which supplies afferent and efferent fibres. During normal peristaltic contraction, pressure within the oesophageal lumen reaches a peak value of 40 to 80 mmHg [10].

In severe mitral stenosis the enlarged left atrium displaces the oesophagus, usually backwards and to the right [8-9]. Pressure within the left atrium is increased and may interfere with normal oesophageal peristalsis, causing dysphagia. The maximum pressure applied to the oesophagus by the left atrium is not likely to exceed peak intra-oesophageal pressure during active peristalsis. However, autonomic nerve fibres stretched between the posterior pulmonary plexuses and the oesophagus may themselves be damaged, resulting in abnormal oesophageal peristalsis and an increased likelihood of dysphagia developing as a result of external compression from the enlarged and tense left atrium.

Our patient gave a history of dysphagia for the past one year, but she had a feeling of food sticking to the mid-thorax with vomiting in the evening hours on most days in the past one month. As the patient was elderly and dysphagia could not be directly attributed to an enlarged left atrium compressing the oesophagus she underwent barium swallow, endoscopy and oesophageal manometry, which established the diagnosis of achalasia.

References

1. Goldblum JR, Rice TW, Richter JE. Histopathologic features in esophagomyotomy specimens from patients with achalasia. *Gastroenterology* 1996; 111: 648-54.
2. Goldblum JR, Whyte RI, Orringer MB, et al. Achalasia. A morphologic study of 42 resected specimens. *Am J Surg Pathol* 1994; 18: 327-37.
3. Meijssen MAC, Tilanus HW, Blankenstein M, et al. Achalasia complicated by oesophageal squamous cell carcinoma: a prospective study in 195 patients. *Gut* 1992; 33: 155-8.
4. Sandler RS, Nyren O, Ekblom A, et al. The risk of esophageal cancer in patients with achalasia. *JAMA* 1995; 274: 1359-62.
5. Streitz JM Jr, Ellis FH Jr, Gibb SP, Heatley GM. Achalasia and squamous cell carcinoma of the esophagus: analysis of 241 patients. *Ann Thorac Surg* 1995; 59: 1604-9.
6. Bloomfield AL. Dysphagia with disorders of the heart and great vessels. *Am J Med Sci* 1940; 200: 289-99.
7. Dienes DE, Anderson MW. Giant left atrium as a cause of dysphagia. *Ann Intern Med* 1966; 65: 758-61.
8. Le Roux BT, William MA. Dysphagia megalatriensis. *Thorax* 1969; 24: 603-9.
9. Whitney B, Croxon R. Dysphagia caused by cardiac enlargement. *Clin Radiol* 1972; 23: 147-52.
10. Goyal RK. Diseases of esophagus. In: Wilson JD, Braunwald E, Isselbacher KJ, et al. (eds.). *Harrison's principles of internal medicine*. 17th ed. *McGraw-Hill* 2008; 1847-55.