

Ivabradine as a heart rate-lowering agent in a patient with end-stage renal failure after heart transplantation

Ivabradyna — lek zwalniający częstość rytmu serca u pacjentki z krańcową niewydolnością nerek po transplantacji serca

Małgorzata Kurpesa, Ewa Trzos, Karina Wierzbowska-Drabik, Tomasz Rechciński

2nd Chair and Department of Cardiology, Medical University of Łódź, Łódź, Poland

Abstract

A 56 year-old woman with a transplanted heart, with arterial hypertension and chronic pulmonary obstructive disease, was hospitalised because of palpitations, dyspnea, chest pain and oedema. After cyclosporine treatment she was diagnosed with renal failure, which was treated by hemodialysis. Heart rate (HR) at admission was 100, mean HR in 24-hour Holter monitoring was 106 bpm. Ivabradine was added to the treatment. The dose of 2.5 mg bid was doubled after three days. Mean HR in control Holter monitoring was 81. Ivabradine was well tolerated in this patient. The clinical benefits were observed soon after application and maintained during the follow-up.

Key words: heart transplantation, ivabradine, renal failure

Kardiol Pol 2010; 68, 6: 684–686

CASE REPORT

A 56 year-old woman with a history of cardiac transplantation (performed 15 years previously because of post-infarction heart failure) was admitted to the hospital due to palpitations, decreased exercise capacity, resting dyspnea, mild chest pain and ankle oedema. The symptoms had started one month prior to her admission. In 2002, after ten years of treatment with cyclosporine, she was diagnosed with renal failure, which had been treated by hemodialysis since 2007. The patient also had arterial hypertension and chronic obstructive pulmonary disease. She still smoked up to five cigarettes per day. In 2005, she underwent coronary angiography, which did not reveal significant stenoses. She had been taking over the previous 12 months metoprolol MR 50 mg/day, aspirin 75 mg/day, valsartan 160 mg/day, simvastatin 20 mg/day, amlodipine 10 mg/day and cyclosporine 100 mg bid.

At admission, the blood pressure was 130/80 mm Hg and heart rate (HR) 100 beats/min. Electrocardiogram sho-

wed regular sinus rhythm 110/min with right bundle branch block (RBBB) (present since the transplantation: Fig. 1A). In echocardiography, she had preserved left ventricular diastolic and systolic function with ejection fraction 64%, slightly enlarged left atrium 49 mm and a thickening of the left ventricle muscle 16/12 mm. In laboratory tests: BUN 70 mg/dL, creatinine 5.0 mg/dL, GFR 10 mL/min/1.73 m², serum K⁺ 5.01 mmol/l. Aminotransferases, bilirubin and albumine were normal. Cardiopulmonary exercise treadmill test revealed reduced exercise capacity: peak VO₂ 18.6 mL/min/kg, without induced ST-segment changes or chest pain. The test was terminated because of fatigue. Mean HR in 24-hour Holter monitoring was 106 bpm (max. HR 123 bpm, min. HR 92 bpm) with no significant ventricular or supraventricular arrhythmias (Fig. 2A).

Ivabradine was added to the treatment. The initial dose 2.5 mg bid was doubled after three days. In the control ECG, HR was reduced to 90 bpm. No symptoms of intolerance

Address for correspondence:

Małgorzata Kurpesa, MD, PhD, 2nd Chair and Department of Cardiology, Medical University of Łódź, Biegański Hospital, ul. Kniaziewiczza 1/5, 91–347 Łódź, Poland, tel: +48 42 653 99 09, fax: +48 42 251 60 15, e-mail: kurpesa@ptkardio.pl

Received: 09.11.2009 Accepted: 18.11.2009

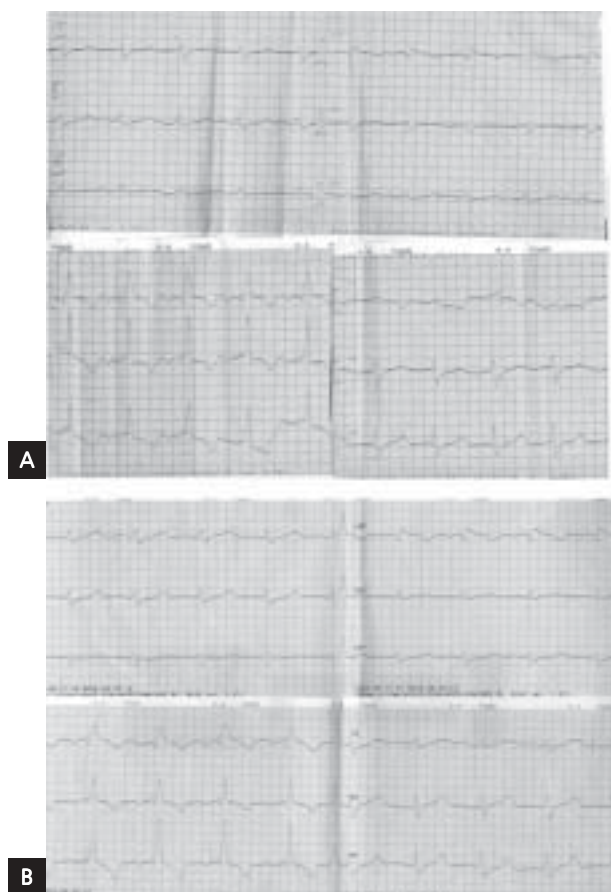


Figure 1. 12-lead electrocardiogram; **A.** Before starting the treatment with ivabradine; **B.** After three months of treatment with ivabradine (see the description in the article)

were observed. The patient was discharged on a dose of ivabradine 5 mg bid.

After three months, she reported improvement in all the symptoms which had been the reason for her hospitalisation. In ECG, regular sinus rhythm of 80 bpm with RBBB (Fig. 1B). Mean HR in 24-hour Holter monitoring was 81 bpm (max. HR 105 bpm, min. HR 71 bpm; Fig. 2B). The cardiopulmonary exercise test revealed improved exercise capacity, with peak VO_2 of 19.8 mL/min/kg.

DISCUSSION

The increased HR is associated with increased risk of cardiovascular mortality in patients with ischemic heart disease [1]. High resting HR in long-term survivors of cardiac transplantation is an adverse prognostic sign [2]. However, sinus tachycardia is a common problem in heart transplant recipients. The reason is the graft denervation, which decreases the efficacy of beta-blockers. On the other hand, calcium channel antagonists may negatively affect exercise capacity, whereas high doses of beta-blockers are often poorly tolerated, especially by patients with concomitant pulmonary diseases.

Ivabradine is a novel agent which inhibits spontaneous pacemaker activity of the sinus node by selectively and specifically inhibiting the I_f current. Ivabradine slows the HR without affecting myocardial contractility, relaxation or vascular resistance [3]. It can be safely used in patients with pulmonary contraindications for beta-blockers. Ivabradine has been studied in patients with coronary artery disease and has proven effective in preventing angina [4]. Recently, the BEAUTIFUL study has documented the safety and efficacy of ivabradine in patients with depressed left ventricular systolic function [5]. The data on using this agent after heart transplantation is limited.

We found two reports describing the effect of ivabradine as the only heart rate-lowering agent in heart transplant recipients [6, 7]. In our patient, ivabradine was added to a beta-blocker. We decided to continue the treatment with metoprolol 50 mg/day. A higher metoprolol dose would probably be more effective in reducing HR, but it might be dangerous for the patient because of the concomitant pulmonary disease. Complex treatment of ivabradine plus beta-blocker was well tolerated and effective. The HR was significantly lowered and this effect was observed during follow-up. The safety of the combined treatment with ivabradine and beta blocker was documented by the BEAUTIFUL study [5].

In our patient, the HR-lowering treatment was difficult because of concomitant end-stage renal failure. To our knowledge, this is the first report on using ivabradine in renal failure. It has been documented that continuous treatment with cyclosporine for more than 12 months causes progressive injury to renal microvessels that is rarely reversible and has the potential to advance to end-stage renal failure [8]. Cyclosporine-induced chronic nephropathy is diagnosed in 5–10% of heart transplant recipients [9]. The decision to start management with a new pharmacological agent is especially difficult in the presence of end-stage renal failure. Ivabradine undergoes extensive metabolism in the liver. Elimination of the metabolites is split between the faeces and urine (52% and 45% respectively). The manufacturer does not recommend a reduction of the ivabradine dose in patients with creatinine clearance > 15 mL/min. However, caution is advised in end-stage renal failure. There is no data related to the treatment with ivabradine in hemodialysed patients with chronic renal failure. Recently, Drouin et al. [10] demonstrated in an animal model that ivabradine prevented endothelial dysfunction in renal arteries by reducing oxidative stress. This study encouraged us to add ivabradine to the treatment. The medication was well tolerated and we did not observe a deterioration of renal parameters. Our patient reported significant symptomatic benefits and exercise capacity in spirometry was improved.

CONCLUSIONS

Ivabradine was safe and well tolerated in a patient after heart transplantation with end-stage renal failure. The clinical be-



Figure 2. Heart rate trend from 24-hour Holter monitoring (vertical axis: beats/minute; horizontal axis: hours of ECG monitoring); **A.** Before starting the treatment with ivabradine; **B.** After three months of treatment with ivabradine

nefits were observed soon after the application of ivabradine, and its effectiveness was maintained during the long-term follow-up.

References

1. Diaz A, Bourassa MG, Guertin MC et al. Long-term prognostic value of resting heart rate in patients with suspected or proven coronary artery disease. *Eur Heart J*, 2005; 26: 967–974.
2. Scott CD, McComb JM, Dark JH. Heart rate and late mortality in cardiac transplant recipients. *Eur Heart J*, 1993; 14: 530–533.
3. Berdeaux A. Preclinical results with If current inhibition by ivabradine. *Drugs*, 2007; 67 (suppl. 2): 25–33.
4. Tardif JC. Clinical results of I(f) current inhibition by ivabradine. *Drugs*, 2007; 67 (suppl. 2): 35–41.
5. Fox K, Ford I, Steq PG et al. BEAUTIFUL Investigators. Ivabradine for patients with stable coronary artery disease and left ventricular systolic dysfunction (BEAUTIFUL): a randomized, double-blind, placebo-controlled trial. *Lancet*, 2008; 372: 807–816.
6. Doesch AO, Celic S, Ehlermann P et al. Heart rate reduction after heart transplantation with beta-blocker versus the selective If channel antagonist ivabradine. *Transplantation*, 2007; 84: 988–996.
7. Zhang R, Haverich A, Strüber M et al. Effects of ivabradine on allograft function and exercise performance in heart transplant recipients with permanent sinus tachycardia. *Clin Res Cardiol*, 2008; 97: 811–819.
8. Myers BD, Newton L. Cyclosporine-induced chronic nephropathy: an obliterative microvascular renal injury. *J Am Soc Nephrol*, 1991; 2: S45–S52.
9. Frimat L, Villemot JP, Cormier L et al. Treatment of end-stage renal failure after heart transplantation. *Nephrol Dial Transplant*, 1998; 13: 2905–2908.
10. Drouin A, Gendron ME, Thorin E et al. Chronic heart rate reduction by ivabradine prevents endothelial dysfunction in dyslipidemic mice. *Br J Pharmacol*, 2008; 154: 749–757.