

# Autologous skeletal myoblast transplantation in non-ischaemic cardiomyopathy — a case report

Autologiczny przeszczep mioblastów szkieletowych  
w kardiomiopatii nie-niedokrwiennej — opis przypadku

Adam Sokal<sup>1</sup>, Roman Przybylski<sup>2</sup>, Marian Zembala<sup>2</sup>, Natalia Rozwadowska<sup>3</sup>, Małgorzata Bialas<sup>3</sup>,  
Radosław Lenarczyk<sup>1</sup>, Tomasz Niklewski<sup>2</sup>, Karol Miszański-Jamka<sup>2</sup>, Beata Średniawa<sup>1</sup>, Maciej Kurpisz<sup>3</sup>

<sup>1</sup>Department of Cardiology, Congenital Heart Disease and Electrotherapy, Medical University of Silesia, Silesian Centre of Heart Diseases, Zabrze

<sup>2</sup>Department of Cardiac Surgery and Transplantology, Medical University of Silesia, Silesian Centre of Heart Diseases, Zabrze, Poland

<sup>3</sup>Institute of Human Genetics, Polish Academy of Sciences, Poznan, Poland

## INTRODUCTION

Skeletal myoblast transplantation has been considered a promising therapy for the treatment of heart failure [1]. However, large multicenter trial (MAGIC) did not confirm these results [2]. The only documented effect was a decrease in the left ventricular (LV) end-diastolic volume and LV end-systolic volume. The disappointing outcome of this trial may be explained by a lack of sufficient vascularisation of myoblasts implanted to the areas supplied by infarct-related arteries unsuitable for direct revascularisation, which resulted in poor engraftment and viability of transplanted cells [2]. Additionally, all published reports on skeletal myoblast administration have highlighted the arrhythmogenic potential of these cells, something that is possibly due to the absence of connexin 43, the gap junction protein responsible for the electromechanical integrity of cardiac muscle [3]. In most of the studies, life-threatening ventricular arrhythmias occurred in the early post-transplant period (< 30 days) rather than during later follow-up [1].

Myoblasts can grow and differentiate only in areas with well developed vascular and microvascular bed that provides a sufficient supply of oxygen and nutrition. Such an environment is difficult to obtain in areas damaged by ischaemia. In non-ischaemic cardiomyopathy a loss of contractile element is diffused with entirely intact vascular bed. Recently published animal studies support such a hypothesis [4, 5]. In the present paper, we report the first case of a patient with non-

ischaemic cardiomyopathy in whom autologous skeletal myoblasts were delivered during surgical mitral valvuloplasty.

## METHODS

**Case description.** Patient (M.A.) was a 45 year-old male who had been referred to our department due to severe mitral valve regurgitation as a candidate for mitral anuloplasty. Patient suffered from dilated cardiomyopathy of unknown origin and progressive heart failure for 5 years before present hospitalisation. Despite optimal medical therapy (beta-blocker, ACEI in maximal tolerated doses, spironolactone and diuretics) a continuous decrease of exercise capacity with accompanying LV enlargement, increase of mitral regurgitation, and decrease of LV ejection fraction were observed during this time. Six months prior to hospitalisation a chronic atrial fibrillation led to extensive worsening of symptoms. Coronary angiography revealed no atherosclerotic lesions in coronary arteries. Magnetic resonance imaging excluded an active inflammatory process in the myocardium. Echocardiography showed severe type I and IIIB mitral regurgitation requiring surgical intervention. Baseline characteristics of the patient are summarised in Table 1. Due to the poor LV contractility autologous myoblast implantation during planned surgical procedure was additionally offered to the patient.

**Myoblast preparation.** After obtaining written consent and approval by the local Bioethical Committee, approximately 1 cm<sup>3</sup> of tissue was surgically collected from the *vasus*

---

### Address for correspondence:

Maciej Kurpisz, MD, Institute of Human Genetics, ul. Strzeszyńska 32, 60–479 Poznań, Poland, tel: +48 61 657 92 02, fax: +48 61 823 32 35, e-mail: kurpimac@man.poznan.pl

**Table 1.** Clinical characteristics of patient at baseline and at 12-month follow-up

Parameter	Baseline	12-month follow-up
NYHA class	III	I
EF (echocardiography)	26%	40%
EF (MRI)	15%	Not done (ICD)
Maximal VO <sub>2</sub> consumption	18.5 mL/min/kg	27.7 mL/min/kg
NT-proBNP	5337 pg/mL	198 pg/mL
Average diurnal heart rate	88/min	72/min
Mitral regurgitation	Severe	None

NYHA — New York Heart Association; EF — ejection fraction; ICD — implantable cardioverter-defibrillator; MRI — magnetic resonance imaging; NT-proBNP — N-terminal pro B-type natriuretic peptide

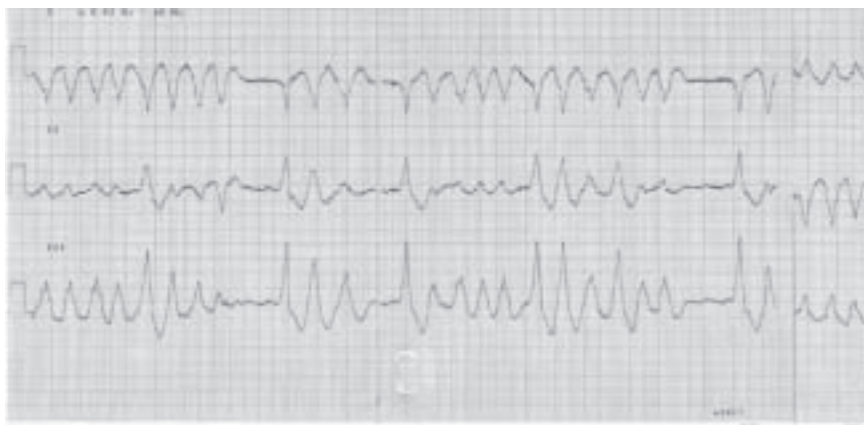*lateralis* under local anaesthesia for myoblasts isolation and *in vitro* culture [6].

## RESULTS

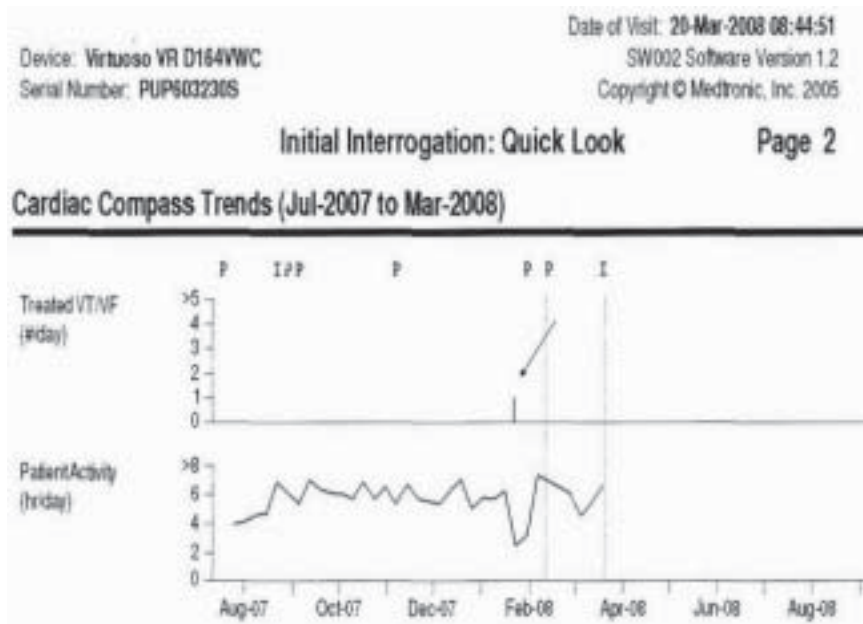After the end of mitral valvuloplasty (undersized-26 physio ring suturing) before cardio-pulmonary by-pass was discontinued, 10 injections of 0.3 mL myoblast cell suspensions were performed into the anterior, lateral and posterior walls of the LV. Propidium iodide and annexin V flow cytometry confirmed that > 95% of injected cells were viable without signs of apoptosis/necrosis. The surgical procedure was accomplished without any complications. Over the first three days following surgery, 900 mg/24 h of intravenous amiodarone was administered, followed by 400 mg/day oral amiodarone. No ventricular rhythm disorders were observed in the early postoperative period. Ten days after myoblast injection, an electrical storm with recurrent polymorphic ventricular tachycardia (VT) requiring repeated

cardioversions occurred despite antiarrhythmic therapy (Fig. 1). Ventricular tachycardia was finally suppressed with intravenous infusion of lidocaine (500 mg/day) which was continued for 7 days. Six days after lidocaine withdrawal, and 23 days after surgery, polymorphic VT reappeared. Replacing oral amiodarone with mexiletine (1,200 mg/day) resulted in sustained suppression of the ventricular rhythm disorders. The patient received an implantable cardioverter-defibrillator (ICD; Medtronic Virtuoso VR) and was discharged from the hospital having sinus rhythm at 34 days after surgery. Over a 12-month follow-up, a gradual improvement was observed, including symptomatic relief (from NYHA class III to NYHA class I), a substantial increase of LV ejection fraction and maximal exercise oxygen consumption, with a decrease of N-terminal pro B-type natriuretic peptide (NT-proBNP) serum concentration (Table 1). The patient had mainly sinus rhythm, however, episodes of typical atrial flutter occurred 2 months after discharge and were successfully treated by right atrial cavo-tricuspid isthmus ablation. Eight months after the administration of myoblasts, the patient decided to stop taking mexiletine. This resulted in an almost immediate recurrence of VT requiring multiple ICD interventions (Fig. 2). Mexiletine was reintroduced in a previous dose and prevented further ventricular arrhythmia.

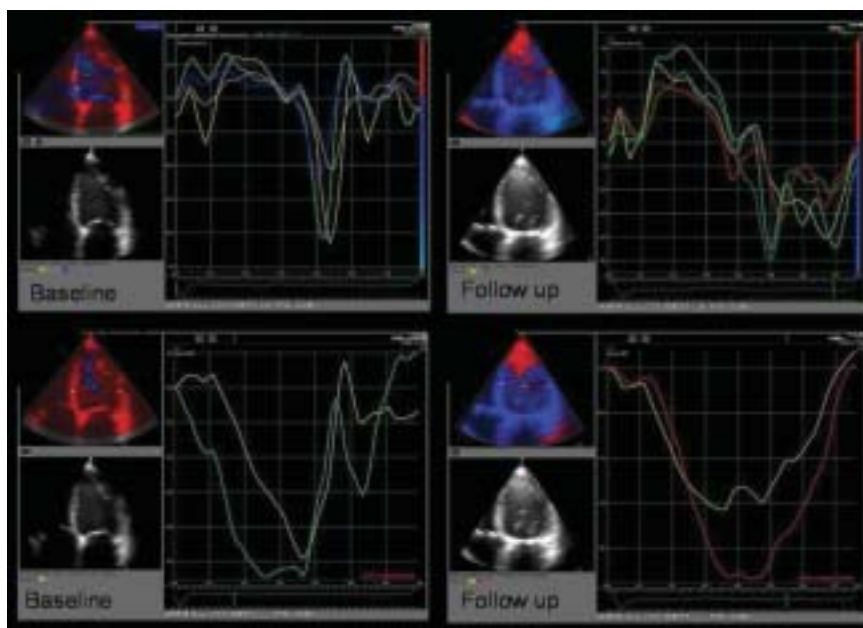
Using an ultrasound strain we observed a very good recovery of myocardial function 12 months after the procedure. Echocardiographic quantitative tissue Doppler analysis showed the essential improvement of longitudinal strain from about 10% up to 17–24%; this is within normal limits for healthy subjects and maximal deformation from post systolic strain to ejection time. Significant improvement of regional myocardial velocity from maximal 2.4 m/s to more than 4 m/s, especially in the lateral wall, and a clear increase of global LV diastolic function was revealed (Fig. 3).



**Figure 1.** Polymorphic ventricular tachycardia occurring ten days after myoblasts injection [RR 180/60 mm Hg; 25 mm/s; 10 mm/mV]



**Figure 2.** Records from an ICD memory during follow-up. Arrow shows an episode of recurrent ventricular tachycardia after mexiletine had been discontinued



**Figure 3.** Left ventricular regional function measured by tissue Doppler imaging

### COMMENT

We have here set out the first case of successful autologous skeletal myoblast implantation during mitral valve surgery. The ineffectiveness of myoblast administration into post-infarction scars in the MAGIC trial can be partly explained by the inability of these cells to promote local (scar) area vascularisation [2]. This seems to be less important in cases of non-ischæmic cardiomyo-

pathy with a well preserved vascular bed. In our case, two important findings support the hypothesis that the delivery of autologous skeletal myoblasts into a non-ischæmic myocardium would result in better engraftment and viability of transplanted cells; first, the observed a sustained substantial increase of LV contractility, and second — the occurrence of ventricular arrhythmia in early but also in a late phase after myoblasts injection.

Restrictive mitral annuloplasty is a common surgical procedure which significantly improves outcomes and relieves symptoms for patients with congestive heart failure and severe mitral valve regurgitation. Our observations (and previously published data) do not suggest that this procedure could also substantially improve heart contractility [7]. Such general experience may not exclude that in isolated cases such an effect may occur. We were able to effectively suppress the developing arrhythmia with mexiletine. Mexiletine is a sodium channel antagonist which, despite its action as a class Ib antiarrhythmic drug, is also used to relax hyperexcitability in myotonic syndromes such as hereditary disorders of skeletal muscle [8]. The case we present does not prove unequivocally the hypothesis that skeletal myoblast transplantation may soon become the standard therapy for non-ischaemic cardiomyopathy. However, it may serve to stimulate further trials with muscle-derived stem cells in specific cases of cardiomyopathy.

### Acknowledgements

The authors wish to acknowledge financial support from the Ministry of Science and Higher Education (No.N40306531/3011, No.NR13006506).

### References

1. Seidel M, Borczyńska A, Rozwadowska N, Kurpisz M. Cell-based therapy for heart failure: skeletal myoblasts. *Cell Transplant*, 2009; 18: 695–707.
2. Menasché P, Alfieri O, Janssens S et al. The Myoblast Autologous Grafting in Ischemic Cardiomyopathy (MAGIC) trial: first randomized placebo-controlled study of myoblast transplantation. *Circulation*, 2008; 117: 1189–2000.
3. Abraham MR, Henrikson CA, Tung L et al. Antiarrhythmic engineering of skeletal myoblasts for cardiac transplantation. *Circ Res*, 2005; 97: 159–167.
4. Ohno N, Fedak PW, Weisel RD, Mickle DA, Fujii T, Li RK. Transplantation of cryopreserved muscle cells in dilated cardiomyopathy: effects on left ventricular geometry and function. *J Thorac Cardiovasc Surg*, 2003; 126: 1537–1548.
5. Pouly J, Hagège AA, Vilquin JT et al. Does the functional efficacy of skeletal myoblast transplantation extend to nonischemic cardiomyopathy? *Circulation*, 2004; 110: 1626–1631.
6. Rozwadowska N, Fiszer D, Siminiak T, Kalawski R, Kurpisz M. Evaluation of *in vitro* culture of human myoblasts for tissue autotransplants to the post-infarcted heart. *Kardiologia Pol*, 2002; 57: 233–237.
7. Ngaage DL, Schaff HV. Mitral valve surgery in non-ischaemic cardiomyopathy. *J Cardiovasc Surg (Torino)*, 2004; 45: 477–481.
8. Cannon SC. Sodium channel defects in myotonia and periodic paralysis. *Annu Rev Neurosci*, 2006; 19: 141–164.