

Long-lasting durability of Carpentier-Edwards pericardial bovine bioprosthesis in mitral position — a case report of unfavourable post redo valve surgery course

Wieloletnia trwałość bioprotezy osierdziowej Carpentier-Edwards w pozycji mitralnej — opis niekorzystnego przebiegu pooperacyjnego po kolejnej wymianie zastawki

Katarzyna Łuczak¹, Katarzyna Piestrzeniewicz¹, Marek Maciejewski¹, Andrzej Walczak², Ryszard Jaszewski², Stanisław Ostrowski², Jarosław Drożdż¹

¹1st Department of Cardiology, Medical University of Łódź, Poland

²Department of Cardiac Surgery, Medical University of Łódź, Poland

Abstract

We describe a 73 year-old patient with mitral valve pericardial bioprosthesis Carpentier-Edwards 29M implanted due to the rheumatic mitral stenosis 21 years ago. Hemodynamic destabilisation had emerged 18 months before the admission. Echocardiography revealed significant bioprosthesis degeneration with calcification of its leaflets, small pannus on the bioprosthetic ring, moderate mitral stenosis, severe mitral and tricuspid regurgitation with high pulmonary hypertension and moderate aortic regurgitation. Redo valve surgery with mechanical Medtronic 27M valve implantation and tricuspid suture annuloplasty was successfully performed. The postoperative course was complicated by bleeding and severe respiratory insufficiency and the patient died 3 weeks after the surgery.

Key words: bioprosthesis, rheumatic heart disease, elderly, redo valve surgery

Kardiol Pol 2010; 68, 7: 806–808

INTRODUCTION

In patients with valvular heart disease referred for surgery, valve replacement with bioprosthesis is an alternative to mechanical prosthesis in selected patients. Unavailability of anti-coagulation is the major advantage of bioprosthesis, considered mostly when anti-coagulation is contra-indicated, in women contemplating pregnancy, in the non-compliant patients and in certain life-styles or occupations. Patient's young age at the time of implantation is the main risk factor of its structural degeneration implying the need for future redo valve surgery. Moreover, previous heart

operation or left ventricular dysfunction constitute the high risk of redo valve surgery. Therefore, the decision of bioprosthesis implantation before 65 years of age should be considered only when anti-coagulation is contra-indicated or not accepted. Although the number of cardiac surgical interventions in geriatric patients is increasing, elderly are postoperatively susceptible to complications and need more intensive care. The optimization of the patient's organ functions are decisive for the prognosis [1]. Beyond 20 years durability of bioprosthesis in mitral position is an exceptionally rare occurrence.

Address for correspondence:

dr n. med. Katarzyna Piestrzeniewicz, Department of Cardiac Surgery, 1st Chair of Cardiology and Cardiac Surgery, Medical University, ul. Sterlinga 1/3, 91–425 Łódź, Poland, tel/fax: +48 42 636 44 71, e-mail: katarzyna.piestrzeniewicz@umed.lodz.pl, kpiestrzeniewicz@tlen.pl

Received: 27.10.2009 Accepted: 02.11.2009

CASE REPORT

We describe a 73 year-old female patient with mitral valve bioprosthesis Carpentier-Edwards 29M implanted 21 years ago because of the rheumatic mitral stenosis. She was referred to our institution with increasing symptoms of heart failure and signs of the degeneration of bioprosthesis. At the time of implantation sinus rhythm was shown on ECG and on echocardiography typical features of rheumatic mitral valve disease with moderate enlargement of left atrium (46 mm). The patient had a history of paroxysmal atrial fibrillation (AF), hypertension, diabetes and dyslipidaemia. The decision of mitral valve replacement with bioprosthesis was made. The patient developed AF 5 months later. After the initial success to restore sinus rhythm, rate control strategy has been finally undertaken and oral anticoagulation was recommended. The clinical course was uneventful for the following 19 years. The control echocardiographic study performed four years before the present admission, showed mild degeneration of bioprosthesis with mitral valve area 2.1 cm², second degree mitral regurgitation and third degree functional tricuspid regurgitation.

Haemodynamic destabilisation had emerged a few months before and the significant progression of the degeneration of the bioprosthesis was revealed. On admission the patient presented with NYHA functional class III. Physical examination revealed symptoms of right heart failure — jugular venous distension, oedema of the ankles and hepatic enlargement. Systolic murmur was present at the apex and at the 5th intercostal space on the right sternal border. Laboratory tests revealed proper lipid profile and glucose metabolism. The thyroid dysfunction, infections and anaemia were excluded. Chest X-ray demonstrated spherical heart shape with both atria enlargement and pulmonary congestion and an increase of the cardio-thoracic ratio (0.7). Electrocardiogram showed AF, and nonspecific ST-T segment changes in leads V4–V6. Transthoracic and transeophageal echocardiography confirmed the significant bioprosthesis leaflets calcific degeneration (Fig. 1), small pannus on the atrial surface of the bioprosthetic ring, mitral valve area 1.8 cm², third degree mitral regurgitation, fourth degree tricuspid regurgitation and elevated systolic pulmonary arterial pressure (SPAP = 62 mm Hg), significant enlargement of both atria and preserved left and right ventricular systolic function (left ventricular ejection fraction: 63%, tricuspid annular motion: 20 mm). The leaflets of the aortic valve were thickened and second degree aortic regurgitation was detected.

The redo valve surgery with mechanical Medtronic 27M valve implantation and tricuspid suture annuloplasty with Revuelta method were successfully performed. The echocardiographic findings regarding degeneration of the bioprosthesis were confirmed (Fig. 2). The early postoperative course was complicated by bleeding requiring reoperation and blood transfusion and respiratory disorders requiring respiration. On

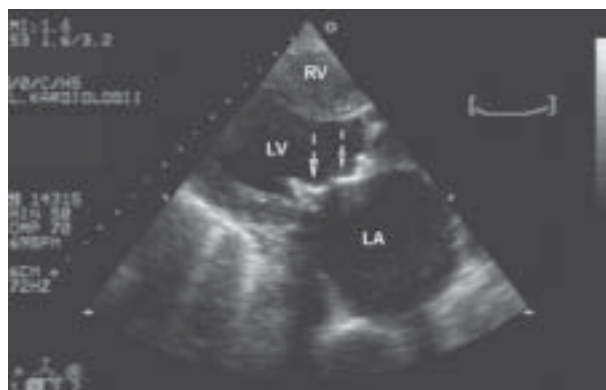


Figure 1. B-mode, modified, parasternal long axis view. Significant degeneration of the mitral bioprosthesis (calcified leaflets — arrows) and enlarged left atrium (LA); LV — left ventricle; RV — right ventricle

echocardiography the function of the prosthetic valve was correct and the left ventricular function was slightly depressed. Despite the intensive pharmacological treatment patient died three weeks after the operation.

DISCUSSION

Although the bioprosthesis implantation is recommended in patients aged over 65 years of age it may be an option in younger patients in certain situations. In the study of Yu et al. [2] in the total group of 872 patients with Carpentier-Edwards porcine bioprosthesis, those with implantation in mitral position were aged 40 ± 13 years. Mean duration to valve failure was 12.2 ± 0.4 years and actuarial patient survival rates after surgery at 5, 10, 15 and 20 years were 92.5%, 83.8%, 72.3% and 35.8%, respectively. Most other cases presented in the literature show a proper function of bioprosthesis in mitral position for about 15–17 years. To our knowledge only a few patients with bioprosthesis lasting for longer than 20 years were described [3]. Various malformations are being found on the porcine pericardial Carpentier-Edwards bioprostheses late after implantation — leaflet perforation, dehiscence at the stent posts, commissural tear, pannus overgrowth, impaired leaflet mobility and diffuse calcification [4] which result in stenosis and/or regurgitation. Risk factors of atherosclerosis might play a substantial role in the degeneration of bioprosthetic valves so that lipid levels control, smoking cessation, therapy for diabetes and hypertension are strongly recommended [5].

Limited durability of bioprostheses results in an unsatisfactory rate of reoperation. Although previous heart operation is recognised as a negative predictor of outcome Potter et al. [6] showed in their study that the risk of operative mortality was not significantly different between the group of patients undergoing repeat vs. primary mitral valve replacement (4.7% vs 4.1%, respectively). The best results are achieved with elective valve replacement, without concurrent cardiac

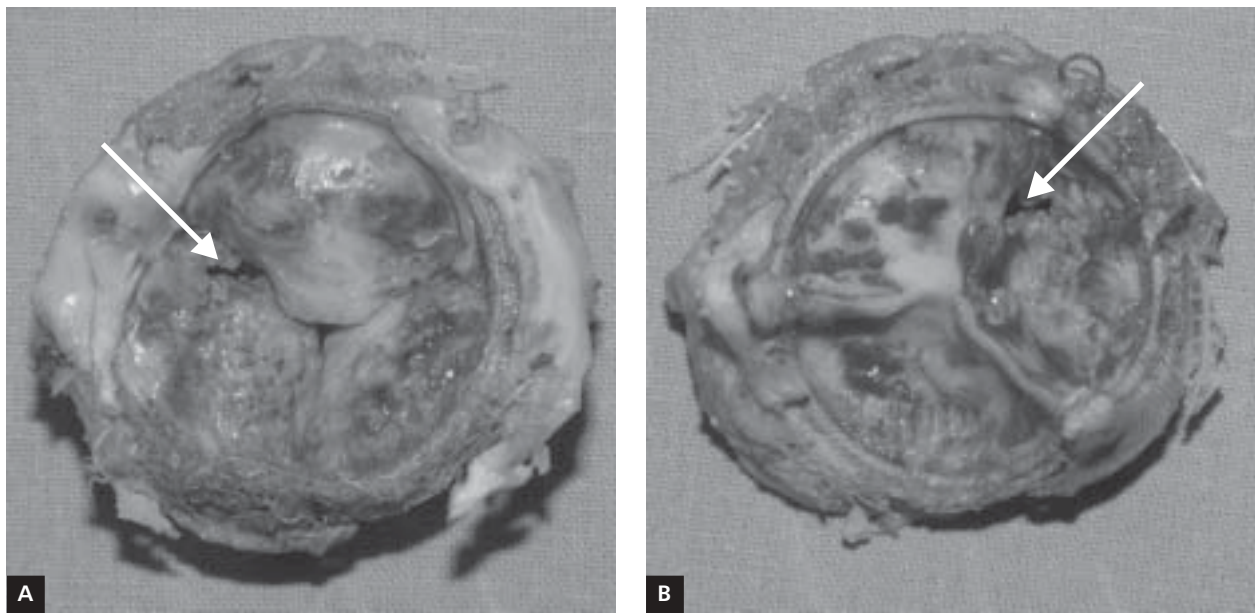


Figure 2. Photos of the atrial (A) and ventricular (B) sides of the excised bioprosthesis. Severe degeneration and extensive calcification of the leaflets with the small loss of the leaflet tissue (arrows) — the cause of the mitral regurgitation

procedures [7]. There were two independent predictors of poor outcome in our patient — the age over 65 years [7] and the bleeding requiring reoperation [8], so despite the proper intensive care the patient died three weeks after the operation. The presented case supports the conviction that bioprosthesis is not the optimal choice for the relatively young patient.

The presented case confirms the rule that bioprosthesis is not an optimal choice for relatively young patients.

References

1. Albert A, Ujvari Z, Mauser M, Ennker J. Cardiac surgery in the elderly: perioperative care and operative strategies. *Dtsch Med Wochenschr*, 2008; 133: 2393–2402.
2. Yu HY, Ho YL, Chu SH, Chen YS, Wang SS, Lin FY. Long-term evaluation of Carpentier-Edwards porcine bioprosthesis for rheumatic heart disease. *J Thorac Cardiovasc Surg*, 2003; 126: 535–540.
3. Baba T, Morishita K, Sato H, Yamauchi A, Obama T, Abe T. Extended survival of a porcine mitral bioprosthesis for 23 years: report of a case. *Surg Today*, 1999; 29: 573–574.
4. Naqvi TZ, Siegel RJ, Buchbinder NA et al. Echocardiographic and pathologic features of explanted Hancock and Carpentier-Edwards bioprosthesis valves in the mitral position. *Am J Cardiol*, 1999; 84: 1422–1427.
5. Nollert G, Miksch J, Kreuzer E, Reichart B. Risk factors for atherosclerosis and the degeneration of pericardial valves after aortic valve replacement. *J Thorac Cardiovasc Surg*, 2003; 126: 965–968.
6. Potter DD, Sundt TM 3rd, Zehr KJ, Dearani JA et al. Risk of repeat mitral valve replacement for failed mitral valve prostheses. *Ann Thorac Surg*, 2004; 78: 67–72.
7. Akins CW, Buckley MJ, Daggett WM et al. Risk of reoperative valve replacement for failed mitral and aortic bioprostheses. *Ann Thorac Surg*, 1998; 65: 1545–1551.
8. Toumpoulis IK, Chamogeorgakis TP, Angouras DC, Swistel DG, Anagnostopoulos CE, Rokkas CK. Independent predictors for early and long-term mortality after heart valve surgery. *J Heart Valve Dis*, 2008; 17: 548–556.