

Late right pulmonary artery stenosis after arterial switch operation in mirror image dextrocardia and situs inversus totalis

Późne zwężenie tętnicy płucnej po korekcji anatomicznej przełożenia wielkich pni tętniczych u noworodka z przełożeniem trzewi

Krzysztof Mozol, Piotr Burczyński, Ireneusz Haponiuk

The Children's Memorial Health Institute, Cardiac Surgery, Warsaw, Poland

Abstract

The operation of D-transposition of the great arteries is performed extremely rarely in patients with mirror image dextrocardia and situs inversus totalis. Therefore, it is not surprising that such unusual anatomy case presents problems with primary operation. We present a case of late right pulmonary artery stenosis after neonatal surgical anatomic correction of mirror image dextrocardia and situs inversus totalis.

Key words: arterial switch operation, mirror image dextrocardia

Kardiol Pol 2011; 69, 10: 1066–1068

INTRODUCTION

D-transposition of the great arteries (D-TGA) requires surgical correction in the neonatal period. Modern surgical management of D-TGA, without left ventricular outflow tract obstruction, is based on an arterial switch operation (ASO), first described in 1975. Nevertheless, operations of this type are performed extremely rarely in patients with mirror image dextrocardia and situs inversus totalis [1–3]. The first case with such unique anatomy of the heart was described by McMahon et al. in 2000 [1]. This atypical anatomy frequently causes difficulties during heart surgery [1, 2]. Furthermore, the location of pulmonary artery (PA) branches close behind the arterial duct increases the risk of iatrogenic injury of the right PA. We present a case of late right PA stenosis after neonatal surgical anatomical correction of mirror image dextrocardia and situs inversus totalis.

CASE REPORT

A baby boy, 3.6 kg, neonate with the diagnosis of D-TGA and mirror image dextrocardia, was referred for ASO. Extra-

corporeal circulation was commenced and the procedure was done using the Lecompt manoeuvre. The right PA was incidentally injured during separation of the ductus arteriosus. Reconstruction of the right PA was done using a fresh autologous pericardial patch. The post-surgery measurements were normal, and the child was transferred to the Intensive Care Unit under mechanical ventilation and standard catecholamine support (dopamine 5 µg/kg/min, milrinone 0.6 µg/kg/min). The anticoagulation prophylaxis was provided firstly by heparin infusion and further by low-molecular heparin supply. The general condition systematically improved.

The child was extubated within 110 hours. Postoperative chest X-ray shown symmetrical blood perfusion of the lungs. Echocardiography done routinely on the second, fifth and tenth postoperative days demonstrated good surgical results with normal bloodflow in both PAs. The boy was transferred to the Cardiac Surgery Ward and then to the Cardiac Ward. Dyspnoea systematically increased. Chest radiography showed growing abnormality in the pulmonary bloodflow. Right ventricle (RV)-right PA pressure gradient was seen on echo-

Address for correspondence:

Krzysztof Mozol, MD, The Children's Memorial Health Institute, ul. Dzieci Polskich 20, 04–730 Warszawa, Poland, e-mail: krzymoz@epf.pl

Received: 06.08.2010 Accepted: 15.09.2010

Copyright © Polskie Towarzystwo Kardiologiczne

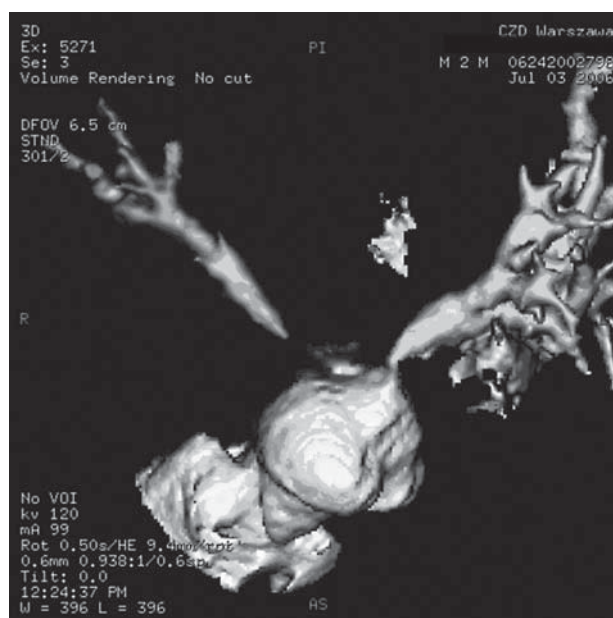


Figure 1. Angio-computed tomography scan demonstrates critical stenosis in the proximal part of the right pulmonary artery and slightly stenotic changes to the left pulmonary artery

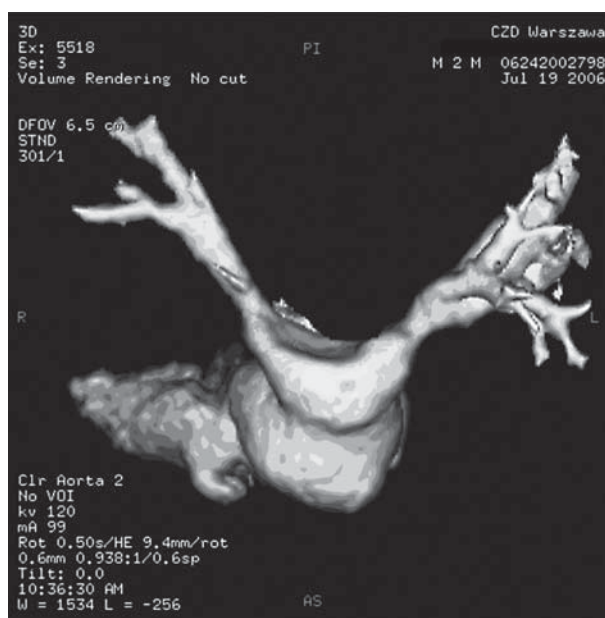

Figure 3. Angio-computed tomography demonstrates widely reconstructed right and intermediate pulmonary arteries, with sufficient enlargement of the left pulmonary artery orifice

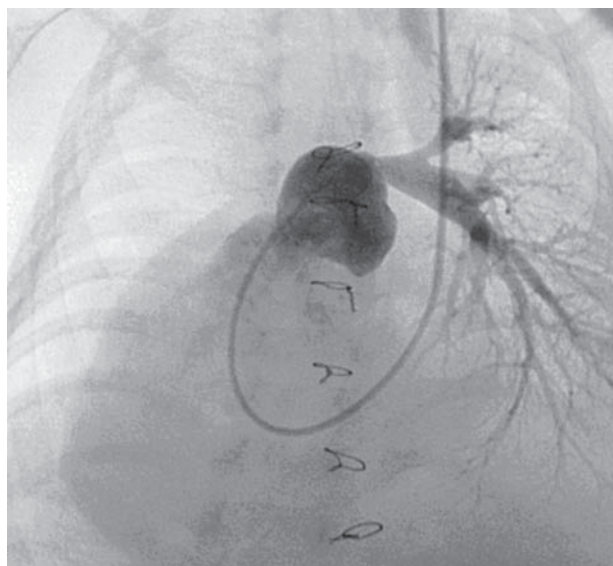

Figure 2. Angiography performed two months after arterial switch operation reveals high right ventricle pressure and hypertrophy

cardiography. Angio-computed tomography (CT) scans demonstrated critical stenosis in the proximal part of the right PA and mild stenotic changes of the left PA (Fig. 1).

The child was referred for interventional catheterisation aimed for PA balloon angioplasty. The angiography, performed two months after ASO (Fig. 2), revealed high RV pressure and hypertrophy. The PA angioplasty was ineffective and

the boy was referred for surgical treatment. Significant occlusion of the right PA ostium with retraction of the pericardial patch was found. The PA reconstruction was performed using a large cryopreserved homogenic pericardial patch. The postoperative course was uneventful and the pressure gradient was significantly lower in postoperative measurements (25 torr and 41 torr, respectively). The pulmonary flow distributions in chest X-ray were normal. Angio-CT demonstrated widely reconstructed right PA and intermediate PA with sufficient enlargement of the left PA orifice (Fig. 3). The child was transferred to Cardiac Surgery and then to Cardiac Ward, and discharged home in a good general condition 17 days after surgery. He is still under ambulatory clinical observation without symptoms of heart failure or lung abnormalities in the physical and imaging examinations.

DISCUSSION

Pulmonary artery stenosis remains a rare complication after ASO procedure [4]. Many papers have stressed that fresh autologous pericardium should be the material of choice for a patch graft [4–6]. The slowly ongoing retraction of the pericardial patch was responsible for the gradually increased pressure gradient between the RV and right PA in our case. Fresh autologous pericardium retraction is the effect of mixed reactions including fibrosis, wall thinning and dilatation [7]. Stabilising the pericardial implants (glutaraldehyde rinsing) alleviated the fibrosis and tissue retraction that were observed within the fresh implant [7, 8]. Balloon angioplasty can be the first therapeutic choice, with a low complication rate and the

potential benefit of the procedure [9]. Similarly, endovascular stent implantations are effective and safe, with satisfactory early and mid-term results [10]. Unfortunately, the right PA in our case was too small for these methods. The second surgical reconstruction, using a cryopreserved homologous pericardial patch, was successful. We speculate that patch preparation method prevents their retraction and made this technique sufficient for the prevention of re-stenosis and a significantly improved prognosis.

Acknowledgements

We gratefully acknowledge the support of Dr Maria Zubrzycka, Dr Andrzej Kościeszka and Dr Małgorzata Mirkowicz-Malek from the Cardiology, Radiology and Cardiac Surgery Departments at the Children's Memorial Health Institute. Without their assistance, this paper would not have been possible.

Conflict of interest: none declared

References

1. McMahon JC, Snyder CS, Rivenes SM, Sang CJ, Freser CF. Neonatal arterial switch operation for transposition of the great arteries in a patient with mirror image dextrocardia and situs inversus totalis. *Tex Heart Inst J*, 2000; 27: 193–195.
2. Di Donato RM, Wernovsky G, Jonas RA, Mayer JE Jr, Keane JF, Castaneda AR. Corrected transposition in situs inversus. Biventricular repair of associated cardiac anomalies. *Circulation*, 1991; 84 (5 suppl.): III 193–199.
3. Oppido G, Napoleone CP, Luca R, Gargiulo G. Arterial switch operation for a complex transposition of the great arteries in dextrocardia. *Eur J Cardiothorac Surg*, 2005; 27: 165–167.
4. Iha K, Kojima K, Kusaba A. Morphological, immunohistological and fibrinolytic features of patch graft for reconstruction of the inferior vena cava. *J Cardiovasc Surg*, 1994; 2: 592–597.
5. Planche C, Bruniaux J, Lacour-Gayet F et al. Switch operation for transposition of the great arteries in neonates. A study of 120 patients. *J Thorac Cardiovasc Surg*, 1988; 96: 354–363.
6. Prifi E, Crucean A, Bonacchi M et al. Early and long term outcome of the arterial switch operation for transposition of the great arteries: predictors and functional evaluation. *Eur J Cardiothorac Surg*, 2002; 22: 864–873.
7. Cheung PT, Choo SJ, Grobe AC et al. Behavior of vital and killed autologous pericardium in the descending aorta of sheep. *J Thorac Cardiovasc Surg*, 1999; 118: 998–1005.
8. Kumar SP, Prabhakar G, Kumar M et al. Comparison of fresh and glutaraldehyde-treated autologous stent pericardium as pulmonary valve replacement. *J Card Surg*, 1996; 10: 545–551.
9. Nakanishi T, Matsumoto Y, Seguchi M, Nakazawa M, Imai Y, Momma K. Balloon angioplasty for postoperative pulmonary artery stenosis in transposition of the great arteries. *J Am Coll Cardiol*, 1993; 22: 859–866.
10. Formigari R, Santoro G, Guccione P et al. Treatment of pulmonary artery stenosis after arterial switch operation: stent implantation vs. balloon angioplasty. *Catheter Cardiovasc Interv*, 2000; 50: 207–211.