

# Echocardiographic quantitative analysis of resting myocardial function for the assessment of viability after myocardial infarction — comparison with magnetic resonance imaging

Piotr Lipiec<sup>1</sup>, Ewa Szymczyk<sup>1</sup>, Błażej Michalski<sup>1</sup>, Ludomir Stefańczyk<sup>2</sup>, Bartłomiej Woźniakowski<sup>2</sup>, Arkadiusz Rotkiewicz<sup>2</sup>, Konrad Szymczyk<sup>2</sup>, Jarosław D. Kasprzak<sup>1</sup>

<sup>1</sup>2<sup>nd</sup> Chair of Cardiology, Medical University of Lodz, Lodz, Poland

<sup>2</sup>Department of Radiology and Imaging Diagnostics, Medical University of Lodz, Lodz, Poland

## Abstract

**Background and aim:** The study was set out to assess feasibility and diagnostic value of the echocardiographic quantitative analysis of the resting regional systolic function (i.e. strain and strain rate) with use of the speckle tracking (2D strain) for myocardial viability assessment in patients with acute myocardial infarction (MI) treated with primary angioplasty. The reference method was the late enhancement magnetic resonance imaging (LE MRI).

**Methods:** The study group consisted of 40 patients (29 men, mean age  $61 \pm 9$  years) in whom resting echocardiographic examination was performed 7–10 days after MI with peak systolic longitudinal strain (STS) and systolic longitudinal strain rate (SLSR) measurement by 2D strain technique on external workstation (EchoPac 6.1.0., GE Vingmed Ultrasound). Within 72 h LE MRI was performed in all patients, with visual assessment of late enhancement in all segments of the left ventricle. Viability of a segment was assessed based on two distinct, frequently adopted criteria: LE extent  $\leq 50\%$  or  $\leq 75\%$  of the wall thickness.

**Results:** Due to suboptimal image quality 70 (10.9%) of the segments were excluded from 2D strain analysis. In the analysis of akinetic and dyskinetic segments, SLS and SLSR measurements with 2D strain technique had good discrimination value for viability defined as LE extent of  $\leq 75\%$  by MRI (area under the ROC curve 0.715 and 0.705, respectively; diagnostic accuracy of the criterion  $SLS \leq -7.61\%$  was 72.8%; diagnostic accuracy of the criterion  $SLSR \leq -0.79/s$  was 64.9%). However, when the  $\leq 50\%$  viability criterion by LE MRI was used, only SLS measurement could be used for viability assessment, with sufficient diagnostic value (area under the ROC curve 0.620; diagnostic accuracy of the criterion  $SLS \leq -9.77\%$  was 57%). In the analysis of all segments, including hypokinetic and normokinetic segments, SLS and SLSR measurements did not provide additional information, beyond that of the visual viability analysis.

**Conclusions:** Resting quantitative echocardiographic analysis of myocardial function seems to be a promising tool for myocardial viability assessment. There is a trend towards greater diagnostic value of SLS than SLSR measurements.

**Key words:** viability, myocardium, echocardiography, magnetic resonance imaging

Kardiol Pol 2011; 69, 9: 915–922

## INTRODUCTION

Myocardial viability is defined as structural integrity, enabling the cardiomyocytes to undertake systolic function. Usually the issue of viability is considered in relation to akinetic seg-

ments (i.e. segments with no resting contractile function). Lack of contractility does not necessarily mean that the particular area of the myocardium is non-viable. Such contractility defects may also be present in the muscle which is viable, but

### Address for correspondence:

Piotr Lipiec, MD, PhD, 2<sup>nd</sup> Chair of Cardiology, Medical University of Lodz, ul. Kniaziewiczza 1/5, 91–347 Łódź, Poland, e-mail: lipiec@ptkardio.pl

Received: 12.01.2011 Accepted: 06.04.2011

Copyright © Polskie Towarzystwo Kardiologiczne

presents reversible contractile dysfunction due to hibernation or stunning [1]. In the clinical practice three methods of detection of the viable myocardium, with confirmed diagnostic value are used: low-dose dobutamine echocardiography, magnetic resonance imaging (MRI) with late gadolinium enhancement, and single photon emission computed tomography [2, 3].

Resting echocardiography is usually the first imaging modality to be used for myocardial function and viability assessment. It allows for identification of areas with preserved systolic function, thus confirming their preserved viability, and areas that do not display resting systolic function (i.e. akinetic), in which viability assessment is necessary. However, the ability of routine resting echocardiography to effectively analyse viability is limited. Actually, the only parameter that can be used, is wall thickness — its marked reduction ( $\leq 6$  mm) points to the presence of scar and irreversible injury with high probability [4]. Such areas can display paradoxical movement (dyskinesia).

In the recent years echocardiographic techniques of quantitative assessment of regional systolic function were introduced — strain and strain rate analysis [5]. Initially, imaging of strain and strain rate was based on tissue Doppler technique [6]. The method, however, had certain limitations. Significant progress was made with the advent of automatic myocardial speckle tracking in standard echocardiographic views on the grey scale [7]. Due to feasibility of precise myocardial function assessment, these techniques are promising in terms of myocardial viability assessment in resting images of the heart — which, due to the imprecise visual method of analysis — have been of limited value for viability detection. Encouraging results were published in both experimental and clinical studies [8–10]. Such approach to viability assessment, based on resting echocardiography, without the need of contrast or drug administration, would represent a great step forward in cardiac imaging.

The aim of our study was the assessment of the diagnostic value of quantitative echocardiographic analysis of the regional systolic function (strain and strain rate) with speckle tracking technique (2D strain) for the assessment of myocardial viability in post-infarction patients. The reference method was the late enhancement assessment by MRI (LE MRI).

## METHODS

### Study group

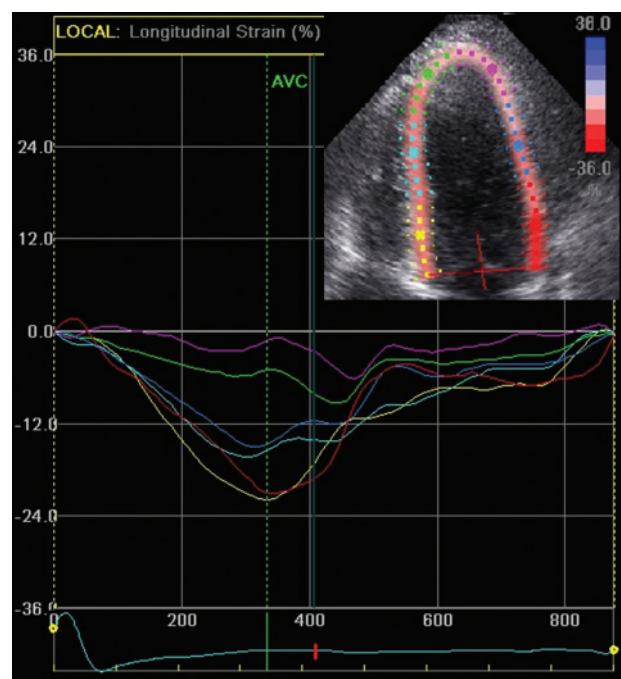
Forty patients (29 men, mean age  $61 \pm 9$  years) hospitalised due to first ST-segment elevation myocardial infarction (MI), successfully treated with primary angioplasty (with post-procedural TIMI 3 flow) were included. The infarct-related artery was the left anterior descending (LAD) in 22 (55%), in 6 (15%) patients — the left circumflex (LCX), and in 12 (30%) patients — the right coronary artery (RCA).

### Resting echocardiography

In all patients, a resting echocardiographic examination was performed 7–10 days ( $8.3 \pm 1.0$  days) after the primary angioplasty (Vivid 7, GE Vingmed Ultrasound, harmonic imaging 2.0/4.3 MHz with maximum temporal resolution for a given sector width).

Cine images acquired in the apical views were digitally recorded on the system's hard disk. Visual analysis of the contractile function of all the 16 segments was subsequently performed. Four-point score was adopted (including normokinesia, hypokinesia, akinesia and dyskinesia). In order to limit the subjectiveness of the method, the visual analysis of regional systolic function was performed jointly by two experienced physicians performing echocardiography on a daily basis. Moreover, left ventricular ejection fraction (LVEF) was calculated with modified Simpson's method [11].

With the speckle tracking algorithm, peak systolic longitudinal strain (STS) and systolic longitudinal strain rate (SLSR) measurements were performed in 16 segments of the LV (with the end of systole defined based on the aortic closure) on an external workstation (EchoPac 6.1.0., GE Vingmed Ultrasound) (Fig. 1). Segments with insufficient quality for the assessment of the parameters were excluded from the analysis.



**Figure 1.** Quantitative analysis of the regional myocardial systolic function (longitudinal strain) with speckle tracking technique (2D strain). Day 8 after anterior myocardial infarction treated with primary angioplasty, 4 chamber apical view. X-axis: time [ms], Y-axis: segmental strain [%]. Severely reduced systolic strain of the apical segments of septum and lateral wall (violet and green curves); AVC — aortic valve closure

Time needed to perform the measurements was also measured in each patient.

### Magnetic resonance and late gadolinium enhancement

Within 72 h of echocardiography LE MRI was performed in all patients, with visual assessment of LE in all 16 segments of the LV. The examination was performed using a 1.5 T system (Avanto, Siemens Medical Solutions) with a 16-channel coil. The images were acquired 12 min after injection of the paramagnetic gadolinium contrast media at the dose of 0.2 mL/kg (Gd-DTPA, Magnevist, Schering) during end-expiratory breath hold. Short axis images of the heart were acquired with slice thickness of 8 mm and by a gradient echo sequence with prospective ECG gating. Inversion time was between 270 and 360 ms and was individually adjusted to suppress the signal of viable myocardium and to provide optimal contrast between necrotic and viable areas.

For analysis, the images were exported to an external workstation (Leonardo, Siemens Medical Solutions). Based on short and long axis images, areas with LE were assessed semi-quantitatively (visually). Viability of a segment was assessed based on two distinct, frequently adopted criteria: LE extent  $\leq 50\%$  or  $\leq 75\%$  of the wall thickness. In order to limit the subjectiveness of the analysis, the visual LE assessment was performed jointly by two investigators.

### Statistical analysis

Quantitative variables were initially tested for normality of data distribution by the Kolmogorov-Smirnov test. In case of nor-

mal distribution, data are presented as means and SD; variables that did not follow normal distribution are presented as medians and upper and lower quartiles. A  $p$  value  $< 0.05$  was considered as significant.

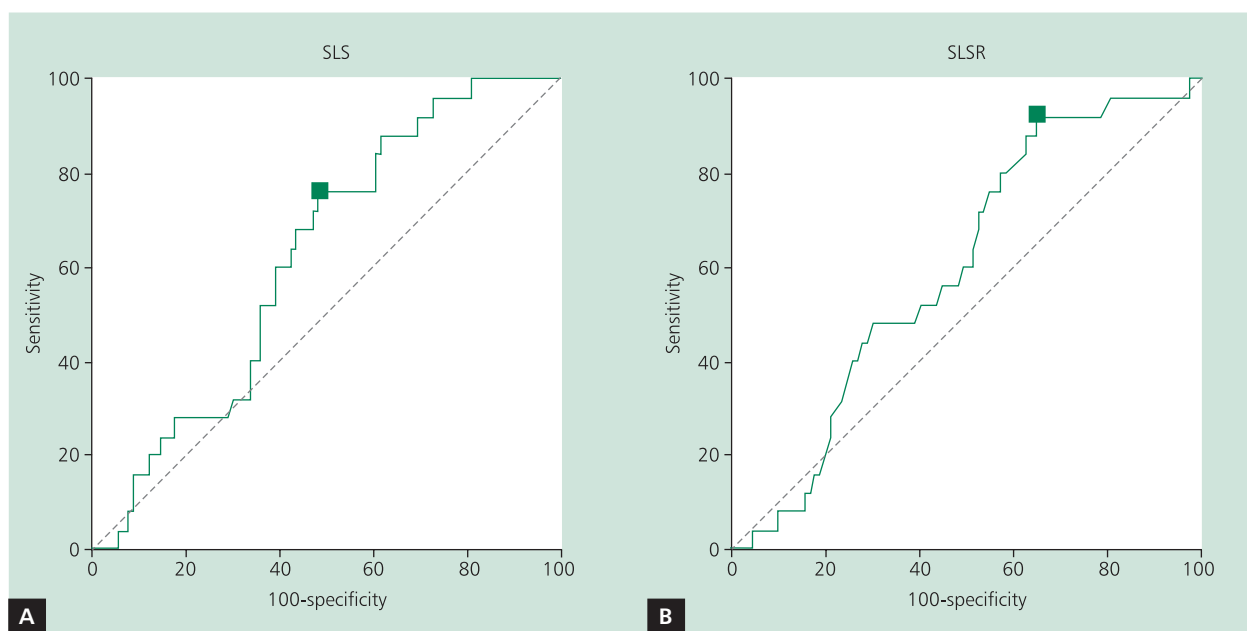
In order to determine the most accurate threshold value for SLS and SLSR for viability detection, the results were analysed with use of four-field result table with variable threshold value, with use of the receiver operating characteristic (ROC) curve.

### RESULTS

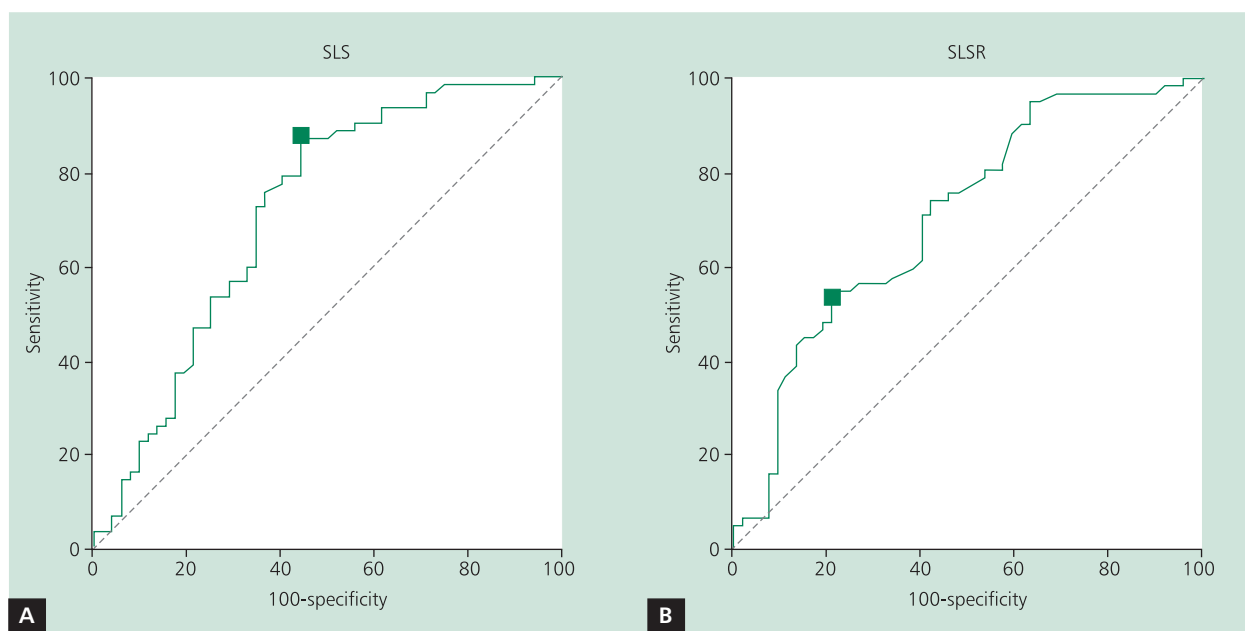
The mean LVEF value in the study group was  $48\% \pm 7\%$ . Due to inadequate image quality, preventing speckle tracking 70 (10.9%) of the segments were excluded from the analysis. Mean duration of the analysis was  $6 \pm 2$  min. The duration was chiefly related to baseline image quality. Comparative viability assessment of 570 LV segments with the use of both speckle tracking and LE MRI was carried out, including 111 akinetic and 3 dyskinetic segments. The dyskinesia was mild and the wall thickness of these segments was not reduced, hence their viability could not be excluded based on resting echocardiography. All patients were in sinus rhythm, with a mean heart rate of  $62 \pm 8$  bpm.

### Analysis of akinetic and dyskinetic segments on resting echocardiography

The results of the analysis of SLS and SLSR diagnostic value for detection of viability in akinetic or dyskinetic segments as confirmed by LE MRI are presented in Figures 2 and 3 as well as in Table 1.



**Figure 2.** The ROC curves showing diagnostic value of systolic longitudinal strain (SLS) (A) and systolic longitudinal strain rate (SLSR) (B) measurements for the detection of viability defined as late enhancement  $\leq 50\%$  of the wall thickness in akinetic/dyskinetic segments (SLS – AUC = 0.620, 95% CI 0.525–0.710; SLSR – AUC = 0.597, 95% CI 0.501–0.688). Squares denote points of the highest diagnostic accuracy (SLS  $\leq -9.77\%$ , SLSR  $\leq -0.5/s$ )



**Figure 3.** The ROC curves showing diagnostic value of systolic longitudinal strain (SLS) (A) and systolic longitudinal strain rate (SLSR) (B) measurements for the detection of viability defined as late enhancement  $\leq 75\%$  of the wall thickness in akinetic/dyskinetic segments (SLS – AUC = 0.715, 95% CI 0.623–0.796;  $p = 0.0001$ ; SLSR – AUC = 0.705, 95% CI 0.612–0.787;  $p = 0.0001$ ). Squares denote points of the highest diagnostic accuracy (SLS  $\leq -7.61\%$ , SLSR  $\leq -0.79/s$ )

**Table 1.** Diagnostic value of the highest diagnostic accuracy criteria based on SLS and SLSR measurements for the detection of viability in akinetic and dyskinetic segments as defined based on late enhancement assessment by magnetic resonance imaging (LE MRI)

Parameter	Sensitivity	Specificity	Positive PV	Negative PV	Accuracy
<b>Viability as LE <math>\leq 50\%</math> of the wall thickness</b>					
SLS $\leq -9.77\%$	76.0%	51.7%	30.6%	88.5%	57.0%
SLSR $\leq -0.5/s$	92.0%	34.8%	28.4%	93.9%	47.3%
<b>Viability as LE <math>\leq 75\%</math> of the wall thickness</b>					
SLS $\leq -7.61\%$	87.1%	55.8%	70.1%	78.4%	72.8%
SLSR $\leq -0.79/s$	53.2%	78.9%	75.0%	58.6%	64.9%

SLS — peak systolic longitudinal strain; SLSR — peak systolic longitudinal strain rate; LE — late enhancement; PV — predictive value

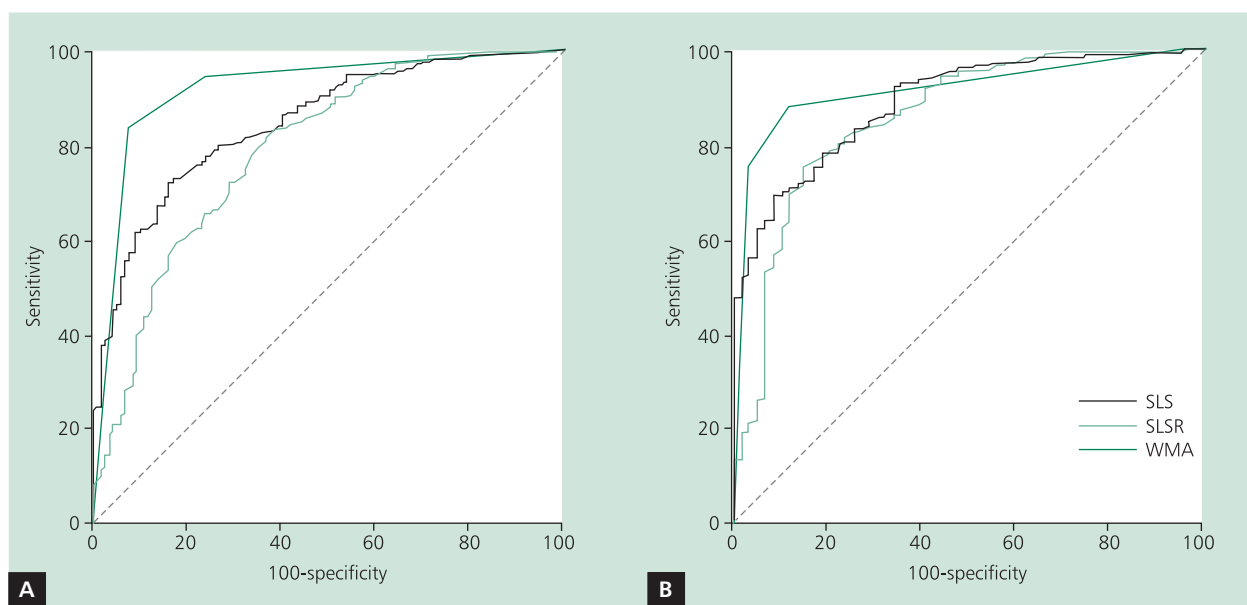
With the assumption that viable segments are those in which LE was 0–50% of the wall thickness by MRI, the area under the ROC curve was significantly greater than 0.5 for SLS ( $p = 0.0459$ ) but not for SLSR ( $p = 0.115$ ). The highest diagnostic accuracy of the SLS-based criterion (57.0%) was higher than that of SLSR-based criterion (47.3%), but the difference was not significant ( $p = 0.182$ ).

On the other hand, with the assumption that viable segments are those in which LE was 0–75% of the wall thickness, the area under the ROC curve was not significantly different for SLS in comparison with that of SLSR ( $p = 0.813$ ). The highest diagnostic accuracy of the SLSR-based criterion (72.8%) was higher than that of SLS-based criterion (64.9%), but the difference was not significant ( $p = 0.252$ ).

### Analysis of all left ventricular segments

We have also carried out diagnostic accuracy analysis of this method of viability assessment for all LV segments (irrespective of the results of visual analysis of their resting systolic function). Moreover, in order to assess whether SLS and SLSR measurements have additional diagnostic value for viability detection when compared to standard semi-quantitative (visual) echocardiographic assessment of the resting wall motion abnormalities (WMA), the ROC curves for the detection of viability defined according to LE MRI were compared for SLS, SLSR and WMA. The results of this analysis are presented in Figure 4.

With the assumption that viable segments are those in which LE was 0–50% of the wall thickness by MRI, the area



**Figure 4.** Comparison of the ROC curves showing diagnostic value of systolic longitudinal strain (SLS), systolic longitudinal strain rate (SLSR) and visual analysis of resting wall motion abnormalities (WMA) for the detection of viability defined as late enhancement (LE)  $\leq$  50% of the wall thickness (**A**) and LE  $\leq$  75% of the wall thickness (**B**)

under the ROC curve for SLS measurements (AUC = 0.847, 95% CI 0.814–0.875) was significantly greater than that of SLSR (AUC = 0.789, 95% CI 0.753–0.822,  $p = 0.003$ ). It was found that the area under the ROC curve for resting WMA assessment was significantly greater than those of SLS ( $p = 0.005$ ) and SLSR ( $p < 0.001$ ).

On the other hand, with the assumption that viable segments are those in which LE was 0–75% of the wall thickness, the area under the ROC curve was not significantly different for SLS (AUC = 0.891, 95% CI 0.862–0.915) in comparison with that of SLSR (AUC = 0.859, 95% CI 0.827–0.886,  $p = 0.183$ ). Moreover, no significant differences were found between areas under the ROC curves for resting WMA and for SLS and SLSR measurements (WMA vs SLS:  $p = 0.488$ ; WMA vs SLSR:  $p = 0.122$ ).

## DISCUSSION

Our results show that although echocardiographic quantitative analysis of the systolic function by speckle tracking is a safe study, the viability analysis is not possible in as many as 11% of the segments, due to suboptimal quality of the images usually obtained in the clinical practice. In the akinetic and dyskinetic segment analysis in patients after acute MI, the SLS and SLSR measurements with the 2D strain technique have a good diagnostic value for the detection of viability defined as LE involving 0–75% of the wall thickness by MRI.

However, when using the 0–50% LE viability criterion, only SLS can be used for its detection, even though its dia-

gnostic value is limited. In the viability assessment of all LV segments including those normo- and hypokinetic, SLS and SLSR measurements do not provide additional significant information when compared to visual contractility assessment. However, taking into account that 2D strain analysis does not require that much experience as visual contractility analysis, it seems that in more difficult cases it can be used by less experienced echocardiographers as initial viability analysis of all LV segments.

Initial studies referring to the possibility of applying resting echocardiographic analysis of strain and strain rate for viability detection were based on experimental models and on tissue Doppler technique. Weidemann et al. [12], in a model of non-transmural MI in 10 pigs, found a significant negative correlation between the extent of transmural necrosis on histopathology and systolic radial strain ( $r = 0.88$ ,  $p < 0.001$ ) and slightly weaker correlation with systolic radial strain rate ( $r = 0.76$ ,  $p < 0.01$ ).

One of the largest clinical studies relating to this issue was the study by Zhang et al. [13], who analysed resting values of the myocardial velocity and longitudinal strain rate with use of tissue Doppler technique in 47 patients at 2–6 days after MI and in 60 healthy volunteers. It should be noted that strain was not analysed in that study. The presence of myocardial necrosis was assessed based on LE MRI. The results of that study showed that maximum resting systolic strain rate of  $> -0.59/s$  allows for detection of transmural necrosis (100% of the wall thickness) with sensitivity and specificity of 90.9% and 96.4%, respectively.

Hanekom et al. [14], based also on tissue Doppler technique, found that resting measurements of systolic strain rate and peak strain (including post-systolic strain) had no diagnostic value for the prediction of myocardial function recovery. The only resting parameter that was significantly different in segments that were displaying function recovery at follow-up and segments that did not recover, was resting systolic longitudinal strain ( $p = 0.017$ ).

Another interesting, although small study on the role of the analysis of the resting systolic function in a limited patient group (40 akinetic segments in 20 patients after primary angioplasty) was published by Park et al. [10]. The authors concluded, that akinetic segments in which recovery of function was proved at follow up, had significantly higher strain rate in the early diastolic phase ( $p = 0.04$ ) on echocardiography carried out one day after the procedure. It should be noted, however that the parameters that came close to statistical significance were: longitudinal systolic strain ( $p = 0.10$ ) and the longitudinal strain rate ( $p = 0.16$ ). Differences in peak (including post-systolic) values of strain and strain rate between segments with preserved viability and non-viable segments were far from significant ( $p = 0.51$ – $0.69$ ). The lack of diagnostic and prognostic value of post-systolic strain measurements for the assessment of viability and prediction of functional recovery was previously reported by Lim et al. [15] and Tekelsen et al. [16], as well as Hanekom et al. [14]. On the other hand, encouraging results published by Park et al. [10] on resting diastolic function assessment for viability analysis were not confirmed by Hoffmann et al. [17]. These authors did not find significant differences in longitudinal strain rate in early diastole (E) and during atrial contraction (A) in 37 patients with post-infarction systolic dysfunction in viable in comparison to non-viable segments, as defined by positron emission tomography.

However, all the studies mentioned above were based on regional systolic function analysis by tissue Doppler technique. On the other hand, the possibility of using speckle tracking technique (2D strain) for resting viability analysis is less well documented. In an experimental study by Migrino et al. [8] it was found that peak systolic strain was significantly different between transmural and non-transmural scar on pathology exam (50% of the wall thickness was adopted as a threshold value). In a study by Roes et al. [18], in a group of 90 patients with chronic ischaemic myocardial dysfunction it was found that global longitudinal strain of LV segments correlated well with the total LE extent on MRI ( $r = 0.62$ ,  $p < 0.001$ ), and longitudinal strain of  $-4.5\%$  allowed for differentiation between viable and non-viable segments with transmural LE, with 81.2% sensitivity and 81.6% specificity [18].

Our study results show that with viability defined as LE involving 0–50% of the wall thickness by MRI, the diagnostic value of 2D strain technique is low. Area under the ROC cu-

ve for the detection of viability thus defined, was significantly higher than 0.5 only for systolic strain measurements (0.620), while the diagnostic accuracy of this parameter ( $SLS \leq -9.77\%$ ) was only 57%. Only when the threshold value of LE was increased to 75% of the wall thickness, the diagnostic value of systolic strain (AUC ROC 0.715; optimal diagnostic accuracy  $SLS \leq -7.61\% = 72.8\%$ ) and systolic strain rate (AUC 0.705; diagnostic accuracy  $SLSR \leq -0.79/s = 64.9\%$ ) for viability detection was increased.

In comparative analyses of diagnostic accuracy of the criteria based on systolic strain and strain rate measurements for viability detection, a trend can be noticed towards greater diagnostic value of strain in comparison with strain rate measurement. This is in concordance with the previously mentioned studies by Weidemann et al. [12], Hanekom et al. [14] and Park et al. [10]. This can probably be partially explained by a greater number of artefacts in the graphs of strain rate in comparison to graphs of strain measurements.

## CONCLUSIONS

In summary, speckle tracking technique seems a valuable tool for resting viability assessment, however currently not devoid of limitations. Newer, semi-automatic algorithms will probably allow for improving diagnostic value and shortening the duration of the analysis, what seems necessary if the technique is to be useful in clinical practice [19].

*The study was funded by the Polish Ministry of Science and Higher Education (Scientific grant No N402 4254 33).*

**Conflict of interest:** none declared

## References

1. Camici PG, Prasad SK, Rimoldi OE. Stunning, hibernation, and assessment of myocardial viability. *Circulation*, 2008; 117: 103–114.
2. Underwood SR, Bax JJ, vom Dahl J et al. Study Group of the European Society of Cardiology. Imaging techniques for the assessment of myocardial hibernation. Report of a Study Group of the European Society of Cardiology. *Eur Heart J*, 2004; 25: 815–836.
3. Senior R. Diagnostic and imaging considerations: role of viability. *Heart Fail Rev*, 2006; 11: 125–134.
4. Schinkel AF, Bax JJ, Boersma E et al. Assessment of residual myocardial viability in regions with chronic electrocardiographic Q-wave infarction. *Am Heart J*, 2002; 144: 865–869.
5. Bijnens BH, Cikes M, Claus P, Sutherland GR. Velocity and deformation imaging for the assessment of myocardial dysfunction. *Eur J Echocardiogr*, 2009; 10: 216–226.
6. Heimdal A, Støylen A, Torp H, Skjaerpe T. Real-time strain rate imaging of the left ventricle by ultrasound. *J Am Soc Echocardiogr*, 1998; 11: 1013–1019.
7. Perk G, Tunick PA, Kronzon I. Non-Doppler two-dimensional strain imaging by echocardiography—from technical considerations to clinical applications. *J Am Soc Echocardiogr*, 2007; 20: 234–243.
8. Migrino RQ, Zhu X, Pajewski N, Brahmabhatt T, Hoffmann R, Zhao M. Assessment of segmental myocardial viability using regional 2-dimensional strain echocardiography. *J Am Soc Echocardiogr*, 2007; 20: 342–351.

9. Kymälä MM, Antila MK, Kivistö SM, et al. Tissue Doppler strain-mapping in the assessment of the extent of chronic myocardial infarction: validation using magnetic resonance imaging. *Eur J Echocardiogr*, 2008; 9: 678–684.
10. Park SM, Miyazaki C, Prasad A et al. Feasibility of prediction of myocardial viability with Doppler tissue imaging following percutaneous coronary intervention for ST elevation anterior myocardial infarction. *J Am Soc Echocardiogr*, 2009; 22: 183–189.
11. Schiller NB, Shah PM, Crawford M et al. Recommendations for quantitation of the left ventricle by two-dimensional echocardiography. American Society of Echocardiography Committee on Standards, Subcommittee on Quantitation of Two-Dimensional Echocardiograms. *J Am Soc Echocardiogr*, 1989; 2: 358–267.
12. Weidemann F, Dommke C, Bijns B et al. Defining the transmural of a chronic myocardial infarction by ultrasonic strain-rate imaging: implications for identifying intramural viability: an experimental study. *Circulation*, 2003; 107: 883–888.
13. Zhang Y, Chan AK, Yu CM et al. Strain rate imaging differentiates transmural from non-transmural myocardial infarction: a validation study using delayed-enhancement magnetic resonance imaging. *J Am Coll Cardiol*, 2005; 46: 864–871.
14. Hanekom L, Jenkins C, Jeffries L et al. Incremental value of strain rate analysis as an adjunct to wall-motion scoring for assessment of myocardial viability by dobutamine echocardiography: a follow-up study after revascularization. *Circulation*, 2005; 112: 3892–3900.
15. Lim P, Pasquet A, Gerber B et al. Is postsystolic shortening a marker of viability in chronic left ventricular ischemic dysfunction? Comparison with late enhancement contrast magnetic resonance imaging. *J Am Soc Echocardiogr*, 2008; 21: 452–457.
16. Terkelsen CJ, Poulsen SH, Nørgaard BL et al. Does postsystolic motion or shortening predict recovery of myocardial function after primary percutaneous coronary intervention? *J Am Soc Echocardiogr*, 2007; 20: 505–511.
17. Hoffmann R, Altiok E, Nowak B et al. Strain rate analysis allows detection of differences in diastolic function between viable and nonviable myocardial segments. *J Am Soc Echocardiogr*, 2005; 18: 330–335.
18. Roes SD, Mollema SA, Lamb HJ, van der Wall EE, de Roos A, Bax JJ. Validation of echocardiographic two-dimensional speckle tracking longitudinal strain imaging for viability assessment in patients with chronic ischemic left ventricular dysfunction and comparison with contrast-enhanced magnetic resonance imaging. *Am J Cardiol*, 2009; 104: 312–317.
19. Delgado V, Mollema SA, Ypenburg C et al. Relation between global left ventricular longitudinal strain assessed with novel automated function imaging and biplane left ventricular ejection fraction in patients with coronary artery disease. *J Am Soc Echocardiogr*, 2008; 21: 1244–1250.

# Echokardiograficzna ilościowa analiza spoczynkowej funkcji mięśnia sercowego w celu oceny żywotności po zawale serca — porównanie z rezonansem magnetycznym

Piotr Lipiec<sup>1</sup>, Ewa Szymczyk<sup>1</sup>, Błażej Michalski<sup>1</sup>, Ludomir Stefańczyk<sup>2</sup>, Bartłomiej Woźniakowski<sup>2</sup>, Arkadiusz Rotkiewicz<sup>2</sup>, Konrad Szymczyk<sup>2</sup>, Jarosław D. Kasprzak<sup>1</sup>

<sup>1</sup>II Katedra Kardiologii, Uniwersytet Medyczny w Łodzi, Łódź

<sup>2</sup>Zakład Radiologii i Diagnostyki Obrazowej, Uniwersytet Medyczny w Łodzi, Łódź

## Streszczenie

**Wstęp i cel:** Celem pracy była ocena możliwości zastosowania i wartości diagnostycznej echokardiograficznej ilościowej analizy spoczynkowej regionalnej funkcji skurczowej (odkształcenia i tempa odkształcenia) techniką śledzenia markerów akustycznych (2D *strain*) w celu oceny żywotności mięśnia sercowego u pacjentów po ostrym zawale leczonym metodą pierwotnej angioplastyki. Metodą referencyjną była technika późnego wzmocnienia w rezonansie magnetycznym (LE MRI).

**Metody:** Do badania włączono 40 pacjentów (29 mężczyzn, śr. wiek  $61 \pm 9$  lat), u których w 7.–10. dniu po zawale wykonano spoczynkowe badanie echokardiograficzne z pomiarami maksymalnego skurczowego podłużnego odkształcenia (SLS) oraz maksymalnego skurczowego tempa podłużnego odkształcenia (SLSR) techniką 2D *strain* na zewnętrznej stacji roboczej (EchoPac 6.1.0., GE Vingmed Ultrasound). W ciągu 72 godzin przeprowadzono u wszystkich pacjentów badanie techniką LE MRI z wizualną oceną wielkości obszaru późnego wzmocnienia w segmentach mięśnia lewej komory. Żywotność segmentów określano na podstawie dwóch różnych, powszechnie stosowanych kryteriów: LE obejmujące  $\leq 50\%$  lub  $\leq 75\%$  grubości mięśnia.

**Wyniki:** Z powodu suboptymalnej jakości obrazu 70 (10,9%) segmentów wyłączono z analizy techniką 2D *strain*. W analizie segmentów akineetycznych i dyskinetycznych pomiary SLS i SLSR techniką 2D *strain* charakteryzowały się dobrą zdolnością do wykrywania żywotności definiowanej jako LE w MRI obejmujące 0–75% grubości mięśnia sercowego — pole pod krzywą ROC odpowiednio 0,715 i 0,705; dokładność diagnostyczna kryterium  $SLS \leq -7,61\% = 72,8\%$ ; dokładność diagnostyczna kryterium  $SLSR \leq -0,79/s = 64,9\%$ . Jednak przy zastosowaniu jako kryterium żywotności  $\leq 50\%$  grubości mięśnia objętego przez LE w MRI można w celu jej wykrywania zastosować tylko pomiar SLS, choć i on ma jedynie dostateczną wartość diagnostyczną (pole powierzchni pod krzywą ROC 0,620; dokładność diagnostyczna kryterium  $SLS \leq -9,77\% = 57\%$ ). W ocenie żywotności wszystkich segmentów lewej komory (w tym ocenianych wizualnie jako normokinetyczne i hipokinetyczne) pomiary SLS i SLSR nie wносиły dodatkowych, istotnych informacji w stosunku do wizualnej oceny kurczliwości.

**Wnioski:** Spoczynkowa ilościowa echokardiograficzna analiza funkcji mięśnia sercowego wydaje się obiecującym narzędziem w ocenie jego żywotności. Zauważalna jest tendencja do większej wartości diagnostycznej pomiarów SLS niż SLSR.

**Słowa kluczowe:** żywotność, mięsień sercowy, echokardiografia, rezonans magnetyczny

Kardiol Pol 2011; 69, 9: 915–922

## Adres do korespondencji:

dr hab. n. med. Piotr Lipiec, II Katedra Kardiologii, Uniwersytet Medyczny w Łodzi, ul. Kniaźwiczka 1/5, 91–347 Łódź, e-mail: lipiec@ptkardio.pl

Praca wpłynęła: 12.01.2011 r. Zaakceptowana do druku: 06.04.2011 r.