

# Cardiac chambers perforation by pacemaker and cardioverter-defibrillator leads. Own experience in diagnosis, treatment and preventive methods

Perforacje jam serca przez elektrody rozruszników i kardiowerterów-defibrylatorów. Doświadczenia własne w diagnostyce, leczeniu i metodach prewencji

Andrzej Maziarz<sup>1</sup>, Andrzej Ząbek<sup>1</sup>, Barbara Małecka<sup>1</sup>, Andrzej Kutarski<sup>2</sup>, Jacek Lelakowski<sup>1</sup>

<sup>1</sup>Department of Electrophysiology, The John Paul II Hospital, Krakow, Poland

<sup>2</sup>Department of Cardiology, Medical University, Lublin, Poland

## Abstract

Cardiac chamber perforation is an uncommon, but potentially dangerous, complication of implantation of a pacemaker (PM) or a cardioverter-defibrillator (ICD). Different clinical presentations are related to the time between implantation and perforation, localisation of the perforation and concomitant lesions in neighbouring organs. Diagnosis is based on concomitant analysis of the clinical picture, ECG tracings, PM or ICD function check-up with a programmer, and review of echocardiographic, X-ray and computed tomography pictures. We analysed seven cases of perforation. Perforating leads were removed in all cases and a new pacing system was implanted in five cases. Choice of operative technique (unscrewing and direct traction from device pocket, Cook system or surgical procedure with pericardial drainage) depended on the time elapsing between implantation and perforation, the presence of lesions of other organs, and the amount of fluid in the pericardial sac. Avoiding unsafe localisation of a pacing electrode in the apex and free wall of the right ventricle and in the free anterolateral wall of the right atrium, and avoiding leaving an extra length of pacing lead under tension and overscrewing of the lead helix seem to be the best ways of prevention.

**Key words:** cardiac perforation, pacemaker, cardioverter lead

Kardiol Pol 2012; 70, 5: 508–510

## INTRODUCTION

Cardiac chambers perforation by an endocardial lead is an uncommon, but potentially dangerous, complication of implantation of a pacemaker (PM) or a cardioverter-defibrillator (ICD). According to the literature, such a complication may occur in 0.1–0.8% of patients after PM implantation, and in 0.6–5.2% of patients after ICD implantation [1]. The clinical picture of that complication and its sequel depends on the time elapsing from perforation: acute until 5–7 days, subacute from 7–30 days, and delayed after 30 days from procedure, the type of perforating lead (atrial vs ventricular), complications (tamponade, pneumothorax), and other organ lesions.

Diagnosis of heart chamber perforation by endocardial lead relies on concomitant analysis of ECG tracings (with magnet effect), transthoracic and transoesophageal echocardiography, PM or ICD parameters check-up with a program-

mer and chest X-ray, and a computed tomography scan which is recognised as the gold standard [2, 3].

In this paper, we analyse seven cases of heart chamber perforation by pacing lead which were treated in the Department of Electrophysiology, Jagiellonian University Medical College in Krakow in 2009–2010 (three patients implanted in our Department and four patients referred after operations in other hospitals).

## RESULTS

Perforation was detected as acute in three cases, subacute in one, and as delayed in three cases (Table 1). Chest pain was the most typical clinical symptom of perforation. In imaging studies, pericardial fluid was the most common finding. It is important to note that in one of the patients without fluid in the pericardium, the ventricular lead had perforated the right

### Address for correspondence:

Andrzej Maziarz, MD, PhD, Department of Electrophysiology, The John Paul II Hospital, ul. Pędzicka 80, 31–202 Kraków, Poland, e-mail: buna@wp.pl

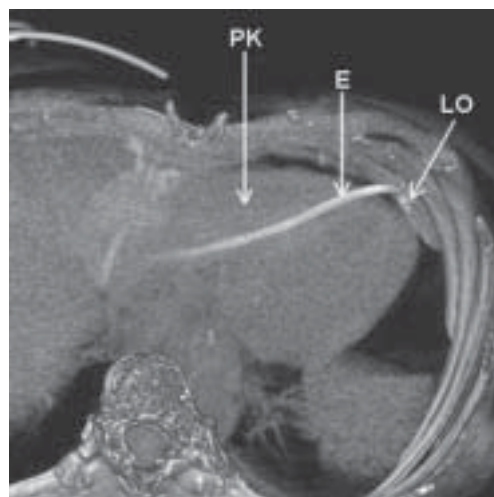
Received: 31.03.2011 Accepted: 22.06.2011

Copyright © Polskie Towarzystwo Kardiologiczne

**Table 1.** Characteristics of patients with heart chamber perforation by endocardial lead treated in 2009–2010

No.	Age	Gender	Time to perforation	Chest pain	Fluid in pericardium	Pacing	Removed leads type and technique	Implanted leads technique	Pericardial drainage technique	Pleural drainage	Emergency surgery
1	84	Female	Acute 2 days	No	Yes	USCI implanted in other facility, no data	USCI-T	No	DS + SZ	Removed by suction	No
2	80	Female	Acute 2 days	Yes	No	Lack	V-T	EN-A, EN-V	No	No	No
3	74	Male	Subacute 5 days	Yes	Yes	Normal	A-T, V-T	EN-A, EN-V	DM in 7 days	P: 150 mL	No
4	67	Female	Chronic 3 years	Yes	Yes	Normal	V-C	EN-V	No	No	No
5	17	Female	Chronic 42 days	No	Yes	Lack	A-T, V-T	No	DM: 1,000 mL	No	Yes, tamponade
6	63	Female	Chronic 2 years	No	Yes, earlier pericardiocentesis in another facility	Normal	A-C	EN-A	P: 475 mL	No	No
7	73	Female	Acute 3 days	Yes	On admission, no later bleeding into pericardium	Lack	V-T	EP-V	DS + SZ	Yes, 1,300 mL	Yes, bleeding to pleura and pericardium

Lead removal: direct traction — T, Cook system — C. Atrial lead implantation: endovascular — EN-A. Ventricular lead implantation: endovascular — EN-V, surgical epicardial — EP-V. Pericardial drainage: surgical by sternotomy and right ventricular suture — DS + SZ, surgical by small incision — DM, puncture — P

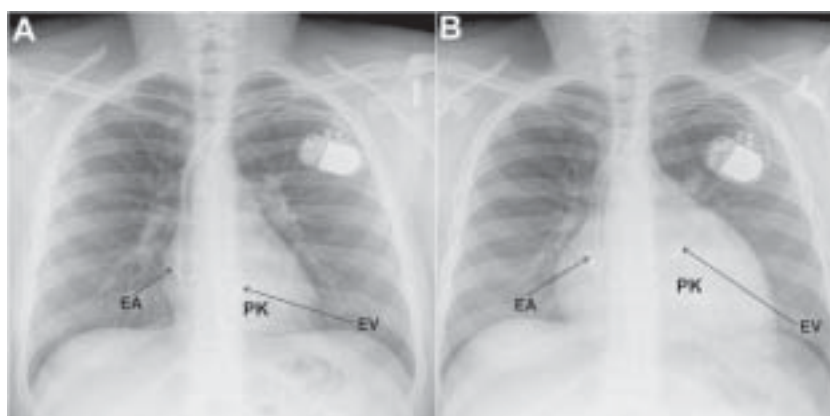


**Figure 1.** Perforation of right ventricle (PK) and left pleura (LO). Chest computed tomography. Reconstruction; E — lead

ventricular wall, pericardium and left pleura and caused a haemorrhage into the pleural cavity treated by an emergent cardio surgical operation in spite of lack of pericardial fluid and signs of tamponade. Pacing failure was present in all three cases of acute perforation by ventricular lead, but normal pacing was present in both cases of perforation by atrial lead and in the case of chronic perforation by ventricular lead.

In scheduling patients for corrective procedures, we took into account the time from implantation and the presence of fluid in the pericardial sac. Two patients with properly functioning DDD pacemakers with detected chronic perforation (more than 12 months from implantation) were selected for percutaneous lead extraction in the Department of Cardiology, Medical University in Lublin. In both cases, only the perforating leads were percutaneously removed (using the Cook system) with cardio surgical back-up without complications.

In the remaining five cases (three acute perforations, one subacute and one chronic in 42 day post procedure), patients were scheduled for elective lead removal by unscrewing and direct traction from the PM pocket or from vascular access sheath (temporary lead — USCI), with cardio surgical back-up and optional pericardial drainage. Two of these patients had to be treated as emergency procedures due to impeding shock after bleeding, to the left pleural space in one case, and cardiac tamponade in the other. In the first case, a general anaesthesia sternotomy was done and the pericardium and left pleura were drained, the perforating ventricular lead was removed by traction from the pocket, the right ventricular wall was sutured with pledges, and the epicardial ventricular lead was implanted and tunnelled into the PM pocket (Fig. 1). In the second case, pericardial drainage was performed, tamponade was relieved, and the whole pacing system was removed via the PM pocket.



**Figure 2.** **A.** Chest X-ray, postero-anterior projection; EV — ventricular lead, excessive length and tension; **B.** Chest X-ray, postero-anterior projection. Fluid in pericardium. Impeding tamponade; EV — ventricular lead, disappearance of lead tension after perforation of right ventricle (PK); EA — atrial lead

In the remaining three cases, procedures were elective. Perforating leads in two cases, and both leads in one case, were removed by unscrewing and traction. The pericardium was drained in one case. In the second case, deferred drainage of the pericardium was performed seven days after both leads removal due to persistent fluid in the pericardium and the appearance of fluid in the left pleural cavity, anaemia and fever. A new pacing system was implanted in five out of seven patients.

Only female gender (86% of patients) and the use of a temporary pacing lead, and leaving an excessive amount of lead under tension (two cases) were predisposing factors for perforation occurrence (Figs. 2A, B). All perforations by ventricular leads and temporary pacing USCI lead were present on the free anterior wall of the right ventricle.

## DISCUSSION

Safely performed implantation is the best way to avoid perforation. Risk factors (female gender, steroids usage, stiff USCI leads) are common for implantation of both atrial and ventricular leads, but the mechanisms of perforation and the clinical symptoms are different. In a case of an active screw-in atrial lead, the thin atrial wall is often perforated only by the spiral helix of the lead. Sometimes a lead is inactive in sense of pacing and intra-atrial sensing, although parameters and function of implanted atrial lead are often normal in spite of perforation [4]. Perforation of the right atrial wall most often occurs when the lead is anchored on the free anterolateral wall of the right atrium. Right atrial appendage and the inferior part of the intraatrial septum are recognised as safe implantation places.

In the case of a ventricular lead perforation, most often the whole lead with pacing poles protrudes through the heart wall with a resulting lack of proper pacing and sensing. Most often perforation occurs in the apex or free wall of the right ventricular outflow tract (RVOT), frequently when whole pres-

sure by straight stylet during implantation is perpendicularly transmitted to the heart wall, and when excessive length of the lead under tension is left and generates additional force leading to perforation [5, 6].

Using an especially flexed stylet allows implantation of a lead on the septal surface of the RVOT [7]. Implantation in RVOT on the septal wall carries the lowest possible risk of cardiac perforation. In our study, all right ventricular perforations occurred on the anterior wall of the right ventricle, and in two cases we were able to show on X-ray pictures an excessive length of pacing lead generating tension on the heart wall.

An adequate strategy should be used to deal with a patient with heart perforation by endocardial lead. Such a patient should be operated on as an emergency procedure in a hybrid operating room with fluoroscopy and the possibility of performing a cardio surgical procedure, immediately after the diagnosis is obtained [8].

**Conflict of interest:** none declared

## References

- Carlson MD, Freedman RA, Levine PA. Lead perforation: incidence in registries. *PACE*, 2008; 31: 13–15.
- Hirschl DA, Jain VR, Spinola-Franco H et al. Prevalence and characterization of asymptomatic pacemaker and ICD lead perforation on CT. *PACE*, 2007; 30: 28–32.
- Khan MN, Joseph G, Khaykin Y et al. Delayed lead perforation: a disturbing trend. *PACE*, 2005; 28: 251–253.
- Geyfman V, Storm RH, Lico SC et al. Cardiac tamponade as complication of active-fixation atrial lead perforations: proposed mechanism and management algorithm. *PACE*, 2011; 30: 98–501.
- Sterliński M, Przybylski A, Maciąg A et al. Subacute cardiac perforations associated with active fixation leads. *Europace*, 2009; 11: 206–212.
- Rydlewska A, Malecka B, Ząbek A et al. Delayed perforation of the right ventricle as a complication of permanent cardiac pacing — is following the guidelines always the right choice? Non standard treatment: a case report and literature review. *Kardiologia Polska*, 2010; 68: 357–361.
- Medi C, Mond HG. Right ventricular outflow tract septal pacing: long-term follow-up of ventricular lead performance. *PACE*, 2009; 32: 172–176.
- Wilkoff BL, Love CJ, Byrd CL et al. Transvenous lead extraction: Heart Rhythm Society expert consensus on facilities, training, indications and patient management. This document was endorsed by the American Heart Association (AHA). *Heart Rhythm*, 2009; 6: 1085–1104.