

Transcatheter aortic valve implantation using direct aortic access: first procedures in Poland

Radosław Wilimski¹, Zenon Huczek², Wojciech Szczawiński¹, Arkadiusz Pietrasik², Marcin Michalak², Piotr Ścisło², Michał Marchel², Leopold Bakoń³, Krzysztof J. Filipiak², Romuald Cichoń¹, Grzegorz Opolski², Janusz Kochman²

¹Department of Cardiac Surgery, The Medical University of Warsaw, Warsaw, Poland

²1st Department of Cardiology, The Medical University of Warsaw, Warsaw, Poland

³2nd Department of Radiology, The Medical University of Warsaw, Warsaw, Poland

Abstract

Transcatheter aortic valve implantation (TAVI) is an alternative option for the treatment of severe aortic stenosis in patients carrying an elevated operative risk of conventional surgical aortic valve replacement (AVR). Recently, data from randomised clinical trials confirmed superiority of TAVI when compared with the conservative treatment in inoperable patients, and its non-inferiority when compared with AVR in a high-risk population.

Transfemoral vascular access remains the preferred route for delivering the bioprosthesis. However, in a significant proportion of patients, the presence of severe iliac-femoral arteriopathy or small vessel diameter render the transfemoral approach unusable. In this article, we report the first Polish experience of two successful TAVI procedures with bioprostheses (both balloon- and self-expandable) delivered using direct aortic access.

Key words: TAVI, aortic stenosis, aortic access, transaortic

Kardiol Pol 2012; 70, 5: 486–493

INTRODUCTION

In the recent years, transcatheter aortic valve implantation (TAVI) has become an alternative therapeutic approach leading to acceptable outcomes in patients with severe, symptomatic aortic valvular stenosis at high perioperative risk or deemed unsuitable candidates for conventional surgical aortic valve replacement (AVR) [1–3]. The role of this therapy in high-risk patients was confirmed by the results of the randomised PARTNER study which showed that TAVI was associated with similar long-term outcomes compared to AVR but was significantly superior (yielding 20% reduction in mortality) to medical treatment combined with aortic valvuloplasty [4, 5].

Currently, two types of aortic bioprostheses are available, the balloon-expandable Edwards SAPIEN™ device (Edwards Lifesciences, Irvine, CA, USA) and the self-expandable CoreValve™ device (Medtronic Inc., Minneapolis, MN,

USA). For both devices, basic approach to perform TAVI is femoral artery cannulation, insertion of the device through the aorta, and retrograde device implantation. Transfemoral vascular access combined with effective femoral artery puncture occlusion systems (e.g., Prostar XL™, Abbott Vascular) makes this procedure fully non-surgical. However, coexisting peripheral arterial disease, small femoral and/or iliac vessel diameter (< 6 mm) or concomitant aortic aneurysm render the transfemoral approach unusable in some patients. In these cases, alternative approaches have been used for many years (transapical approach for the Edwards SAPIEN device and left transsubclavian approach for the CoreValve device). These alternative approaches also have some limitations, such as bleeding, pseudoaneurysms, adverse ventricular remodeling, chronic postoperative pain and hindered respiratory rehabilitation with the transapical approach, while the left transsubclavian approach is not advisable in patients with functio-

Address for correspondence:

Zenon Huczek, MD, PhD, 1st Department of Cardiology, The Medical University of Warsaw, ul. Banacha 1A, 02–097 Warszawa, Poland, e-mail: zenon.huczek@wum.edu.pl

Received: 10.01.2012 Accepted: 22.02.2012

Copyright © Polskie Towarzystwo Kardiologiczne

ning left interior mammary artery graft, and it may pose significant technical problems in case of bleeding [6–8].

In this study, we report on two first TAVI procedures performed in Poland (on Jun 22, 2011, and Jul 01, 2011) using a novel approach directly through the ascending aorta (direct aortic access) for the implantation of both Edwards SAPIEN and CoreValve devices.

CASE REPORTS AND OPERATIVE TECHNIQUE

Procedures were performed under general anaesthesia in the cardiac catheterisation laboratory of the 1st Department of Cardiology, Medical University of Warsaw. Acetylsalicylic acid (ASA) (both patients) and clopidogrel (only CoreValve) were given for a minimum 5 days before the procedure at a dose of 75 mg/day. We also used standard antibiotic prophylaxis which was continued for 5 days after the procedure. At the beginning of the procedure, unfractionated heparin was given at 80 IU/kg to increase activated clotting time to 200–300 s. A pigtail angiography catheter was introduced through the right femoral artery. Intracavitary lead for rapid ventricular pacing during aortic valvuloplasty and bioprosthesis implantation, as well as treatment of potential postoperative conduction disturbances was inserted through a femoral vein into the right ventricle.

Case 1

A 73-year-old man with severe aortic stenosis (aortic valve area [AVA] 0.8 cm², Vmax 4.8 m/s, peak gradient 93 mm Hg, mean gradient 59 mm Hg, left ventricular ejection fraction [LVEF] 55%) and a history of New York Heart Association (NYHA) class II heart failure, empty sella syndrome, adrenocortical insufficiency, hypothyroidism, Eales disease (blindness of the left eye, impaired vision after vitrectomy in the right eye), chronic obstructive pulmonary disease, and chronic kidney disease. Due to a high risk of ophthalmologic complications in the right eye (history of recurrent vitreous haemorrhages) in case of dual antiplatelet therapy, the patient was selected for TAVI with the use of Edwards SAPIEN device, which may be managed with ASA only. The device had to be implanted using direct aortic access, as the size of the aortic annulus (25–26 mm by transoesophageal echocardiography and computed tomography [CT] angiography) precluded implantation using transfemoral approach.

Access to the ascending aorta was obtained by J-shaped partial upper sternotomy. Pericardial sac was open to visualise the distal portion of the ascending aorta. Using angiographic imaging, the distance between the aortic annular plane and the site of aortic puncture was measured. The exact site where the aortic wall was crossed with the device application system was chosen based on transoesophageal echocardiographic imaging combined with direct palpation of the ascending aorta and protected with two concentric pursestring sutures. Due to the length of the valvuloplasty balloon and the application sys-

tem sheath, this site should be located no less than 5 cm from the aortic annulus. Preoperative CT of the chest excluded extensive calcifications within the aortic wall. Aortic wall was punctured using the Seldinger technique, and the aortic valve was crossed with a stiff Amplatz Ultra Stiff™ guidewire, curved at the tip to minimise the risk of left ventricular (LV) wall perforation. Then, the Ascendra2 system sheath was introduced through the ascending aorta and the native valve was predilated using a Nucleus 22 × 40 mm balloon (NuMED Canada Inc.) during rapid cardiac pacing at 160 bpm. Finally, after precise positioning, an Edwards Sapien XT 29 mm valve was implanted. Of note, as the bioprosthesis valve is implanted using a retrograde approach, it must be crimped before mounting on the application system. Follow-up aortography showed an appropriate position of the bioprosthesis without valvular regurgitation. Mean transvalvular gradient was reduced to < 5 mm Hg. After removal of the Ascendra2 system, pursestring sutures on the aorta were tied with a very good haemostatic effect. The procedure concluded with insertion of mediastinal drainage and multiple layer suturing to close the sternotomy wound. Follow-up echocardiography showed good position of the bioprosthesis, with trace perivalvular regurgitation (1+) and no transvalvular gradient with the AVA of 1.5 cm². The patient was discharged home in a good clinical condition on the 12th day after the procedure. Another follow-up echocardiographic examination at 1 month confirmed normal function of the bioprosthesis. Vascular access and subsequent stages of the implantation procedure are shown in Figures 1 and 2.

Case 2

An 80-year-old man with severe aortic stenosis (AVA 0.6 cm², Vmax 4.5 m/s, peak gradient 80 mm Hg, mean gradient 46 mm Hg, LVEF 51%) and a history of NYHA class II heart failure, 3 previous inferior wall myocardial infarctions, percutaneous coronary intervention involving the left anterior descending artery and the marginal branch, paroxysmal atrial fibrillation, peripheral arterial disease (previous thrombendarterectomy of the right common femoral artery with profundoplasty and application of PTFE patch, occlusion of the left internal carotid artery), diabetes type 2, and chronic kidney disease. The size of the aortic annulus was measured at 26 mm by transoesophageal echocardiography and CT angiography. Due to concomitant peripheral arterial disease and a tortuous course of the left subclavian artery, the patient was selected for TAVI with the use of CoreValve device implanted through the ascending aorta.

In this case, aortic access was obtained by right anterior minithoracotomy with a 5 cm incision in the second intercostal space and preservation of the right internal mammary artery. The use of a small costal retractor allowed good visualisation of the anterior mediastinum and the ascending aorta after incision of the pericardial sac. Similarly to the first case, the distance between the aortic annular plane and the site of

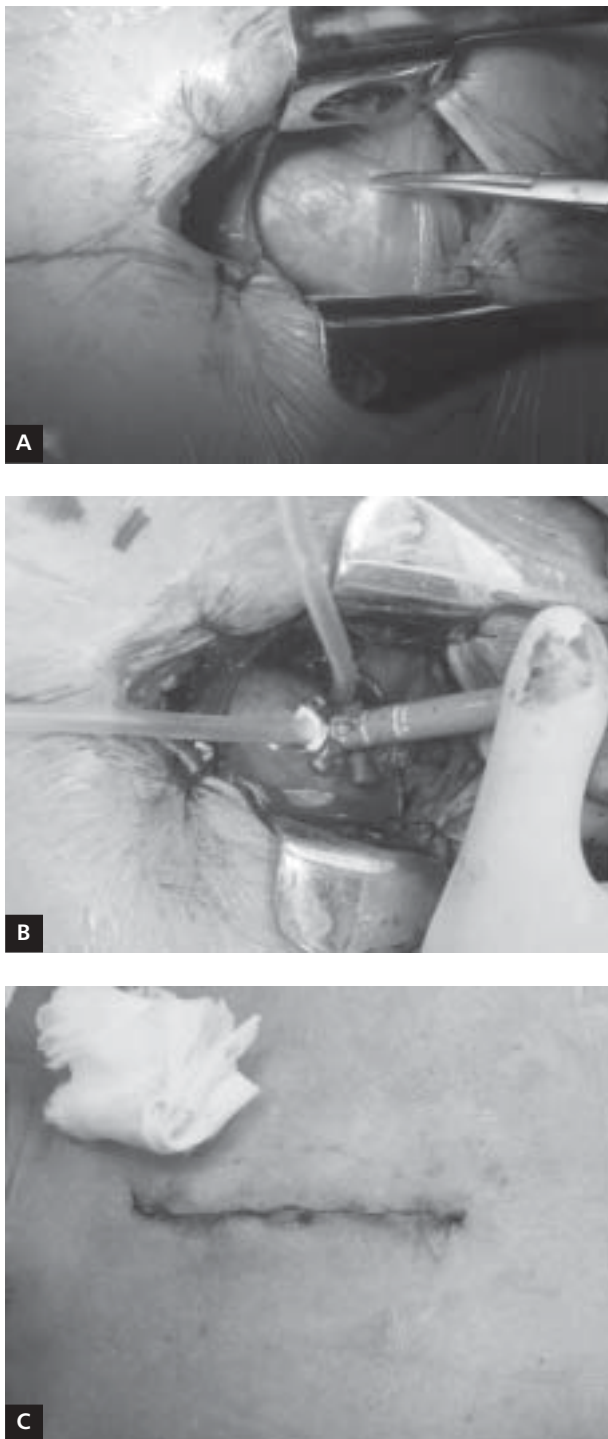


Figure 1. A. Ministernotomy and visualisation of the ascending aorta; B. Vascular sheath insertion into the ascending aorta, with the puncture site protected with two concentric purse-string sutures; C. Surgical wound

aortic puncture was measured using angiographic imaging. TAVI catheters were introduced using the Seldinger technique through the anterolateral aortic wall, and the puncture site was protected with two concentric pursestring sutures.

After predilatation of the native valve using a balloon catheter Nucleus 22 × 60 mm (NuMED Canada Inc.), a 29 mm self-expandable CoreValve bioprosthesis was implanted. Due to moderate perivalvular leak noted in follow-up angiography, the device was additionally expanded using a Z-Med 28 × 40 mm balloon. The application system was then removed, pursestring sutures on the aorta were tied with a very good haemostatic effect, right pleural drainage was inserted, and the procedure concluded with multiple layer suturing to close the ministhoracotomy wound. Follow-up echocardiography showed a moderate (2+) perivalvular regurgitation along the interventricular septum, peak gradient of 14 mm Hg, mean gradient of 6 mm Hg, and AVA of 1.4 cm². The patient was discharged home in a good clinical condition on the 15th day after the procedure. Another follow-up echocardiographic examination at 1 month confirmed normal function of the bioprosthesis. About 4 months later, due to evidence of the bradycardia-tachycardia syndrome in a follow-up Holter monitoring at 3 months and abortive Morgagni-Adams-Stokes attacks, a VVI pacemaker was implanted without complications. Vascular access and subsequent stages of the implantation procedure are shown in Figures 3 and 4.

DISCUSSION

Surgical AVR is currently the standard therapeutic approach in the management of severe aortic stenosis in patients at low to moderate surgical risk. However, perioperative mortality increases significantly in the elderly population with often impaired LV systolic function and numerous concomitant diseases [9]. It has been estimated that AVR is never contemplated in 30–40% of patients with high operative risk [10]. TAVI, which is less invasive and associated with less problematic rehabilitation following the procedure, has become more and more commonly used alternative therapeutic approach in patients at high surgical risk of AVR.

However, some questions regarding the choice of optimal vascular access for TAVI remain unanswered. Limitations of the transfemoral approach are mostly related to the size, course, and quality of femoral and iliac vessels. Manipulating the application system through the whole length of the systemic arterial system is always associated with a potential risk of dangerous complications which is reduced by shortening the intravascular access route. Similarly, a small diameter (< 6 mm), tortuous course or a significant stenosis of the left subclavian artery may preclude using this vessel as the access route. Performing TAVI with insertion of the device through the left subclavian artery is also relatively contraindicated in patients with patent left interior mammary artery graft. In addition, this approach may pose significant technical problems in case of bleeding [11].

The transapical approach, which offers the shortest anatomical route for aortic valve bioprosthesis implantation, also has some disadvantages. Every experienced cardiac surgeon

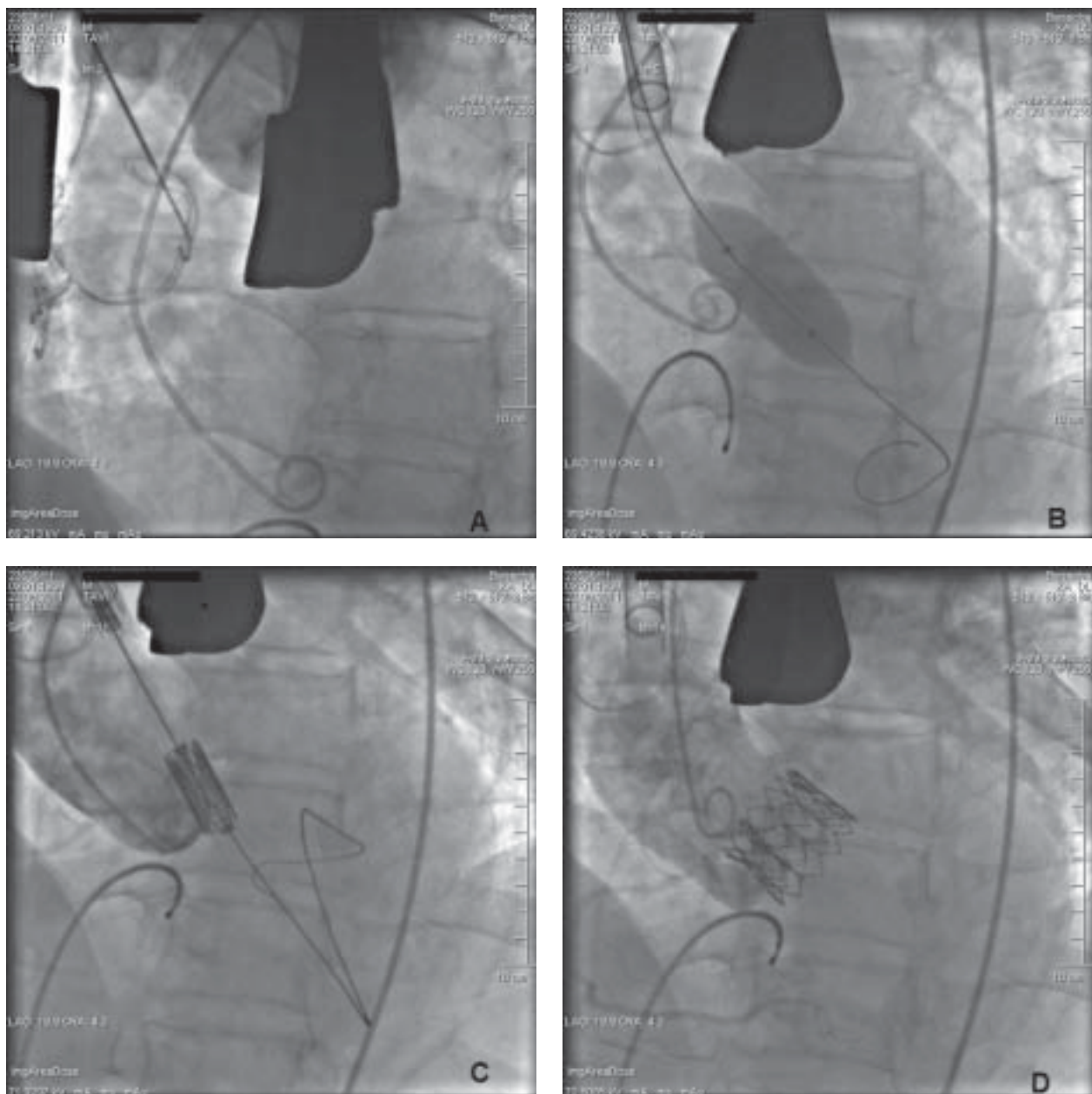


Figure 2. Subsequent stages of the implantation of the bioprosthesis — case 1; **A.** Puncture of the anterior aortic wall; **B.** Predilatation of the aortic annulus using a balloon catheter introduced with an Amplatz Ultra Stiff guidewire; **C.** Positioning of a 29 mm Edwards SAPIEN bioprosthesis; **D.** Final effect of the procedure — appropriately positioned and expanded bioprosthesis

will confirm that in the elderly patients, the quality of LV apical tissues is a critical factor affecting the risk of local surgical complications which may affect the final effects of the procedure in patients with high operative risk. It has been confirmed that such complications as LV apex perforation or rupture are associated with an increased periprocedural mortality [6]. Despite a reduction in size of the application systems (currently 22 F), complications related to apical cannulation occur in 2–6% of patients [6]. The transapical approach may be technically difficult in case of interventricular septal hy-

pertrophy, particularly if there is a significant kinking between the LV outflow tract and the proximal ascending aorta, with the presence of calcifications within the apex or the pericardial sac, and also in patients after previous LV myoplasty procedures. Despite preventive measures (e.g., use of rapid cardiac pacing to reduce tissue strain while tying apical purse-string sutures), LV apical bleeding continues to occur in 3–10% of patients [12]. A late complication is the development of apical pseudoaneurysm, rupture of which is associated with a 25% mortality risk due to cardiac tamponade [6, 7].

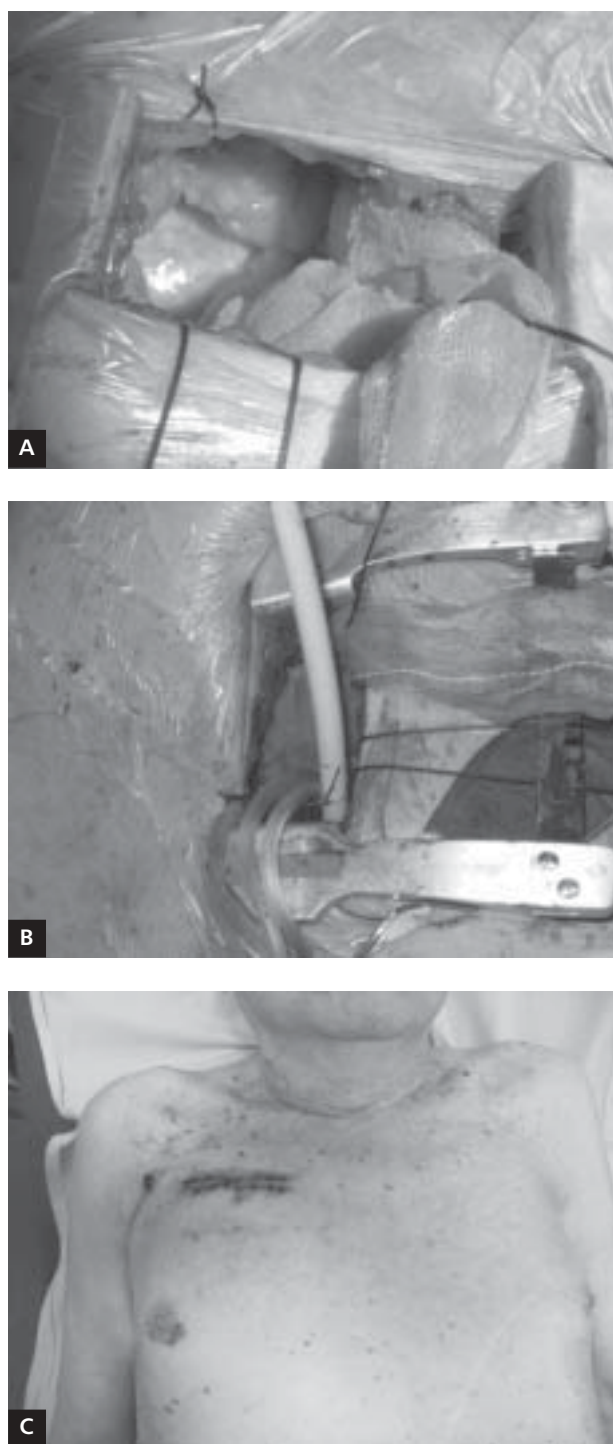


Figure 3. A. Right anterior minithoracotomy and visualisation of the ascending aorta; B. Vascular sheath inserted into the ascending aorta, with the puncture site protected with two concentric pursestring sutures; C. Surgical wound

The first to perform TAVI using the ascending aorta as the vascular access site were Bauernschmitt et al. [13] (Core-Valve device) and Bapat et al. [14] (Edwards SAPIEN device). Potential benefits of the direct aortic access are related to

a reduction in postoperative respiratory and bleeding complications [15, 16]. Preserved diaphragm functioning, no need to drain the left pleural cavity, and reduced postoperative pain contribute significantly to improved respiratory function. Direct aortic access should be considered in case of contraindications to anterolateral thoracotomy due to poor respiratory function ($FEV1/FVC < 70\%$ and $FEV1 < 60\%$ of the predicted value or $FEV1 < 1$ L) or poor LV systolic function ($LVEF < 20\%$). Achieving normal haemostasis at the site of TAVI system insertion (the same which is typically used for aortic cannulation before starting cardiopulmonary bypass) is easier compared to the transapical access. With poor quality of LV apex tissue, closing the cannulation site may be problematic, while even atherosclerotic aortic wall will not pose problems with haemostasis upon tying pursestring sutures. In patients with a very low LVEF, even small scar resulting from healed apical cannulation site or resolution of subepicardial periapical haematoma may lead to further postoperative reduction in LVEF. In such cases, direct aortic access may help preserve LV systolic function.

With direct aortic access, a small distance between the vascular sheath insertion site and the aortic valve itself allows easy procedural control, including when crossing the stenotic valve with an angioplasty guidewire, positioning a valvuloplasty balloon, and determining the appropriate position of the bioprosthesis within the aortic annulus. Partial sternotomy and good visualisation of the ascending aorta may also allow rapid conversion to full sternotomy with typical aortic cannulation for the purpose of instituting cardiopulmonary bypass should acute and life-threatening complications occur, such as coronary artery occlusion, migration of the bioprosthesis, or rupture of the aortic annulus.

Direct aortic access technique requires manipulations within the ascending aorta which may pose a potential risk of peripheral and central nervous system embolism. It seems, however, that the transfemoral approach, with its longer route from the vascular access site to the aortic annulus, may be associated with even higher embolic risk, particularly due to the fact that with that technique the application system is advanced through the aortic arch. Advanced atherosclerosis of the aorta (so-called porcelain aorta) is an obvious contraindication to TAVI using direct aortic access. However, even with diffuse calcifications within the aortic wall it is often possible to identify, using CT angiography or intraoperative transoesophageal echocardiography, a sufficiently large area within the anterior aortic wall that is free from atherosclerotic plaques and permits safe cannulation for the purpose of performing TAVI using this approach. Partial sternotomy may also allow use of the innominate artery as an alternative site of vascular access. Particular caution is necessary, however, in patients with previous coronary artery bypass grafting, in whom the right internal mammary artery used as a bypass graft runs superficial to the ascending aorta.

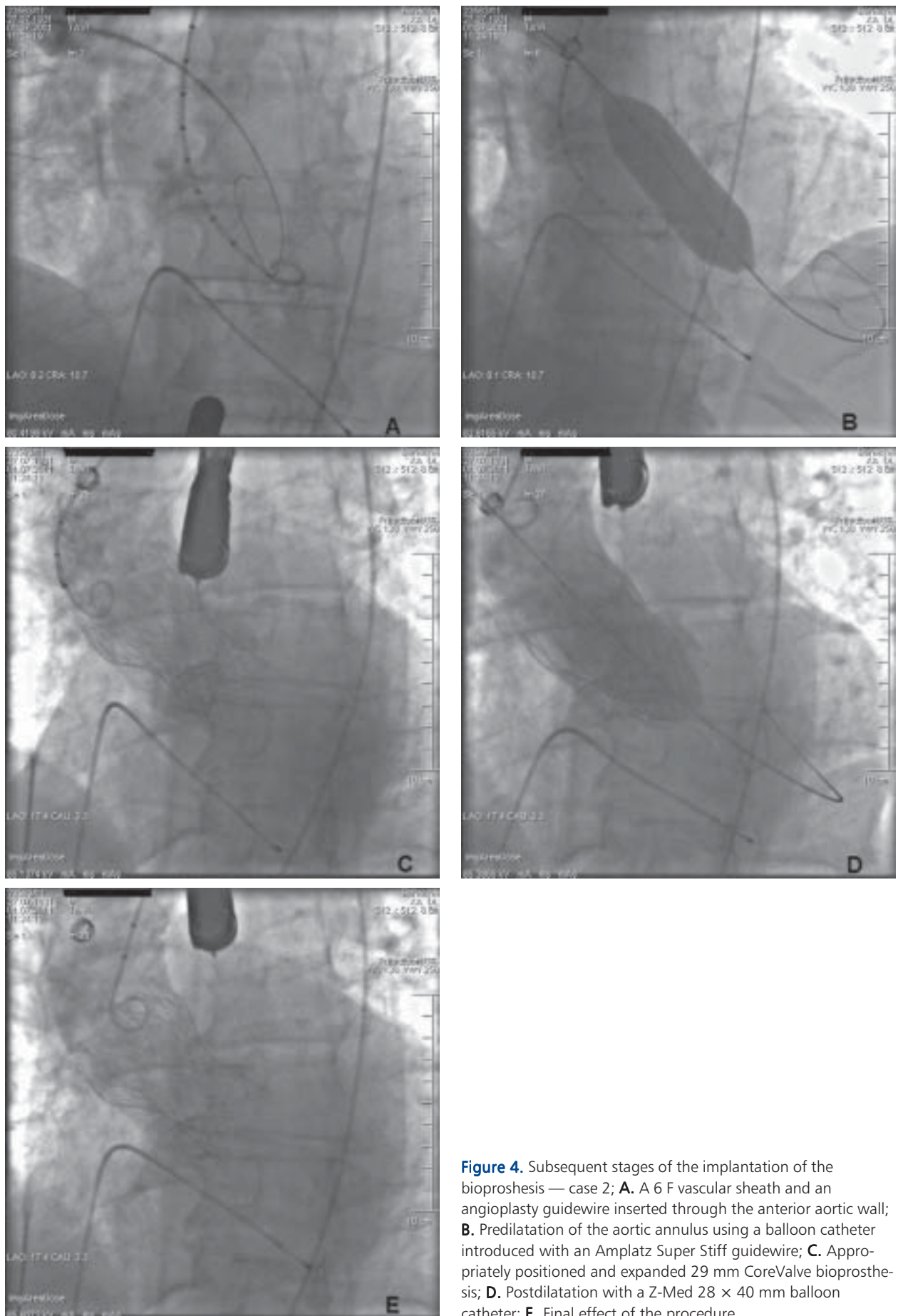


Figure 4. Subsequent stages of the implantation of the bioprosthesis — case 2; **A.** A 6 F vascular sheath and an angioplasty guidewire inserted through the anterior aortic wall; **B.** Predilatation of the aortic annulus using a balloon catheter introduced with an Amplatz Super Stiff guidewire; **C.** Appropriately positioned and expanded 29 mm CoreValve bioprosthesis; **D.** Postdilatation with a Z-Med 28 × 40 mm balloon catheter; **E.** Final effect of the procedure

European cardiology and cardiac surgery societies recommend performing TAVI procedures in dedicated hybrid operating rooms which combine advantages of a cardiac catheterisation laboratory (excellent angiographic visualisation and haemodynamic monitoring) and a surgical operating room (large space, laminar flow, high sterility level, and possibility of a rapid conversion to conventional AVR) [17]. These conditions allow for both high procedural effectiveness and patient safety and are particularly desirable in patients requiring surgical approach to perform TAVI (i.e., through the left subclavian artery, ventricular apex, or the ascending aorta). A short history of TAVI procedures in Poland combined with obvious logistic and financial considerations resulted in the fact that the reported procedures (and all other TAVI procedures performed in our centre in 2010 and 2011) were still performed in a conventional cardiac catheterisation laboratory with full cardiac surgical backup. Since early 2012, all TAVI procedures undertaken at the Medical University of Warsaw, including those attempted using true percutaneous transfemoral approach, will be performed in a dedicated hybrid operating room located within our cardiac surgical operating theatre.

SUMMARY

If performing TAVI via the transfemoral approach is not feasible, direct aortic access is a safe and effective alternative access route, particularly in view of potential limitations and complications of the transapical approach.

Acknowledgements

Authors thank Drs Vinayak Bapat and Giuseppe Bruschi for expert supervision and technical support during the first TAVI procedures performed via direct aortic access at the Medical University of Warsaw in June and July 2011. As far as we know, these were also the first TAVI procedures using direct aortic access performed in Poland.

Conflict of interest: none declared

References

- Zembala M, Wilczek K, Przybylski, et al. Raport POL-TAVIFIRST z zastosowania przezcewnikowej implantacji zastawki aortalnej typu Edwards-Sapien u pierwszych w Polsce 19 chorych z grupy bardzo dużego ryzyka, z ciężką stenozą aortalną i chorobami obciążającymi rokowanie. *Kardiologia Polska*, 2009; 67: 936–940.
- Witkowski A, Dąbrowski M, Chmielak Z et al. Transcatheter aortic valve implantation using transfemoral/transsubclavian or transapical approach: 30-day follow-up of the initial 30 patients. *Kardiologia Polska*, 2011; 69: 105–114.
- Kochman J, Huczek Z, Kołtowski Ł, Michalak M. Transcatheter implantation of an aortic valve prosthesis in a female patient with severe bicuspid aortic stenosis. *Eur Heart J*, 2012; 33: 112.
- Smith CR, Leon MB, Mack MJ et al. Transcatheter versus surgical aortic-valve replacement in high-risk patients. *N Engl J Med*, 2011; 364: 2187–2198.
- Leon MB, Smith CR, Mack MJ et al. Transcatheter aortic-valve implantation for aortic stenosis in patients who cannot undergo surgery. *N Engl J Med*, 2010; 363: 1597–1607.
- Al-Attar N, Ghodbane W, Himbert D et al. Unexpected complications of transapical aortic valve implantation. *Ann Thorac Surg*, 2009; 88: 90–94.
- Wong DR, Ye J, Cheung A et al. Technical considerations to avoid pitfalls during transapical aortic valve implantation. *J Thorac Cardiovasc Surg*, 2010; 140: 196–202.
- Chiara B, Lullo F, Paino R et al. The trans-subclavian retrograde approach for transcatheter aortic valve replacement: Single-center experience. *J Thorac Cardiovasc Surg*, 2010; 140: 911–915.
- Charlson E, Legedza AT, Hamel MB. Decision-making and outcomes in severe symptomatic aortic stenosis. *J Heart Valve Dis*, 2006; 15: 312–321.
- Iung B, Baron G, Butchart EG et al. A prospective survey of patients with valvular heart disease in Europe: The Euro Heart Survey on Valvular Heart Disease. *Eur Heart J*, 2003; 24: 1231–1243.
- da Gama Ribeiro V, Vouga L, Markowitz A et al. Vascular access in transcatheter aortic valve implantation. *Int J Cardiovasc Imag*, 2011; 27: 1235–1243.
- Dumont E, Rode's-Cabau J, de LaRochelliere R, Lemieux J, Villeneuve J, Doyle D. Rapid pacing technique for preventing ventricular tears during transapical aortic valve replacement. *J Cardiac Surg*, 2009; 24: 295–298.
- Bauernschmitt R, Schreiber C, Bleiziffer S et al. Transcatheter aortic valve implantation through the ascending aorta: an alternative option for no-access patients. *Heart Surg Forum*, 2009; 12: E63–E64.
- Bapat V, Thomas M, Hancock J, Wilson K. First successful transcatheter aortic valve implantation through ascending aorta using Edwards SAPIEN THV system. *Eur J Cardiothoracic Surg*, 2010; 38: 811–813.
- Brown ML, McKellar SH, Sundt TM, Schaff HV. Ministernotomy versus conventional sternotomy for aortic valve replacement: a systematic review and meta-analysis. *J Thorac Cardiovasc Surg*, 2009; 137: 670–679.e5.
- Mihaljevic T, Cohn L, Hnic D, Aranki SF, Couper GS, Byrne JG. One thousand minimally invasive valve operations. *Ann Surg*, 2004; 240: 529–534.
- Vahanian A, Alfieri O, Al-Attar N et al. Transcatheter valve implantation for patients with aortic stenosis: a position statement from the European Association of Cardio-Thoracic Surgery (EACTS) and the European Society of Cardiology (ESC), in collaboration with the European Association of Percutaneous Cardiovascular Interventions (EAPCI). *Eur Heart J*, 2008; 29: 1463–1470.

Przecewnikowa implantacja zastawki aortalnej z bezpośredniego dostępu aortalnego: pierwsze zabiegi w Polsce

Radosław Wilimski¹, Zenon Huczek², Wojciech Szczawiński¹, Arkadiusz Pietrasik², Marcin Michalak², Piotr Ścisło², Michał Marchel², Leopold Bakoń³, Krzysztof J. Filipiak², Romuald Cichoń¹, Grzegorz Opolski², Janusz Kochman²

¹Klinika Kardiologii, Warszawski Uniwersytet Medyczny, Warszawa

²I Klinika Kardiologii, Warszawski Uniwersytet Medyczny, Warszawa

³II Zakład Radiologii, Warszawski Uniwersytet Medyczny, Warszawa

Streszczenie

Przecewnikowa implantacja zastawki aortalnej (TAVI) jest alternatywną opcją terapeutyczną u pacjentów z ciężką stenozą zastawki aortalnej, charakteryzujących się wysokim ryzykiem klasycznej chirurgicznej wymiany zastawki. Dane z ostatnich badań randomizowanych wskazują na istotną redukcję śmiertelności u chorych nieoperacyjnych leczonych za pomocą TAVI w porównaniu z osobami leczonymi zachowawczo oraz na brak istotnych różnic w śmiertelności u pacjentów wysokiego ryzyka w porównaniu z klasycznym zabiegiem chirurgicznym.

Dostęp przezudowy jest obecnie najczęstszą i preferowaną drogą dostarczenia biologicznej protezy zastawki. Jednak mała średnica naczynia lub obecność istotnych zmian miażdżycowych w obrębie tętnic biodrowych i udowych wyklucza zastosowanie tej techniki. W niniejszej pracy przedstawiono doświadczenia własne dotyczące dwóch pierwszych w Polsce zabiegów TAVI wykonanych z bezpośredniego dostępu aortalnego.

Słowa kluczowe: TAVI, stenoza aortalna, bezpośredni dostęp aortalny

Kardiologia 2012; 70, 5: 486–493

Adres do korespondencji:

dr n. med. Zenon Huczek, I Klinika Kardiologii, Warszawski Uniwersytet Medyczny, ul. Banacha 1A, 02-097 Warszawa,
e-mail: zenon.huczek@wum.edu.pl

Praca wpłynęła: 10.01.2012 r. Zaakceptowana do druku: 22.02.2012 r.