

Mehmet Zahid Kocak<sup>1</sup>, Murat Araz, Mustafa Korkmaz, Aykut Demirkiran

Medical Oncology Department, Necmettin Erbakan University, Saraykoy, Selcuklu/Konya, Turkey

## Early-stage gastric cancer presenting with tripe palm and acanthosis nigricans

### Address for correspondence:

Dr. Mehmet Zahid Kocak, Assoc. Prof.  
Necmettin Erbakan University, Medical  
Oncology Department, Saraykoy, 42280  
Selcuklu/Konya, Turkey  
phone: +90 332 223 6821  
e-mail: mehmetzahidkocak@hotmail.com

Oncology in Clinical Practice  
2021, Vol. 17, No. 3, 132–134  
DOI: 10.5603/OCP.2021.0014  
Copyright © 2021 Via Medica  
ISSN 2450–1654  
e-ISSN 2450–6478

### ABSTRACT

Tripe palm is a rare cutaneous paraneoplastic syndrome that can be overlooked and frequently appears with acanthosis nigricans. If tripe palm and acanthosis nigricans occur in a patient together, gastric cancer should come to mind. A 50-year-old female patient had signs of abdominal pain and velvety thickening in the palms and soles. Tripe palm and acanthosis nigricans were considered as paraneoplastic syndrome after other benign causes were excluded. It was determined that the underlying malignancy was gastric cancer. After neoadjuvant FLOT chemotherapy regimen, gastrectomy was performed, and the patient received adjuvant chemotherapy. With the recognition of tripe palm, a rare cutaneous paraneoplastic syndrome, patients can be diagnosed and treated early.

**Key words:** tripe palm, acanthosis nigricans, gastric cancer, paraneoplastic syndrome

Oncol Clin Pract 2021; 17, 3: 132–134

### Introduction

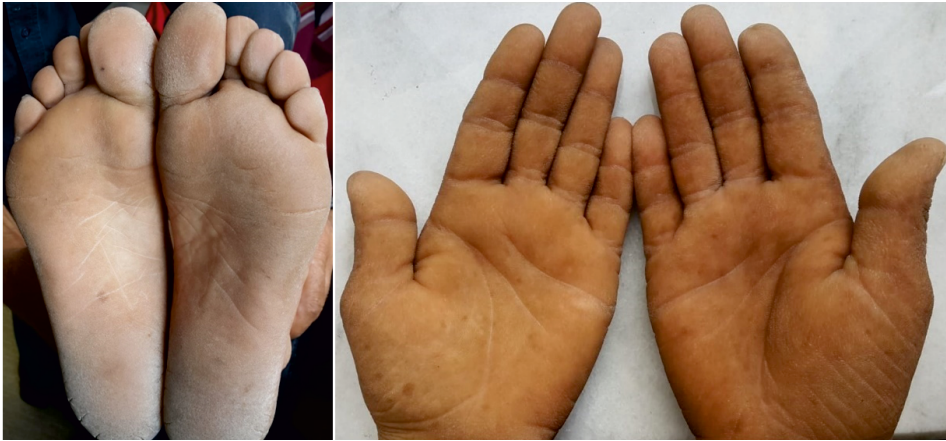Although the incidence of gastric cancer is decreasing worldwide, it is the 5<sup>th</sup> most common neoplasm and the 3<sup>rd</sup> most common cause of cancer death [1]. Gastric cancer is histologically divided into two groups as intestinal and diffuse type. The first one (intestinal) is well-differentiated type and it is the more common. Its prognosis is better [2]. The diffuse type has a worse prognosis and is diagnosed more frequently in women [2]. Neoadjuvant FLOT regimen (docetaxel, oxaliplatin, leucovorin and fluorouracil) is the standard therapy in the treatment of early stage (from Stage 1b) gastric cancer [3]. Detecting gastric cancer at an early stage is very important for overall survival. Several malignant diseases may be detected at an early stage with the diagnosis of paraneoplastic syndromes. Various skin findings herald the presence of an underlying malignancy. These skin evidence may be paraneoplastic signs such as Leser-Trelat, tripe palm and acanthosis nigricans [4]. Tripe palm is velvety hyperkeratosis of the palmar hands resembling the bovine stomach. Tripe palm is reported to be associated with malignancy and may occur especially together with acanthosis nigricans. Tripe

palm occurs before or concurrently with the cancer diagnosis of patients [5]. When tripe palm occurs with acanthosis nigricans, gastric carcinoma is the most common malignancy. If tripe palm occurs alone, it is most often suggestive of pulmonary carcinoma [5, 6].

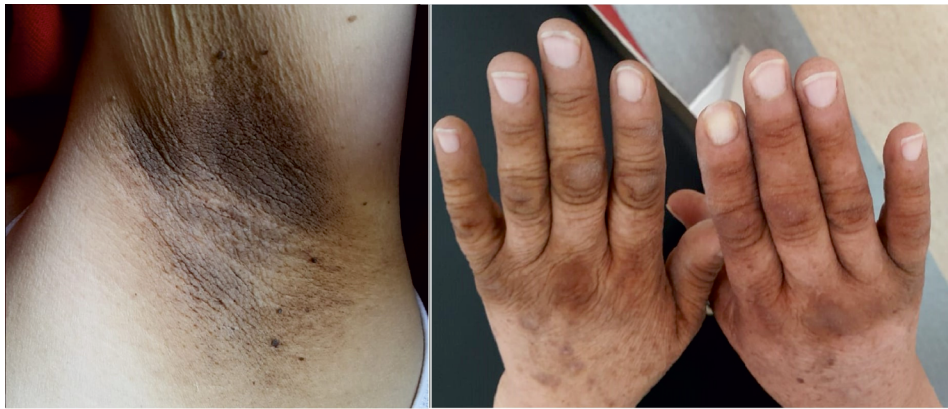We aimed to present a case of early-stage gastric cancer presenting with rare tripe palm and acanthosis nigricans.

### Case report

A 50-year-old woman presented with a 2-month history of abdominal pain and a 3-week history of hyperpigmentation in the armpits, knees, joints of the fingers and toes. She used a proton pump inhibitor because of abdominal pain. The other medical history was unremarkable. Family history was unremarkable. Vital signs were stable. Physical examination of the palms of her hands and soles revealed velvety appearance, thickened, moss-like, corrugated surface resembling tripe (Fig. 1). Hyperpigmentation in the nape, armpit, knee, joints of the fingers and toes was considered as acanthosis nigricans (Fig. 2). There was

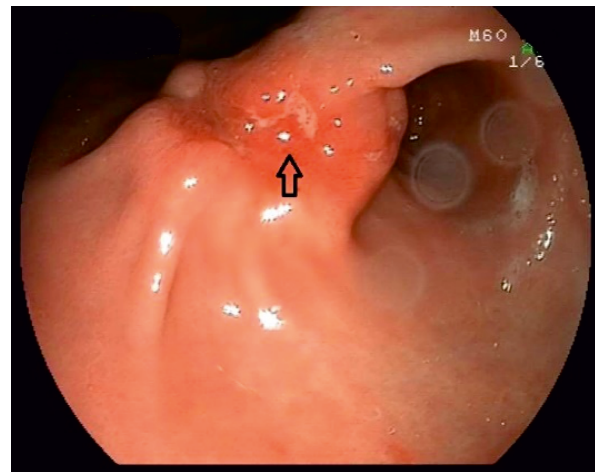


**Figure 1.** A rugose appearance with a ridged surface, mimicking the tripe of a ruminant, on the palms and soles



**Figure 2.** Hyperpigmentation of skinfolds (acanthosis nigricans) on the armpit and fingers

no abnormal value in the laboratory analysis. Abdominal ultrasonography was performed and there was no additional abnormality except grade 2 hepatosteatosis. The presence of tripe palm and acanthosis nigricans in our patient suggested malignancy. Gastroduodenoscopy was performed. Malignant ulcer was detected in the stomach (antrum) (Fig. 3) and biopsy was taken. The result showed gastric adenocarcinoma. Thoracic and abdominal computed tomography was performed for cancer staging. Stomach wall thickness increased and there were no distant metastases. Neoadjuvant chemotherapy in form of FLOT regimen was initiated because of the diagnosis of early-stage gastric cancer. Paraneoplastic tripe palm and acanthosis nigricans regressed. There was a slight decrease in gastric wall thickness after 4 cycles (detected in computed tomography of the abdomen). Total gastrectomy and D2 lymph node dissection were performed. Postoperative pathology report revealed adenocarcinoma. The same chemotherapy regimen was started again in the postoperative 8<sup>th</sup> week and 4 cycles were given. Paraneoplastic tripe palm and acanthosis nigricans completely disappeared. The patient was observed with no evidence of progressive disease.



**Figure 3.** Malignant ulcer in the stomach antrum incisura angularis in gastroduodenoscopy

## Discussion

Paraneoplastic syndromes are a group of pathological conditions caused by neoplasia that do not occur with

metastatic spread or local infiltration. Cutaneous paraneoplastic syndromes are non-adjacent skin and mucous membrane changes. The cause for the occurrence of cutaneous manifestations of gastric cancer may be the production of growth factors, hormones, peptides, or exhausting of various substances [7]. Successful treatment of gastric cancer, as in our case, often leads to disappearance of paraneoplastic dermatoses. Among many cutaneous paraneoplastic syndromes described tripe palm is defined by velvety thickening of the palms and soles and resembles the rugose stomach mucosa (tripe) of ruminants. In our case, it was present in both the palm and the soles. TGF- $\alpha$ , receptor tyrosine kinases, and oncogenes SRC may implicate in tripe palm pathogenesis [7]. Tripe palm presents before cancer diagnosis in approximately 40% of patients [8]. Tripe palm is particularly associated with 90% solid tumors such as stomach or lung cancer and 30% of tripe palm responds to cancer treatment [7, 8]. Tripe palm disappeared with treatment in our case. Tripe palm can occur with acanthosis nigricans (72%), florid cutaneous papillomatosis (30%), and the sign of Leser-Trelat (10%) [5]. If acanthosis nigricans occurs with tripe palms, gastric carcinoma is the most common malignancy, but if acanthosis nigricans is absent, pulmonary carcinoma is most frequent [5, 6]. In our case, tripe palm was seen together with acanthosis nigricans and the underlying malignancy was gastric adenocarcinoma. Acanthosis nigricans is a cutaneous marker of cancers; it typically displays hyperpigmented, roughened plaques of velvety and usually occurs in the intertriginous zones (neck, axilla, and groin). Acanthosis nigricans may also occur in familial or drug-induced and autoimmune diseases, diabetes mellitus, obesity, insulin resistance, and polycystic ovarian disease. Acanthosis nigricans occurs frequently in gastric cancer, but it may appeared in liver, lung, ovarian, kidney, and breast cancers [7, 9]. In our case, acanthosis nigricans was seen in the axilla, neck and groin and regressed with treatment.

The importance of paraneoplastic syndromes was emphasized with this case. With the diagnosis of paraneoplastic syndrome, cancer with high mortality was diagnosed at an early stage and cured. Tripe palm and acanthosis nigricans are rare paraneoplastic syndrome. Physician with awareness of these skin signs, will diagnose and treatment patients earlier with probably lifesaving outcomes.

## Conflict of interest

The authors report no conflicts of interest.

## References

1. Bray F, Ferlay J, Soerjomataram I, et al. Global cancer statistics 2018: GLOBOCAN estimates of incidence and mortality worldwide for 36 cancers in 185 countries. *CA Cancer J Clin.* 2018; 68(6): 394–424, doi: [10.3322/caac.21492](https://doi.org/10.3322/caac.21492), indexed in Pubmed: [30207593](https://pubmed.ncbi.nlm.nih.gov/30207593/).
2. Chon HJ, Hyung WJ, Kim C, et al. Differential Prognostic Implications of Gastric Signet Ring Cell Carcinoma: Stage Adjusted Analysis From a Single High-volume Center in Asia. *Ann Surg.* 2017; 265(5): 946–953, doi: [10.1097/SLA.0000000000001793](https://doi.org/10.1097/SLA.0000000000001793), indexed in Pubmed: [27232252](https://pubmed.ncbi.nlm.nih.gov/27232252/).
3. Al-Batran SE, Homann N, Pauligk C, et al. Perioperative chemotherapy with fluorouracil plus leucovorin, oxaliplatin, and docetaxel versus fluorouracil or capecitabine plus cisplatin and epirubicin for locally advanced, resectable gastric or gastro-oesophageal junction adenocarcinoma (FLOT4): a randomised, phase 2/3 trial. *The Lancet.* 2019; 393(10184): 1948–1957, doi: [10.1016/s0140-6736\(18\)32557-1](https://doi.org/10.1016/s0140-6736(18)32557-1).
4. Schadt CR. The cutaneous manifestations of gastrointestinal malignancy. *Semin Oncol.* 2016; 43(3): 341–346, doi: [10.1053/j.seminoncol.2016.02.028](https://doi.org/10.1053/j.seminoncol.2016.02.028), indexed in Pubmed: [27178686](https://pubmed.ncbi.nlm.nih.gov/27178686/).
5. Cohen P, Grossman M, Silvers D, et al. Tripe palms and cancer. *Clinics in Dermatology.* 1993; 11(1): 165–173, doi: [10.1016/0738-081x\(93\)90114-r](https://doi.org/10.1016/0738-081x(93)90114-r).
6. Gheeraert P, Goens J, Schwartz RA, et al. Florid cutaneous papillomatosis, malignant acanthosis nigricans, and pulmonary squamous cell carcinoma. *Int J Dermatol.* 1991; 30(3): 193–197, doi: [10.1111/j.1365-4362.1991.tb03850.x](https://doi.org/10.1111/j.1365-4362.1991.tb03850.x), indexed in Pubmed: [2037404](https://pubmed.ncbi.nlm.nih.gov/2037404/).
7. Ehst BD, Minzer-Conzetti K, Swerdlin A, et al. Cutaneous manifestations of internal malignancy. *Curr Probl Surg.* 2010; 47(5): 384–445, doi: [10.1067/j.cpsurg.2010.01.003](https://doi.org/10.1067/j.cpsurg.2010.01.003), indexed in Pubmed: [20363406](https://pubmed.ncbi.nlm.nih.gov/20363406/).
8. Cohen PR, Grossman ME, Almeida L, et al. Tripe palms and malignancy. *J Clin Oncol.* 1989; 7(5): 669–678, doi: [10.1200/JCO.1989.7.5.669](https://doi.org/10.1200/JCO.1989.7.5.669), indexed in Pubmed: [2651581](https://pubmed.ncbi.nlm.nih.gov/2651581/).
9. Thiers BH, Sahn RE, Callen JP. Cutaneous manifestations of internal malignancy. *CA Cancer J Clin.* 2009; 59(2): 73–98, doi: [10.3322/caac.20005](https://doi.org/10.3322/caac.20005), indexed in Pubmed: [19258446](https://pubmed.ncbi.nlm.nih.gov/19258446/).