

## Tomasz Sachański<sup>1</sup>, Maciej Miodoński<sup>1</sup>, Barbara Radecka<sup>2,3</sup>

<sup>1</sup>Department of Surgical Oncology with Breast Surgery Unit, Tadeusz Koszarowski Cancer Center in Opole, Poland

<sup>2</sup>Department of Oncology, Institute of Medical Sciences, University of Opole, Poland

<sup>3</sup>Department of Clinical Oncology, Tadeusz Koszarowski Cancer Center in Opole, Poland

# Invasive breast cancer in ectopic axillary breast tissue — case report

### Address for correspondence:

Lek. Tomasz Sachański  
Opolskie Centrum Onkologii  
ul. Katowicka 66a, 45-061 Opole  
Tel: 606 898 677  
+48 77 441 6073  
e-mail: saszk73@gmail.com

### ABSTRACT

Breast cancer is the most commonly diagnosed malignancy in women in Poland. Rare, unusual forms of breast cancer remain a diagnostic problem. The incidence of ectopic breast glandular tissue in the general population varies between 0.4 and 6%. The same abnormalities and diseases as in the anatomical mammary gland may develop in this tissue. Breast cancer may develop as well.

We present the case of a 36-year-old woman, who went to the doctor because of a nodule in the right armpit presented for 2 years. The patient was referred to a surgeon with suspicion of an epidermal cyst. The lesion was surgically removed and in the histopathological examination, the diagnose was: invasive breast cancer in ectopic glandular tissue. After imaging diagnostics, discussion of a multidisciplinary diagnostic and therapeutic team, the patient was offered a surgical procedure - widening of the excision margins to obtain oncological completeness and axillary lymphadenectomy. After the surgery, due to the results of the histopathological examination, complementary systemic treatment (chemo- and hormone therapy) and radiotherapy were used.

Doctors often do not consider the possibility of primary breast cancer occurring elsewhere than in the breast. Breast imaging does not always make it possible to diagnose the disease, and doctors performing and interpreting these tests often do not include primary armpit cancer in the differential diagnosis. This can cause a delay in diagnosis and worsen the prognosis.

**Key words:** rare cases of breast cancer, ectopic glandular tissue, additional breast, axillary tumor

Oncology in Clinical Practice  
2021, Vol. 17, No. 1, 42–45  
DOI: 10.5603/OCP.2020.0025  
Translation: lek. Maciej Miodoński  
Copyright © 2021 Via Medica  
ISSN 2450-1654

Oncol Clin Pract 2021; 17, 1: 42–45

## Introduction

Breast cancer is the most commonly diagnosed malignancy in women in Poland. It is also one of the biggest threats to the premature mortality of women [1]. The growing awareness of doctors of various specialties not only oncologists, allows more and more often to detect this disease at an early stage, also preclinical. Rare, unusual forms of breast cancer remain a diagnostic problem.

Ectopic breast glandular tissue occurs between 0.4 and 6% of the general human population [2]. Its presence is a consequence of the incomplete disappearance of the so-called mammary crests (*cretae mammae*) [3]. Such remaining additional glandular tissue is most often located within the axillary pits, but other locations, such as supra and subclavian region, subcutaneous region, and even anatomically distant locations such as perineum and anus are possible [4].

In such an additional gland, abnormalities and diseases characteristic of the anatomical mammary gland may occur. Cases of adenomas, fibro-cystic lesions, as well as breast cancer are reported [5]. Typically, the patient is not aware of the presence of such an incorrectly located additional glandular tissue until a palpable tumor is found, for example in the armpit.

## A case report

A 36-year-old woman, without a significant medical history, was referred by a primary care physician to a general surgeon because of a nodule in the soft tissues of her right armpit for more than 2 years. The lesion has increased over the past few months. Due to the incriminating family history (mother's sister had breast cancer), the patient regularly checked her breasts during gynecological visits. Periodically performed breast ultra-

sound showed no abnormalities. The consulting surgeon found the relative movable tumor with a diameter of 2 cm and redness of the skin above it. The ultrasound examination of the armpit described a hypoechoic, irregular focal lesion with a diameter of 21 mm, involving skin and subcutaneous tissue, as well as, lymph nodes up to 8 mm in diameter next to the principal lesion. There was suspicion of the inflammatory epidermal cyst or inverted acne (*hidradenitis suppurativa*). The lesion was surgically removed.

In histopathological report, invasive cancer of special type (NST) with intermediate grade (G2) was identified, with the presence of angio- and neuro-invasion. The pathologist described the weaving of cancer in the dermis and subcutaneous tissue, and in the vicinity, structures corresponding to the residual weaving of the mammary gland. In summary, it was found that the whole picture corresponds to primary cancer originating from ectopic breast glandular tissue. Along with the major lesion, 4 lymph nodes were removed, in which metastatic lesions up to 3 mm in diameter were found with infiltration outside the lymph node capsule. The degree of pathomorphological severity was defined as pT1cN2a. In immunohistochemistry, the strong expression of estrogen and progesterone receptors, lack of HER2 receptor expression, and Ki67 proliferation index of about 30% were found. The cancer phenotype was defined as luminous B HER2 negative.

After diagnosis, the patient was referred to the Opole Oncology Center, where spectral mammography, chest X-ray and abdominal ultrasound were performed.

In spectral mammography (Fig. 1 and 2) no pathological strengthening foci were found both in breasts and axillary pits (the study was performed after a diagnostic excision). The results of the chest and abdominal imaging were normal. The patient's case was discussed during a multidisciplinary diagnostic and therapeutic team meeting. Due to the presence of cancer stuck to the edges of the surgical incision of the removed lesion and metastases to four lymph nodes with infiltration outside the node capsule, the patient was offered the surgery at first - widening the excision of the lesion with the removal of right axillary lymph nodes. In the pathomorphological examination of the postoperative material, the edges of the preparation were free of neoplastic lesions. There were found postoperative resorptive changes and ductal carcinoma in situ (DCIS) with an intermediate degree of differentiation present in individual ducts in the lodge area. In four of the twelve lymph nodes assessed, metastases of cancer up to 6 mm in diameter with infiltration outside the lymph node capsule were found. After surgery, the patient was offered complimentary treatment as part of a multidisciplinary medical consultation. Chemotherapy based on anthracyclines and taxoids was used, and then, according to the expression of steroid hormone receptors, pharmacological ovarian suppression and treatment with nonsteroidal aromatase inhibitors were included. The patient was also subjected to additional radiation therapy. The breast was irradiated together with the nodal field up to a dose of 50 Gy in 25 fractions with an additional dose of 10 Gy in 5 fractions after the tumor resection using 3D conformal radiotherapy with intensity-modulated radiation therapy (IMRT).

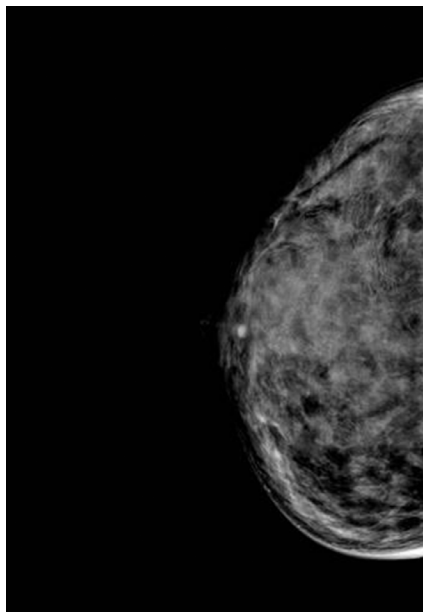


Figure 1. Contrast — enhanced spectral mammography of the right breast

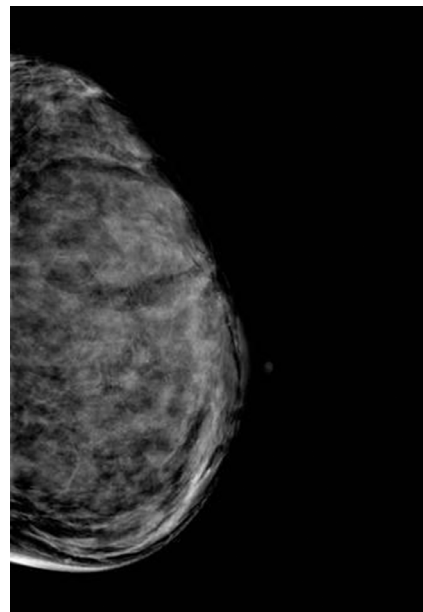


Figure 2. Contrast — enhanced spectral mammography of the left breast

## Discussion

In case of a palpable tumor in the armpit, the most often taken into account are enlarged lymph nodes, which have been changed, reacted with inflammation or cancer. In differential, diagnostics should be considered such conditions as inflammation (abscess, boil, lipoma, inverted acne), epidermal cyst, as well as soft tissue tumors or peripheral nerve sheaths tumors [6, 7].

We should also remember about the possibility of ectopic breast glandular tissue. In terms of histological structure, one can distinguish an additional (supernumerary) breast and aberrant breast tissue [8]. Additional breasts most often occur in place of embryonic nipple combs, so-called "milky line" from armpits to the groin. The glandular structures of such an additional breast are ordered, with a secretory system, as well as with the possibility of an additional wart and areola. In the breast tissue of the split breast, the glandular structures are chaotic, with no ordered secretory system. They are usually located near the anatomical breast as an "islands" of glandular tissue [8].

Extrapodial glandular tissue undergoes changes under the influence of hormones, analogously to the anatomical mammary gland. It may develop various abnormalities and diseases such as fibro-cystic lesions, adenomas, papillomas, as well as breast cancers [9]. According to various authors, the incidence of breast cancer in ectopic breast glandular tissue accounts for 0.2 to 0.6% of all breast cancers [5]. Because of the rarity of the disease, doctors often do not consider the possibility of primary breast cancer outside the anatomical mammary gland. Imaging breast examinations do not always make it possible to diagnose the disease. This can cause a significant delay in diagnosis and worsen the prognosis.

The treatment of cancer in the ectopic breast glandular tissue within the armpit is generally subject to the same principles as the treatment of cancer of the anatomically located breast. However, some issues remain controversial, especially regarding the extent of surgical treatment. Some authors suggest mastectomy on the same side as the tumor in the ectopic tissue if the axillary lymph nodes are involved [10, 11]. Others argue that removal of the anatomical breast does not bring additional benefits to patients, and the prognosis is the same for local, radical removal of ectopic tissue and amputation [12, 13]. Therefore, the surgical treatment of choice is a wide excision of the lesion with surrounding tissues (including skin). Mastectomy is not indicated if breast imaging does not indicate cancer within it. However, it should be considered if the results of imaging tests are not clear and differential diagnosis does not allow for a reliable diagnosis [14].

In case of a primary lesion located in the ectopic tissue of the breast and clinically unchanged regional lymph nodes (which was not the case in this patient), lymph node surgery is necessary. Does sentinel node biopsy make sense in this case? Some authors show that metastases in axillary lymph nodes occurred in about 50% of the analyzed cases, and therefore very often, which could suggest the legitimacy of lymphadenectomy in such a situation [4, 10, 11]. However, several published papers indicate that lymphoscintigraphy allows accurate localization of sentinel lymph nodes. Therefore, it is possible to perform a sentinel node biopsy procedure and to avoid mutilating lymphadenectomy [16, 17]. This approach is particularly justified in cases of ectopic tissue location outside the armpit, where the absorbent flow down to the armpit on the same side is not obvious [17]. The choice of the site for radioisotope injection remains a technical issue. Will the retroareolar injection on the same side as the axillary tumor be appropriate? Considering lymphatic drainage and axillary location, it appears that peritumoral or surgical site biopsy is more appropriate in this case [17].

The scope of complementary radiotherapy also raises some controversy. Due to the rarity of this form of cancer, there is no clearly defined standard of treatment. Most authors suggest qualifying patients for complementary radiotherapy based on similar criteria as in the case of breast cancer in a typical location. There are differences regarding the scope of radiotherapy. Some authors consider it appropriate to irradiate the lodge after the removed tumor and axillary pit, others suggest covering the breast on the tumor side [18].

Systemic adjuvant treatment should be carried out in accordance with generally accepted recommendations for the treatment of patients with early breast cancer.

In the presented case, after a discussion within the multidisciplinary diagnostic and therapeutic team, a decision was made on supplementary radiotherapy for the lodge after the removed tumor and the armpit due to the involved lymph nodes and skin infiltration. Systemic treatment was adapted to cancer biology and the degree of pathomorphological severity.

## Conclusions

Ectopic breast glandular tissue is often not included in routine mammography. Also, some physicians performing breast ultrasound examination do not take into account the possibility of cancer in the ectopic breast gland tissue. This causes delays in the diagnosis and treatment of additional breast cancer.

## Conflict of interest

The authors report no conflicts of interest.

## References

1. Jeziorski A, Rutkowski P, Wysocki W, et al. *Chirurgia onkologiczna t. 1*. PZWL, Warszawa. 2018: 19–20.
2. Gabriel A, Maxwell G. Breast embryology. 2018, <http://emedicine.medscape.com/article/1275146-overview>.
3. Shunke M, Schulte E, et al. *Atlas Anatomii człowieka t. 1*. Prometeusz, Wrocław 2009.
4. Marshall MB, Moynihan JJ, Frost A, et al. Ectopic breast cancer: case report and literature review. *Surg Oncol*. 1994; 3(5): 295–304, doi: [10.1016/0960-7404\(94\)90032-9](https://doi.org/10.1016/0960-7404(94)90032-9), indexed in Pubmed: [7889223](https://pubmed.ncbi.nlm.nih.gov/7889223/).
5. Francone E, Nathan MJ, Murelli F, et al. Ectopic breast cancer: case report and review of the literature. *Aesthetic Plast Surg*. 2013; 37(4): 746–749, doi: [10.1007/s00266-013-0125-1](https://doi.org/10.1007/s00266-013-0125-1), indexed in Pubmed: [23620009](https://pubmed.ncbi.nlm.nih.gov/23620009/).
6. Kokot F, et al. Diagnostyka różnicowa objawów chorobowych. *Wyd. 3*. PZWL, Warszawa. 2007: 528–530.
7. Aymen F, Atef Y, Majed G, et al. Axillary Masse, is it an Ectopic Mammary Gland? *Breast Cancer: Current Research*. 2016; 1(2): 108, doi: [10.4172/2572-4118.1000108](https://doi.org/10.4172/2572-4118.1000108).
8. Georgiade NG, Georgiade GS, Riefkohl R, et al. *The breast: embryology, anatomy, and physiology*, Philadelphia: WB Saunders. 1990: 3–17.
9. Velanovich V. Ectopic breast tissue, supernumerary breasts, and supernumerary nipples. *South Med J*. 1995; 88(9): 903–906, doi: [10.1097/00007611-199509000-00002](https://doi.org/10.1097/00007611-199509000-00002), indexed in Pubmed: [7660204](https://pubmed.ncbi.nlm.nih.gov/7660204/).
10. Matsuoka H, Ueo H, Kuwano H, et al. [A case of carcinoma originating from accessory breast tissue of the axilla]. *Gan No Rinsho*. 1984; 30(4): 387–391, indexed in Pubmed: [6727040](https://pubmed.ncbi.nlm.nih.gov/6727040/).
11. Visconti G, Eltahir Y, Van Ginkel RJ, et al. Approach and management of primary ectopic breast carcinoma in the axilla: where are we? A comprehensive historical literature review. *J Plast Reconstr Aesthet Surg*. 2011; 64(1): e1–11, doi: [10.1016/j.bjps.2010.08.015](https://doi.org/10.1016/j.bjps.2010.08.015), indexed in Pubmed: [20934398](https://pubmed.ncbi.nlm.nih.gov/20934398/).
12. Tjalma WAA, Senten LLC. The management of ectopic breast cancer — case report. *Eur J Gynaecol Oncol*. 2006; 27(4): 414–416, indexed in Pubmed: [17009640](https://pubmed.ncbi.nlm.nih.gov/17009640/).
13. Cogswell HD, Czerny EW. Carcinoma of aberrant breast of the axilla. *Am Surg*. 1961; 27: 388–390, indexed in Pubmed: [13694314](https://pubmed.ncbi.nlm.nih.gov/13694314/).
14. Evans DM, Guyton DP. Carcinoma of the axillary breast. *J Surg Oncol*. 1995; 59(3): 190–195, doi: [10.1002/jso.2930590311](https://doi.org/10.1002/jso.2930590311), indexed in Pubmed: [7609527](https://pubmed.ncbi.nlm.nih.gov/7609527/).
15. Zhang S, Yu YH, Qu W, et al. Diagnosis and treatment of accessory breast cancer in 11 patients. *Oncol Lett*. 2015; 10(3): 1783–1788, doi: [10.3892/ol.2015.3388](https://doi.org/10.3892/ol.2015.3388), indexed in Pubmed: [26622750](https://pubmed.ncbi.nlm.nih.gov/26622750/).
16. Thorne AL, Jackson A, Yiangou C. The use of sentinel node biopsy in the treatment of cancer of an accessory breast. *Breast*. 2003; 12(2): 153–155, doi: [10.1016/s0960-9776\(02\)00266-7](https://doi.org/10.1016/s0960-9776(02)00266-7), indexed in Pubmed: [14659346](https://pubmed.ncbi.nlm.nih.gov/14659346/).
17. Gentilini O, Paganelli G, Trifiro G, et al. Sentinel node biopsy in ectopic breast cancer. *Nucl Med Commun*. 2003; 24(11): 1127–1128, doi: [10.1097/01.mnm.0000101603.64255.5f](https://doi.org/10.1097/01.mnm.0000101603.64255.5f), indexed in Pubmed: [14569165](https://pubmed.ncbi.nlm.nih.gov/14569165/).
18. Routiot T, Marchal C, Verhaeghe JL, et al. Breast carcinoma located in ectopic breast tissue: a case report and review of the literature. *Oncol Rep*. 1998; 5(2): 413–417, doi: [10.3892/or.5.2.413](https://doi.org/10.3892/or.5.2.413), indexed in Pubmed: [9468570](https://pubmed.ncbi.nlm.nih.gov/9468570/).