

**Ashley J.R. De Bie^{1*}, Simon Körver^{2*}, Erik Kersten³, Jérôme M.H. Kisters¹,
Henricus J.E.J. Vrijhof⁴, Jeroen Willems¹**

¹Department of Internal Medicine, Catharina Hospital Eindhoven, Eindhoven, The Netherlands

²Department of Endocrinology and Metabolism, Academic Medical Centre, Amsterdam, The Netherlands

³Department of Radiology, Catharina Hospital Eindhoven, Eindhoven, The Netherlands

⁴Department of Urology, Catharina Hospital Eindhoven, Eindhoven, The Netherlands

*Authors contributed equally

A paraplegic patient with fever and leucocytosis: not always what it seems

Address for correspondence:

Ashley J.R. De Bie, MD
 Catharina Hospital Eindhoven
 Department of Internal Medicine,
 Catharina Hospital Eindhoven
 Address: Michelangelolaan 2,
 5623 EJ Eindhoven
 Phone: 003140 239 9111
 e-mail:
 ashley.d.bie@catharinaziekenhuis.nl

Oncology in Clinical Practice
 2019, Vol. 15, No. 1, 71–74
 DOI: 10.5603/OCP.2019.0005
 Copyright © 2019 Via Medica
 ISSN 2450–1654

ABSTRACT

A 54-year-old obese woman with a history of spina bifida was admitted to the hospital with malaise and fever accompanied by leucocytosis, thrombocytosis, and hypercalcaemia. As treatment for neurogenic bladder dysfunction she had a suprapubic catheter. Diagnostic workup for osteomyelitis revealed an unknown mass originating from the urinary bladder on MRI of the pelvis. Further diagnostic analyses showed that the mass was a squamous-cell carcinoma (SCC) with laboratory abnormalities as paraneoplastic phenomena mediated by PTH-related peptide and cytokines released by the SCC. Despite radiotherapy the patient died within two months after initial diagnosis. Squamous-cell carcinoma of the bladder is rare in western countries. In unresectable or metastatic disease survival rates are low due to low responsiveness to standard chemotherapy. Concurrent chemoradiotherapy might be an alternative in unresectable or locally advanced disease; however, evidence to support this is lacking. The poor survival in these patients raises the question of whether high-risk groups for SCC of the bladder, like paraplegic patients or patient with neurogenic bladder dysfunction, should receive screening even though the ideal starting point and frequency are still unknown.

Key words: suprapubic catheter, squamous-cell carcinoma suprapubic tract, neoplastic phenomena

Oncol Clin Pract 2019; 15, 1: 71–74

Introduction

Patients with neurogenic bladder dysfunction can be treated with a suprapubic catheter. Here we present a case of a patient with a squamous cell carcinoma (SCC) of the bladder around the suprapubic catheter tract and consequentially three paraneoplastic phenomena, mimicking infection. Written, informed consent was obtained from a legally authorised representative for anonymised patient information to be published in this article.

Case report

A 54-year-old obese (BMI = 48.9 kg/m²) woman was admitted to the hospital with malaise and fever. She was known with a history of smoking, type 2 diabetes mellitus, and spina bifida. The latter was accompanied by paresis of

both legs and neurogenic bladder dysfunction for which she had had a suprapubic catheter for the last 30 years ago with follow-up by her general practitioner. Physical examination at admission was normal except for two ulcers: one stage IV pressure ulcer at the tailbone and one ulcer at the entrance of the suprapubic cystostomy tract. Laboratory findings revealed a thrombocytosis, neutrophilic leukocytosis, and increased CRP (Tab. 1). Both urine analysis and chest radiography were unremarkable.

An MRI-scan of the pelvis was made to rule out ischial tuberosity osteomyelitis beneath the stage IV pressure ulcer. The MRI showed no signs of osteomyelitis, but an unknown mass originating from the urinary bladder around the suprapubic catheter extending to the entrance of the suprapubic cystostomy (Fig. 1). A biopsy revealed a moderately differentiated invasive squamous cell carcinoma (SCC). CT-scan of the chest, abdomen, and pelvis showed no distant metastases.

Table 1. Laboratory test results at admission and after two weeks

	Reference	Hospital admission	After two weeks
Haemoglobin [mmol/L]	7.5–10.0	5.5	5.1
Haematocrit [L/L]	0.35–0.45	0.28	0.26
Thrombocytes [/nL]	150–400	510	600
Leukocytes [/nL]	4.0–10.0	43.5	54.9
Neutrophilic leukocytes [/nL]	1.5–7.5	40	–
Lactate dehydrogenase [U/L]	122–222	254	–
Alkalic phosphatase [IU/L]	33.0–98.0	181	–
Creatinine [μ mol/L]	50–100	54	65
Urea [mmol/L]	2.5–6.4	3.6	3.4
Creatinine clearance [MDRD, ml/min]		> 60	> 60
Natrium [mmol/L]	135–145	136	137
Potassium [mmol/L]	3.5–5.0	3.4	3.5
Calcium, corrected [mmol/L]	2.10–2.55	2.55	3.43
Albumin [g/L]	35–50	31	28
Magnesium [mmol/L]	0.75–1.0	0.61	0.6
PTH-related protein [pmol/L]	< 0.6	–	2
PTH [pmol/L]	1.6–6.9	0.94	–
25-OH vit D [nmol/L]	> 50	34	26
1,25 di-OH vitamine D [pmol/L]	47–130	–	45
Monoclonal immunoglobulins [g/L]		Positive, IgG lambda: < 2	Urine: negative
TSH [mIU/L]	0.27–4.2	1.6	–
Vitamin A [μ mol/L]	0.7–2.1	1.1	–
Thrombopoietin [IE/ml]	4–32	130	–

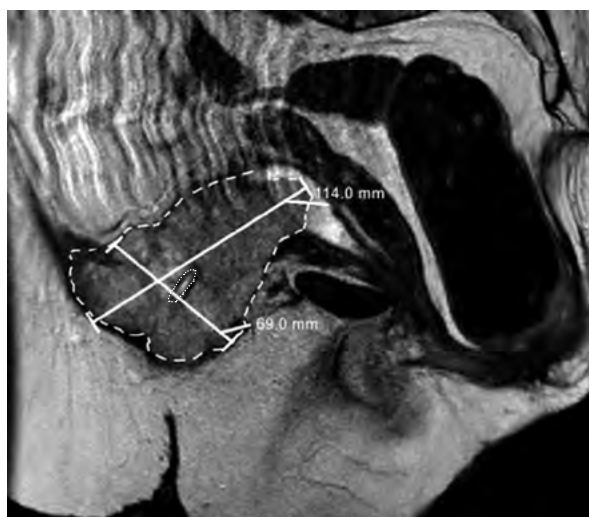


Figure 1. MRI showing a squamous-cell carcinoma (large dashed line) around the suprapubic catheter (small dotted line)

Initially, intravenous antibiotic treatment with ciprofloxacin and flucloxacillin was started to treat a potential underlying infection. Treatment was stopped after two

weeks due to lack of clinical benefit, multiple negative blood cultures, and persistent leucocytosis and fever. In addition, a progressive hypercalcaemia of 3.43 mmol/L was found, which was unlikely to be explained by common causes like immobilisation, osteolytic metastases, or dehydration because the patient had already been immobilised for many years, osteolytic metastases were absent, and hydration did not improve calcium levels. The concomitant suppressed parathyroid hormone (PTH) of 0.94 pmol/L was probably a normal physiological reaction and suggested another mediator responsible for the hypercalcaemia. Closer investigation showed an elevated PTH-related protein of 2.0 pmol/L. Likewise, an elevated thrombopoietin of 130 IE/ml was found as a mediator for the thrombocytosis (Tab. 1).

The final diagnosis was a squamous cell carcinoma of the bladder (cT4N1M0) accompanied by a paraneoplastic syndrome of fever, leukocytosis, thrombocytosis, and hypercalcaemia. The patient was ineligible for radical cystectomy and concurrent chemoradiation based on a WHO performance status of 2. Therefore, treatment was started with bisphosphonates and radiotherapy (51 Gy in 17 fractions). This treatment normalised calcium levels and stopped the fever. After six weeks

of hospitalisation the patient was discharged to strengthen at home. Unfortunately, one week after discharge she was readmitted due to a deteriorating condition. A CT-scan of the chest and abdomen showed new pulmonary metastases, and in consultation with the patient supportive care was started. The patient died within two weeks in a hospice.

Discussion

Squamous cell carcinoma (SCC) of the bladder consists of two subtypes: the bilharzial-associated SCC (B-SCC) and non-bilharzial-associated SCC (NB-SCC). The B-SCC is mainly found in regions where schistosomiasis is endemic, representing 30–50% of bladder cases in these areas [1, 2]. In western countries the NB-SCC subtype is more common, which accounts for 2–5% of bladder neoplasms [1–3]. Important risk factors for NB-SCC are smoking, recurrent urinary infections, and the use of chronic indwelling urinary catheters causing reactive chronic inflammatory and proliferative pathologic changes of the bladder [1, 4, 5]. The incidence of NB-SCC in paraplegic patients is therefore 16–28 times higher.

Paraneoplastic syndromes are well known in pulmonary SCC. These syndromes have also occasionally been reported in SCC of the bladder [6–9]. In this case, the patient presented with a progressive hypercalcaemia and elevated PTH-related peptide (PTH-rP), also known as “humorally mediated hypercalcaemia of malignancy”. This is caused by cancer cells producing PTH-rP with an almost identical structure to PTH, which is therefore able to bind bone and renal PTH-1 receptors. This enhances renal reabsorption and osseous release of calcium [10, 11]. Besides the hypercalcaemia, PTH-rP might also be responsible for the leukocytosis and thrombocytosis. PTH-rP is able to stimulate interleukin-6 (IL-6) secretion from osteoblasts, aside from possible IL-6 secretion by the malignancy itself, which has been described in SCC. IL-6 enhances production of haematopoietic growth factors like granulocyte-colony stimulating factor (G-CSF) and thrombopoietin, resulting in leukocytosis and thrombocytosis [11].

Although we did not measure G-CSF or cytokines, the elevated levels of thrombopoietin and PTH-rP combined with the excessively high neutrophilic leukocytes in the absence of positive blood cultures or steroids suggest that all three phenomena were neoplastic.

Substantial evidence for standard guidelines to treat NB-SCC are lacking since the incidence is low. The main treatment for non-metastatic NB-SCC is radical cystectomy. Preoperative radiotherapy might reduce local recurrence and improve survival [3, 4]. However, despite radical cystectomy and radiotherapy, the prognosis of non-metastatic NB-SCC remains poor with a five-year survival of 34–50%, which is mainly related to failure of locoregional control [1, 3, 4]. Even

though distant metastases are infrequent (8–10%), the presence of metastases or unresectable malignancy reduces the survival dramatically. The reasons for this poor outcome is that NB-SCC shows only low responsiveness for chemotherapy commonly used in urothelial cancer. One study demonstrated some response to treatment with ifosfamide, paclitaxel, and cisplatin with a median survival of 8.9 months, although conclusions are hampered by the small sample size [3, 12]. An alternative treatment for unresectable or locally advanced disease might be concurrent chemoradiotherapy. However, evidence to support this is scarce. Recently, immunotherapy targeting the PD-1 pathway showed promising results. Both atezolizumab in patients previously treated with platinum based therapy and pembrolizumab in patients ineligible for platinum-based regimes have demonstrated an effect in metastatic urothelial cancer [13, 14]. The use of immunotherapy in metastatic squamous cell carcinoma is still unknown and is currently being investigated in a clinical trial using durvalumab and tremelimumab (Clinicaltrial.gov: NCT03430895).

To prevent NB-SCC it is important to reduce the use of chronic indwelling urinary catheters in long-term paraplegic patients. In addition, early discovery with surveillance cystoscopy and urine cytology might be considered in high-risk groups with neurogenic bladder dysfunction, like spina bifida. However, screening on NB-SCC is still under debate because the ideal starting point and frequency are unknown [1, 5, 15, 16].

Contributions: A.J.R. De Bie (guarantor): Acquisition of data, drafting of the manuscript; S. Körver: Acquisition of data, drafting of the manuscript; J.M.H. Kisters: drafting of the manuscript, manuscript review; H.J.E.J. Vrijhof: drafting of the manuscript, manuscript review.

Conflicting interests: All Authors declare that there is no conflict of interest.

Funding: This research received no specific grant from any funding agency in the public, commercial, or not-for-profit sectors.

Informed consent: Written, informed consent was obtained from a legally authorised representative for anonymised patient information to be published in this article. All authors read and approved the manuscript and fulfilled the requirements of authorship.

References

1. Shokeir AA. Squamous cell carcinoma of the bladder: pathology, diagnosis and treatment. *BJU Int.* 2004; 93(2): 216–220, indexed in Pubmed: [14690486](#).
2. Martin JW, Vernez SL, Lotan Y, et al. Pathological characteristics and prognostic indicators of different histopathological types of urinary bladder cancer following radical cystectomy in a large single-center Egyptian cohort. *World J Urol.* 2018 [Epub ahead of print], doi: [10.1007/s00345-018-2331-6](#), indexed in Pubmed: [29761225](#).

3. Martin JW, Carballido EM, Ahmed A, et al. Squamous cell carcinoma of the urinary bladder: Systematic review of clinical characteristics and therapeutic approaches. *Arab J Urol.* 2016; 14(3): 183–191, doi: [10.1016/j.aju.2016.07.001](https://doi.org/10.1016/j.aju.2016.07.001), indexed in Pubmed: [27547458](https://pubmed.ncbi.nlm.nih.gov/27547458/).
4. Zahoor H, Elson P, Stephenson A, et al. Patient Characteristics, Treatment Patterns and Prognostic Factors in Squamous Cell Bladder Cancer. *Clin Genitourin Cancer.* 2018; 16(2): e437–e442, doi: [10.1016/j.clgc.2017.10.005](https://doi.org/10.1016/j.clgc.2017.10.005), indexed in Pubmed: [29154041](https://pubmed.ncbi.nlm.nih.gov/29154041/).
5. Manley KV, Hubbard R, Swallow D, et al. Risk factors for development of primary bladder squamous cell carcinoma. *The Annals of The Royal College of Surgeons of England.* 2017; 99(2): 155–160, doi: [10.1308/rcsann.2016.0343](https://doi.org/10.1308/rcsann.2016.0343).
6. Block NL, Whitmore WF. Leukemoid reaction, thrombocytosis and hypercalcemia associated with bladder cancer. *J Urol.* 1973; 110(6): 660–663, indexed in Pubmed: [4757547](https://pubmed.ncbi.nlm.nih.gov/4757547/).
7. Desai PG, Khan SA, Jayachandran S, et al. Paraneoplastic syndrome in squamous cell carcinoma of urinary bladder. *Urology.* 1987; 30(3): 262–264, indexed in Pubmed: [3307095](https://pubmed.ncbi.nlm.nih.gov/3307095/).
8. Khawaja MR, Bradford CA, Azar JM. Paraneoplastic leukocytosis: an unusual manifestation of squamous cell carcinoma of the urinary bladder. *Oncology (Williston Park).* 2013; 27(12): 1297–1301, indexed in Pubmed: [24624551](https://pubmed.ncbi.nlm.nih.gov/24624551/).
9. Kato T, Yasuda K, Iida H, et al. Trousseau's syndrome caused by bladder cancer producing granulocyte colony-stimulating factor and parathyroid hormone-related protein: A case report. *Oncol Lett.* 2016; 12(5): 4214–4218, doi: [10.3892/ol.2016.5152](https://doi.org/10.3892/ol.2016.5152), indexed in Pubmed: [27895794](https://pubmed.ncbi.nlm.nih.gov/27895794/).
10. Asanuma N, Hagiwara K, Matsumoto I, et al. PTHrP-producing Tumor: Squamous Cell Carcinoma of the Liver Accompanied by Humoral Hypercalcemia of Malignancy, Increased IL-6 and Leukocytosis. *Internal Medicine.* 2002; 41(5): 371–376, doi: [10.2169/internalmedicine.41.371](https://doi.org/10.2169/internalmedicine.41.371).
11. Takaoka S, Yamane Y, Nishiki M, et al. Primary Pulmonary Squamous Cell Carcinoma Associated with Elevated IL-6, Leukocytosis, Hypercalcemia, Phagocytosis, Reactive Lymphadenopathy and Glomerular Mesangial Cell Proliferation via the Production of PTH-rP and G-CSF. *Internal Medicine.* 2008; 47(4): 275–279, doi: [10.2169/internalmedicine.47.0155](https://doi.org/10.2169/internalmedicine.47.0155).
12. Galsky MD, Iasonos A, Mironov S, et al. Prospective trial of ifosfamide, paclitaxel, and cisplatin in patients with advanced non-transitional cell carcinoma of the urothelial tract. *Urology.* 2007; 69(2): 255–259, doi: [10.1016/j.urology.2006.10.029](https://doi.org/10.1016/j.urology.2006.10.029), indexed in Pubmed: [17320659](https://pubmed.ncbi.nlm.nih.gov/17320659/).
13. Rosenberg JE, Hoffman-Censits J, Powles T, et al. Atezolizumab in patients with locally advanced and metastatic urothelial carcinoma who have progressed following treatment with platinum-based chemotherapy: a single-arm, multicentre, phase 2 trial. *Lancet.* 2016; 387(10031): 1909–1920, doi: [10.1016/S0140-6736\(16\)00561-4](https://doi.org/10.1016/S0140-6736(16)00561-4), indexed in Pubmed: [26952546](https://pubmed.ncbi.nlm.nih.gov/26952546/).
14. Balar AV, Castellano D, O'Donnell PH, et al. First-line pembrolizumab in cisplatin-ineligible patients with locally advanced and unresectable or metastatic urothelial cancer (KEYNOTE-052): a multicentre, single-arm, phase 2 study. *Lancet Oncol.* 2017; 18(11): 1483–1492, doi: [10.1016/S1470-2045\(17\)30616-2](https://doi.org/10.1016/S1470-2045(17)30616-2), indexed in Pubmed: [28967485](https://pubmed.ncbi.nlm.nih.gov/28967485/).
15. El Masri y WS, Patil S, Prasanna KV, et al. To cystoscope or not to cystoscope patients with traumatic spinal cord injuries managed with indwelling urethral or suprapubic catheters? That is the question! *Spinal Cord.* 2014; 52(1): 49–53, doi: [10.1038/sc.2013.119](https://doi.org/10.1038/sc.2013.119), indexed in Pubmed: [24276418](https://pubmed.ncbi.nlm.nih.gov/24276418/).
16. Sammer U, Walter M, Knüpfel SC, et al. Do We Need Surveillance Urethro-Cystoscopy in Patients with Neurogenic Lower Urinary Tract Dysfunction? *PLoS One.* 2015; 10(10): e0140970, doi: [10.1371/journal.pone.0140970](https://doi.org/10.1371/journal.pone.0140970), indexed in Pubmed: [26513149](https://pubmed.ncbi.nlm.nih.gov/26513149/).