

Optimized lymphoscintigraphy and diagnostics of lymphatic oedema of the lower extremities

Janusz Dąbrowski¹, Ryszard Merkert², Jacek Kuśmierk¹

¹Department of Nuclear Medicine, Medical University of Lodz, Poland

²Department of Gastroenterologic Oncologic and General Surgery, Medical University of Lodz, Poland

[Received 29 VII 2008; Accepted 3 VIII 2008]

Abstract

BACKGROUND:The elementary diagnostic method for the detection of lymph circulation abnormalities in extremities is lymphoscintigraphy. This method provides information on the morphology and function of the lymphatic system. However, there are no generally acceptable standards for lymphoscintigraphy, which makes judgment of its clinical usefulness very difficult.

MATERIALS AND METHODS: In this work, a discussion is presented on the usefulness of static qualitative scintigraphy of the lymphatic system of lower extremities as well as of its quantitative interpretation, depending upon: (1) time measurement of radiopharmaceutical transport in the system, and (2) assessment of its regional uptake in lymph nodes. The effectiveness of visual assessment combined with each of the quantitative evaluations mentioned is also presented.

RESULTS/CONCLUSIONS: Combination of visual evaluation of static scintigraphy with each of the listed quantitative procedures improves the sensitivity of lymphoscintigraphy in the diagnosis of lymphatic oedema of lower extremities without affecting the specificity of visual evaluation. Both combined methods are characterized by similar indices of diagnostic efficacy. This enables limitation of the quantitative evaluation of lymphatic scintigraphy to the measurement of the final uptake of RPh in the inguinal lymphatic nodes.

Key words: lymphoscintigraphy, lymphatic oedema

Introduction

Lymphatic oedema of the lower extremities is a serious social problem. There are estimates that this disease affects 140–300 million people and its frequency rises with the increase in the number of surgical operations and also with the increasing number of oncologic radiotherapeutic procedures [1, 2]. The therapy of the oedema and its course depend on the accuracy of the diagnosis. Therefore, increasing attention is being paid to improving the diagnostics of the oedema and its characteristics — mainly the disturbed circulation of the lymph. The aim of the present investigation was the optimization of the performance and interpretation of results of lymphoscintigraphy, which seems to be one of the principle methods for diagnosis of lymphatic oedema of lower extremities.

Material and methods

The study was conducted on 67 patients with lymphatic oedema of one or both lower extremities. They were in the age bracket of 11–87 (mean 58) years. On the basis of clinical examinations and Doppler ultrasound inspection of the venous system, two subgroups were established. The first control consisted of 37 limbs without oedema, and the second contained 67 extremities with oedema, which after d-ultrasound examination were diagnosed as being free of venous insufficiency. The latter group of limbs was diagnosed as being affected by the lymphatic oedema. The intensity of the oedema was assessed as being of degree:

- I — of transient character;
- II — as being constant and affecting less than half of the distal part of the tibia;
- III — with constant oedema affecting more than half of the distal part of the tibia;

The oedema of I, II, and III degree were found in 25, 14 and 26 limbs respectively. For lymphoscintigraphy, a ^{99m}Tc labelled human albumin colloid (Nanocoll) was used. The radiopharmaceutical (RPh) was subcutaneously injected simultaneously between the toes of both feet, at activity of 37 MBq for each foot. Immediately

Correspondence to: Janusz Dąbrowski
Department of Nuclear Medicine
ul. Czechosłowacka 8/10, 92–216 Łódź, Poland
Tel.: (+48 42) 678 36 84, fax: (+48 42 679 17 80)
e-mail: jcks@csk.am.lodz.pl

after administration, a 1 min image was acquired of the regions of injection, and after 20 minutes one-minute acquisition was collected again in the inguinal regions. In the course of this acquisition, a standardized physical exercise was applied to accelerate the lymph flow; during this test, the patient flexed and straightened his feet at a rate 20 movements per minute over the whole study (20 min). At 2 hours after the injection of the RPh a static scintigram was made of the whole body in AP projection. In visual evaluation of this image (static), special attention was paid to any abnormalities of lymph circulation:

- absent visualization of lymph nodes or lymphatic channels;
- the presence of dermal back flow;
- interrupted vascular structures;
- visualization of collateral lymphatic channels.

The quantitative evaluation of lymphoscintigraphy was based on two procedures. The first consisted of measurement of the time over which the colloid reached the inguinal nodes (TT — transit time). The second method provided the activity ratio for inguinal nodes: total body uptake at 2 hours after injection of the RPh. To obtain this information, the activity was measured in injection sites immediately after administration and calculating the percentage of the total present in the left and right foot. In the whole body scintigram (2 hours after injection), a count ratio was measured in the whole body and in the inguinal nodes on both sides (right and left). The indices of the regional RPh uptake (UI) in the inguinal nodes were calculated using the following equations:

$$UIL = \frac{ZwL}{Zcc \times WpL} \times 100\%$$

or:

$$UIR = \frac{ZwR}{Zcc \times WpR} \times 100\%$$

where:

UIL and UIR — uptake indices in the nodes of left inguinal region and right inguinal region, respectively; ZwL and ZwR — count rate in the nodes of the left inguinal region and right inguinal region, respectively; Zcc — count rate over the total body; WpL and WpR — percentage of the colloid administered into the left foot and right foot, respectively.

For each of the methods, the indices of diagnostic efficacy were calculated. Diagnostic thresholds for the detection of lymph flow disturbances for both quantitative methods were estimated on the basis of ROC curves. When the results of lymphoscintigraphy were assessed on the basis of two methods (visual and quantitative), lymphatic dysfunction was diagnosed when at least one result was abnormal. Statistical analysis of the results utilized non-parametric methods (distribution of the analysed data was significantly different from the Gaussian distribution).

The test of Mann-Whitney was used for the evaluation of the agreement of transit time and uptake indices of RPh in the inguinal lymph nodes.

A χ^2 test was used for evaluation of the differences in proportions (indices of diagnostic efficacy).

The coefficient of rang correlation (Spearman) was used for assessment of the relations between the variables.

Table 1. The basic indices of the diagnostic efficacy of all applied procedures

	Sensitivity	Specificity
Quantitative evaluation of the dynamic study (met 1)	52	86
Visual evaluation of static scintigrams (met 2)	46	100
Quantitative evaluation of the static scintigrams (met 3)	51	89
Combined method (2 + 1)	69*	86
Combined method (2 + 3)	67*	89

*As a result of combining visual qualitative and quantitative assessments the indices of diagnostic sensitivity were significantly increased ($p = 0.04$)

Statistical conclusions on the significance in relations were based on $p < 0.05$, and the latter was obtained by application of Statistica 6.0 software.

Results

In static images, the evidence of disturbed lymph circulation was seen in 31 out of 67 extremities with oedema (46%). In the oedema grades I, II, and III, the same frequencies were 33, 43 and 62 percent, respectively. The mean time of RPh transit from the foot to the inguinal space was 14min (SD = 19 min); it was significantly greater ($p < 0.0001$) in extremities with oedema than in controls, in which the mean TT was 7 (SD = 4 min). In the same images, the uptake of colloid in the inguinal lymph nodes was 10.1 (SD = 8.3%) and 19.6 % (SD = 10.9) in the oedematous and control extremities, respectively. The difference was highly significant ($p < 0.0001$). There was also a linear relationship between the RPh transit time and its uptake in the inguinal nodes. The uptake was higher at shorter transit times ($r = -0.42$; $p < 0.0001$). The basic indices of the diagnostic efficacy of all applied procedures are presented in Table 1. For both combined methods (2 + 1) and (2 + 3) optimal values of diagnostic effectiveness were obtained for transit time = 9 minutes and for uptake index = 8%, respectively.

Discussion

Lymphatic oedema is a disease with a complex pathogenesis. It may be due to congenital abnormalities, obstruction or damage of lymphatic channels, or functional derangement of the lymphatic system [3–5]. The diagnosis of pathological impairment of the circulation is quite often made by exclusion of the other potential causes leading to oedema. Lymphoscintigraphy seems to be a basic method which provides information regarding the morphology and function of the lymphatic system [6]. Data provided by this method may be interpreted visually, qualitatively and quantitatively. The visual qualitative evaluation is characterized by a high specificity of diagnosing a dysfunction of the lymphatic system, reaching 97–100% [7, 8]. However, its sensitivity varies widely, depending on individual features of the affected system, from 61 to 97% [9, 10]. In this study the specificity reached 100% but sensitivity was very low, of the order of 40–50% percent. This low sensitivity probably resulted from the fact that in the studied group of patients there

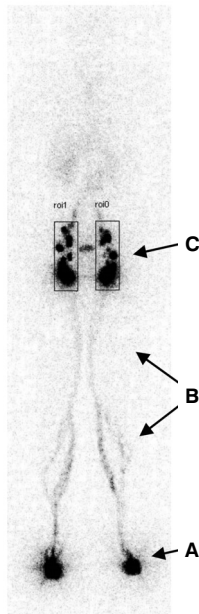


Figure 1. Whole body scintigram 2 hours after injection of Nanocoll in both feet. A — injection sites; B — lymphatic channels; C — inguinal lymphatic nodes with marked regions of interest.

was a substantial frequency of mild oedema of the lower extremities. In the subgroup of oedema of the third degree, the impaired circulation of the lymph was diagnosed twice as often as in the group with transient oedema.

There are in the literature several reports on different quantitative interpretations of the scintigraphic methods; however, their clinical usefulness is not straightforward [11–15]. The reported sensitivity of individual methods varies from 55 to 100%, depending on specific features and performance of the investigator. [16–17]. Moreover, there have been no commonly accepted norms reflecting the variability of the lymph circulation, which in turn depends upon various factors. The variability of results depends on the radiopharmaceutical applied, its volume, pH, electrical charge, and hydrophilicity [2]. There are authors who use and recommend ^{99m}Tc HIG (human immunoglobulin), but better images of the lymph nodes were reported after administration of Nanocoll. A faster passage of RPh has been seen after intracutaneous injection, when compared with subcutaneous administration. The passage is accelerated by mechanical stimulation (massage, physical stress) as well as increased hydrostatic pressure of the interstitial fluid due to oedema or upright position [2, 19]. There are very few comparisons regarding the efficacy of using nuclear medicine methods in the discussed area of clinical investigation. Proby et al. [20] studied the rate of flow of RPh from the injection site and compared it with the uptake of colloid in the inguinal lymph nodes. The authors came to the conclusion that studies on the ratio of outflow are technically difficult and time consuming and did not contribute additional valuable information when compared with the method of assessing regional uptake of RPh in the inguinal lymph nodes. They recommended performing the lymphoscintigraphy at 2 hours post injection of the RPh. Larcos et al. [9] recommended acquisition of additional scintigrams after 24 hours with the expectation that this modification might enhance diagnostic sensitivity of the

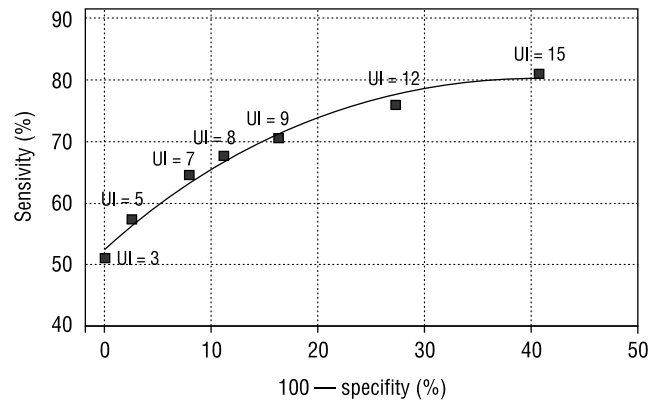


Figure 2. ROC curve for combined methods — visual qualitative assessment of static scintigram and quantitative measurement of the accumulation of the colloid in inguinal lymphatic nodes. Optimal value of uptake index (UI = 8%) is printed in bold.

method. In the present study, the reference data for evaluation of quantitative results of lymphoscintigraphy were obtained from a parallel study of oedema free, healthy limbs of the same patients. This way of normalizing the data was derived from earlier studies in which no differences were found in the UI indices measured in extremities free from oedema and the legs not affected by the oedema in patients with one leg affected, and healthy volunteers [20]. In our study the results obtained from investigation of swollen and unaffected limbs in patients with oedema were statistically significantly different ($p < 0.0001$). It was also found that faster RPh passage is accompanied by higher accumulation of the colloid in lymph nodes. However, the values of diagnostic indices (specificity 86–89%) were accompanied by a low sensitivity (51–52%). Similarly to other studies [18, 21] on patients with dysfunction of the lymphatic system, there was frequently in our investigation a normal or even accelerated flow of the Nanocolloid. Due to these observations and the observed variability of TT and UI, we believe that establishing decision thresholds to provide high diagnostic effectiveness based solely on quantitative measurements is probably impossible. This conclusion led us to the idea that a combination of quantitative and qualitative data could improve the diagnostic efficacy of lymphoscintigraphy. Basing the diagnosis both on visual inspection of scintigraphy at 2 hours post administration of RPh and either TT or uptake index (UI) has led to an improvement in sensitivity of lymphoscintigraphy in diagnosing lymphatic oedema in lower extremities from 52% to 69% and 51% to 67%, respectively. Both ways could be used with equal validity. However, measurement of the uptake of RPh in inguinal nodes 2 hours post injection is less time consuming and easier than establishing the transit time (TT). Nevertheless, using the latter quantity might be recommended for patients in whom the inguinal lymph nodes were removed surgically.

Conclusions

1. Combining qualitative visual inspection of static scintigrams with one of the quantitative measurements, either TT or UI, improves the sensitivity of lymphoscintigraphy in diagnosing lymphatic oedema in lower extremities.

2. Both combinations of the methods have similar diagnostic efficacy, and therefore it is possible to limit the scintigraphy to visual inspection at 2 hours post injection, and measurement of the uptake index (UI).

References

- Ruciński A, Janczak D, Szyber P. Wyniki kompleksowej terapii obrzęku chłonnego kończyn dolnych. *Pol Przegl Chir* 2002; 74: 430–435.
- Szuba A, Shin WS, Strauss HW et al. The third circulation: radionuclide lymphoscintigraphy in the evaluation of lymphedema. *J Nucl Med* 2003; 44: 43–57.
- Carpentier PH. Physiopathology of lymphedema. *Rev Med Interne* 2002; 23: 371–374.
- Tomczak H, Nyka W, Lass P. Lymphoedema: lymphoscintigraphy versus other diagnostic techniques — a clinician point of view. *Nucl Med Rev Cent East Eur* 2005; 8: 37–43.
- Szuba A, Rockson SG. Lymphedema: classification, diagnosis and therapy. *Vasc Med* 1998; 3: 145–56.
- Shinavi M. Lymphedema of the lower extremity: is it genetic or nongenetic. *Clin.Pediatr* 2007; 46: 835–841.
- Gloviczki P, Calcagno D, Schriger A et al. Noninvasive evaluation of the swollen extremity: experiences with 190 lymphoscintigraphic examinations. *Vasc Surg* 1989; 9: 683–689.
- Ogawa Y, Hayashi K. ^{99m}TcDTPA-HAS lymphoscintigraphy in lymphedema of the lower extremities: diagnostic significance of dynamic study and muscular exercise. *Kaku Igaku* 1999; 36: 31–36 (abstaract).
- Larcos G, Foster DR. Interpretation of lymphoscintigrams in suspected lymphoedema: contribution of delayed images. *Nucl Med Commun* 1995; 16: 683–686.
- Stewart G, Gaunt JI, Croft DN, Browse NL. Isotope lymphography: a new method of investigating the role of the lymphatics in chronic limb oedema. *Br J Surg* 1985; 72: 906–909.
- Mortimer PS. Evaluation of lymphatic function: abnormal lymph drainage in venous disease. *Int Angiol* 1995; 14: 32–35.
- Brautigam P, Foldi E, Schaiper I et al. Analysis of lymphatic drainage in various form of leg edema using two compartment lymphoscintigraphy. *Lymphology* 1998; 31: 43–55.
- Bull RH, Gane JE, Evans JEC et al. Abnormal lymph drainage in patients with chronic leg ulcers. *J Am Acad Dermatol* 1993; 28: 585–90.
- Suga K, Kume N, Matsunaga N et al. Assessment of leg oedema by dynamic lymphoscintigraphy with intradermal injection of technetium-99m human serum albumin and load produced by standing. *Eur J Nucl Med* 2001; 28: 294–303.
- Modi S, Stanton AW, Svensson WE et al. Human lymphatic pumping measured in healthy and lymphoedematous arms by lymphatic congestion lymphoscintigraphy. *J Physiol* 2007; 8: 271–285.
- Cambria RA, Gloviczki P, Naessens et al. Noninvasive evaluation of the lymphatic system with lymphoscintigraphy: a prospective semiquantitative analysis in 386 extremities. *J Vasc Surg* 1993; 18:773–882.
- Weissleder H, Weissleder R. Lymphedema: evaluation and quantitative lymphoscintigraphy in 238 patients. *Radiology* 1988; 167: 729–735.
- Nawaz MK, Mamad MM, Bdel-Dayem HM et al. Lymphoscintigraphy in lymphedema of the lower limbs using ^{99m}Tc HSA. *Angiology* 1992; 43: 147–154.
- O'Mahoney S, Rose SL, Chilvers AJ et al. Finding and optimal method for imaging lymphatic vessels of the upper limb. *Eur J Nucl Med Mol Imaging* 2004; 31: 555–563.
- Proby CM, Gane JM, Joseph AEA et al. Investigation of the swollen limb with isotope lymphography. *Br J Dermatol* 1990; 123: 29–37.
- Howarth DM. Increased lymphoscintigraphic flow pattern in the lower extremity under evaluation for lymphedema. *Mayo Clin Proc* 1997; 72: 423–429.