


A crying liver: a scan pattern mimicking spontaneous perforation of the biliary ducts

Somaye Barashki¹ , Hadis Mohammadzadeh Kosari¹, Emran Askari¹, Zahra Bakhshi Golestani¹, Mehran Hradfar², Ramin Sadeghi¹

¹Nuclear Medicine Research Center, Mashhad University of Medical Sciences, Mashhad, Iran

²Department of Pediatric Surgery, Mashhad University of Medical Sciences, Mashhad, Iran

[Received 27 IV 2021; Accepted 27 IV 2022]

Abstract

A 2-month-old infant was referred for hepatobiliary scintigraphy due to ascites of unknown cause. The top differential diagnosis was spontaneous perforation of the biliary ducts. Delayed images up to 4 hours were against this diagnosis showing normal distribution of the radiotracer throughout the bowel. However, on delayed images, the scan showed mild tracer retention in the ascites confirmed by SPECT/CT images. Surprisingly, the exploratory abdominal surgery revealed an intact hepatobiliary system, pointing toward other possible etiologies. Second-review surgery was performed due to uncontrolled progressive ascites showing congestive hepatopathy and biliary leak from the hepatic surface suggestive of the “crying liver”.

KEY words: hepatobiliary scintigraphy; crying liver; biliary leak

Nucl Med Rev 2022; 25, 2: 131–133

Hepatobiliary scintigraphy (HBS) is a well-known diagnostic method for the evaluation of bile duct disease and biliary leak. Several studies have reported that HBS has played an important role in diagnosing spontaneous biliary leak, especially when associated with single photon emission computed tomography/computed tomography (SPECT/CT) [1–6].

A 2-month-old female pediatric patient presenting with abdominal distension since 5 days ago and suspicion of spontaneous perforation of the common bile duct was referred to the nuclear medicine department for hepatobiliary scintigraphy (HBS). Laboratory examination showed elevated total and direct bilirubin levels (4.1 and 2.1 mg/dL, respectively) and high alkaline phosphatase (556 IU/L). Abdominal ultrasonography showed ascites with a normal appearance of liver parenchyma, gallbladder, biliary ducts, and portal vein. Ascites fluid analysis was inconclusive for biliary ascites showing borderline elevation of the total bilirubin (1.5 mg/dL) [7]. Hepatobiliary scintigraphy (HBS) was performed

after an intravenous injection of 37 MBq of ^{99m}Tc-mebrofenin. Dynamic imaging showed normal hepatic uptake and normal intra- and extra-hepatic ducts (Fig. 1A). Delayed static images 2 and 4 hours after injection demonstrated no abnormal radiotracer activity outside the biliary system and intestinal tract (Fig. 1B, C). To increase the sensitivity for detection of bile leakage, 24-hour delayed imaging was also performed showing an accumulation of the tracer throughout the peritoneum (Fig. 1D) [8, 9].

Single photon emission computed tomography/computed tomography (SPECT/CT) images from the abdominal region confirmed the presence of activity in the ascites fluid (Fig. 2). The presence of radiotracer activity in the ascites fluid on the delayed images raised the possibility of biliary tract perforation. During the exploratory abdominal surgery, the hepatobiliary system was intact but there was a large omental cyst as well as intestinal malrotation with a large amount of yellowish free fluid in the peritoneal cavity. Surgical correction was done by resecting the omental cyst with correction of the intestinal malrotation. Owing to progressive abdominal distention, further, work-up was carried out showing increased ascites in the abdominal cavity. The patient underwent second-look surgery. No culprit pathology was found in the exploratory surgery except for superficial bile leak from the hepatic surface and the appearance of liver congestion suggestive of the “crying liver” [10, 11]. The final diagnosis was in favor of

Correspondence to: Ramin Sadeghi, Nuclear Medicine Research Center, Mashhad University of Medical Sciences, Mashhad, Iran, phone: +985138012794, e-mail: sadeghir@mums.ac.ir; raminsadeghi1355@yahoo.com




Figure 1. (A) Dynamic imaging from the abdominal region in anterior view showed normal hepatic uptake and biliary ducts with normal excretion of the radiotracer into the intestine; (B) Static image 2 hours after injection; (C) Static image 4 hours after injection; (D) Static image 24 hours after injection in anterior view showing accumulation of the tracer throughout the peritoneum

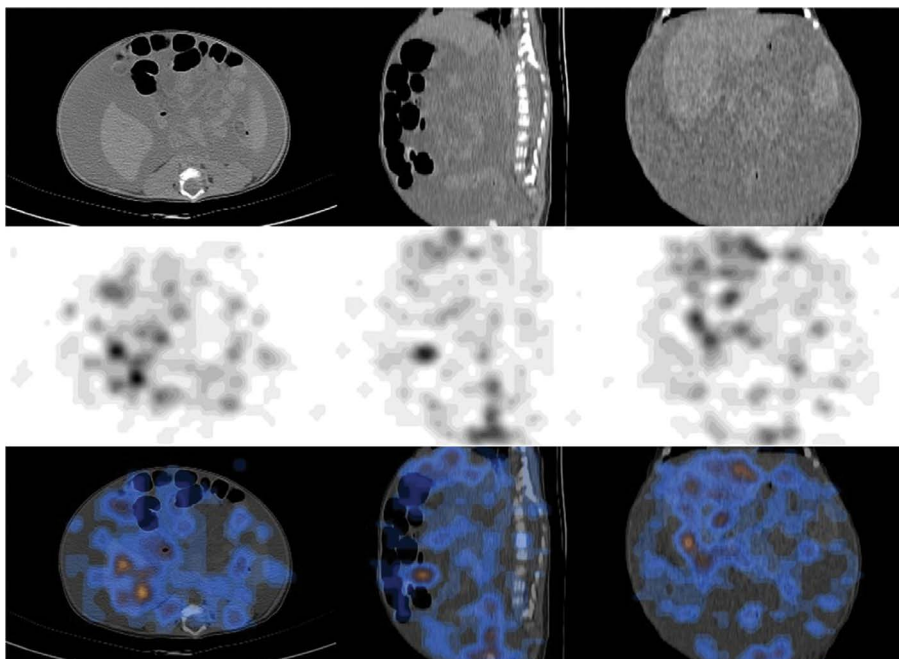


Figure 2. Computed tomography (CT) scan (top row); SPECT images (middle row) and single photon emission computed tomography/computed tomography SPECT/CT images (bottom row) in axial, sagittal, and coronal views confirmed the presence of activity in the peritoneal cavity

Budd-Chiari syndrome. The patient died 12 days after the second explorative laparotomy.

The most probable reason for radiotracer appearance in the ascites fluid on the delayed HBS images was due to oozing of the radiotracer from the liver surface. The present case highlights the usefulness of HBS to narrow the differential diagnosis of ascites of unknown cause in pediatric patients. Delayed imaging is useful in doubtful and challenging cases.

Conflict of interest

The authors declare no conflict of interest.

References

1. Tulchinsky M, Ciak BW, Delbeke D, et al. Society of Nuclear Medicine. SNM practice guideline for hepatobiliary scintigraphy 4.0. J Nucl Med Technol.

- 2010; 38(4): 210–218, doi: [10.2967/jnmt.110.082289](https://doi.org/10.2967/jnmt.110.082289), indexed in Pubmed: [21078782](https://pubmed.ncbi.nlm.nih.gov/21078782/).
2. Snyder ST, Banks KP. Hepatobiliary Scintigraphy. Treasure Island (FL): StatPearls Publishing. 2019(12).
 3. Joodi M, Norouzbeigi N, Rad MA, et al. Spontaneous perforation of common bile duct in a pediatric patient: application of hepatobiliary scintigraphy. Clin Nucl Med. 2012; 37(10): 1006–1008, doi: [10.1097/RLU.0b013e318263928f](https://doi.org/10.1097/RLU.0b013e318263928f), indexed in Pubmed: [22955078](https://pubmed.ncbi.nlm.nih.gov/22955078/).
 4. Sood A, Parihar AS, Thapa BR, et al. Hepatobiliary Scintigraphy Findings Lead to the Diagnosis of Spontaneous Common Bile Duct Rupture in an Infant. Clin Nucl Med. 2017; 42(3): 223–224, doi: [10.1097/RLU.0000000000001509](https://doi.org/10.1097/RLU.0000000000001509), indexed in Pubmed: [28045732](https://pubmed.ncbi.nlm.nih.gov/28045732/).
 5. Vijay BB, Kumar R, Gupta DK, et al. Spontaneous biliary perforation in an infant: an unusual chronic presentation. Clin Nucl Med. 2008; 33(4): 273–275, doi: [10.1097/RLU.0b013e3181662adb](https://doi.org/10.1097/RLU.0b013e3181662adb), indexed in Pubmed: [18356667](https://pubmed.ncbi.nlm.nih.gov/18356667/).
 6. Arun S, Santhosh S, Sood A, et al. Added value of SPECT/CT over planar Tc-99m mebrofenin hepatobiliary scintigraphy in the evaluation of bile leaks. Nucl Med Commun. 2013; 34(5): 459–466, doi: [10.1097/MNM.0b013e3283601098](https://doi.org/10.1097/MNM.0b013e3283601098), indexed in Pubmed: [23503002](https://pubmed.ncbi.nlm.nih.gov/23503002/).
 7. Huda F, Naithani M, K Singh S, et al. Ascitic Fluid/Serum Bilirubin Ratio as an aid in Preoperative Diagnosis of Choleperitoneum in a Neglected Case of Spontaneous Common Bile Duct Perforation. Euroasian J Hepatogastroenterol. 2017; 7(2): 185–187, doi: [10.5005/jp-journals-10018-1246](https://doi.org/10.5005/jp-journals-10018-1246), indexed in Pubmed: [29201807](https://pubmed.ncbi.nlm.nih.gov/29201807/).
 8. Brugge WR, Rosenberg DJ, Alavi A. Diagnosis of postoperative bile leaks. Am J Gastroenterol. 1994; 89(12): 2178–2183, indexed in Pubmed: [7977237](https://pubmed.ncbi.nlm.nih.gov/7977237/).
 9. Gupta V. Bile leak detection by radionuclide scintigraphy. Kathmandu Univ Med J (KUMJ). 2006; 4(1): 82–85, indexed in Pubmed: [18603875](https://pubmed.ncbi.nlm.nih.gov/18603875/).
 10. Bourgeois, F. John, and John B. Hanks: Color Atlas of Laparoscopy. Annals of Surgery 1984: 330.
 11. Tandon K, Dabage N, Rodriguez M. A Crying Liver: Complication of Endoscopic Retrograde Cholangiopancreatography. American Journal of Gastroenterology. 2017; 112: S733, doi: [10.14309/00000434-201710001-01352](https://doi.org/10.14309/00000434-201710001-01352).