

Multiple photopenic vertebrae in the bone scintigraphy of a young man with Gorham disease: CT and MRI correlation

Ramin Sadeghi, Sara Shakeri, Toktam Massoudi, Fatemeh Farahmandfar, Farnaz Nesari Javan

Nuclear Medicine Research Center, School of Medicine, Mashhad University of Medical Sciences, Mashhad, Iran, Islamic Republic Of

[Received 3 XI 2018; Accepted 29 XI 2018]

Abstract

We report a rare pattern of extensive bone abnormalities on the Tc-99m MDP bone scintigraphy in a patient with Gorham disease. This rare condition is the result of vascular and lymphatic channel proliferation in bony structures which induce bone resorption. Our case is a 28-year-old man with a history of biopsy-proven soft tissue hemangioma in the left thigh, encountered with a recent diagnosis of multiple vertebral hemangiomata in the axial skeleton and progressive bony destructions in the pelvis on CT and MRI images, referred for bone scintigraphy. Multiple photopenic hemangiomata were noted on bone scan.

KEY words: Gorham disease, bone resorption, vascular proliferation, hemangioma

Nucl Med Rev 2019; 22, 1: 40–42

Introduction

Gorham disease is known as a rare disappearing-bone disease [1] most commonly in the shoulders and the pelvic girdles; however, various bone structures can be involved such as skull, mandible, humerus, scapula, clavicle, sternum, axial skeleton, hands and feet [2, 3]. Primary involvement of the spine is infrequent [4]. We present a rare form of extensive bony involvement in multiple areas including the spine and pelvis, with photopenic appearance in the whole-body bone scan.

Case report

A 28-year-old man with a history of biopsy-proven soft tissue hemangioma in the left thigh since 3 years ago, admitted with a chief complaint of recently progressive disability of walking. The plain radiography of the pelvis showed subtle osteolysis in the sacrum, left sacroiliac joint, left iliac bone and left femoral head. For precise evaluation, Thoraco-abdomino-pelvic multislice computed tomography [CT] scan and transaxial magnetic resonance images [MRI] were performed (Fig. 1, 2 and 3).

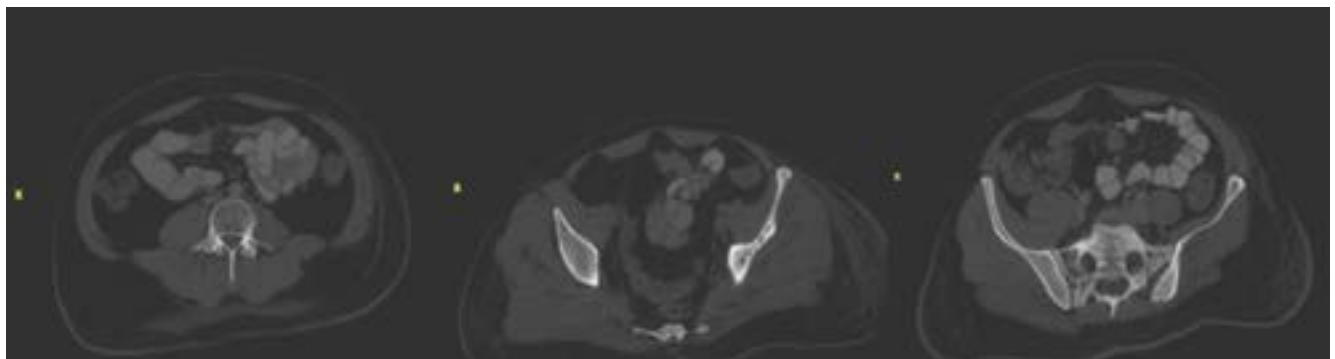


Figure 1. CT images showed Polka-dot sign or salt and paper appearance in T12, L1 and L3–L5 vertebrae, as well as lytic lesions in the sacrum and destructed left iliac bone

Correspondence to: Ramin Sadeghi, Nuclear Medicine Research Center, School of Medicine, Mashhad University of Medical Sciences, Mashhad, Iran, Islamic Republic Of, e-mail: sadeghir@mums.ac.ir

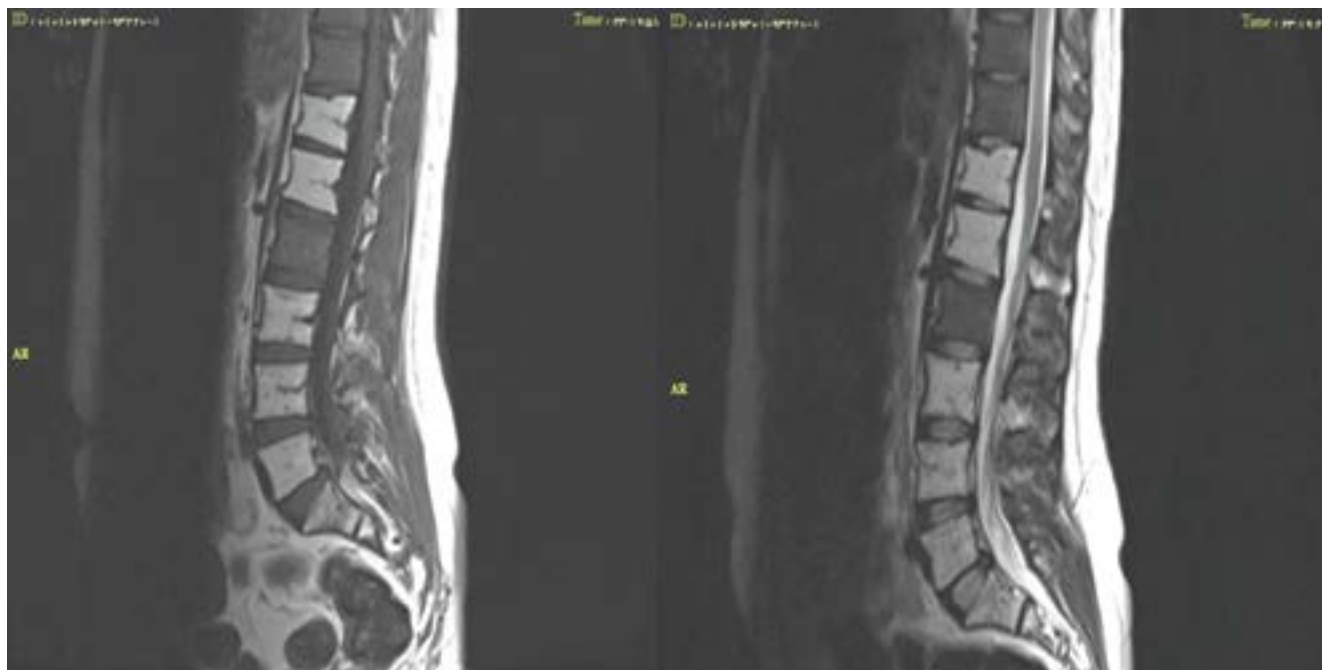

Figure 2. Spine MRI revealed multiple hypersignal vertebrae on T1 (left) and T2-weighted (right) sections in T12, L1, and L3–L5 vertebrae

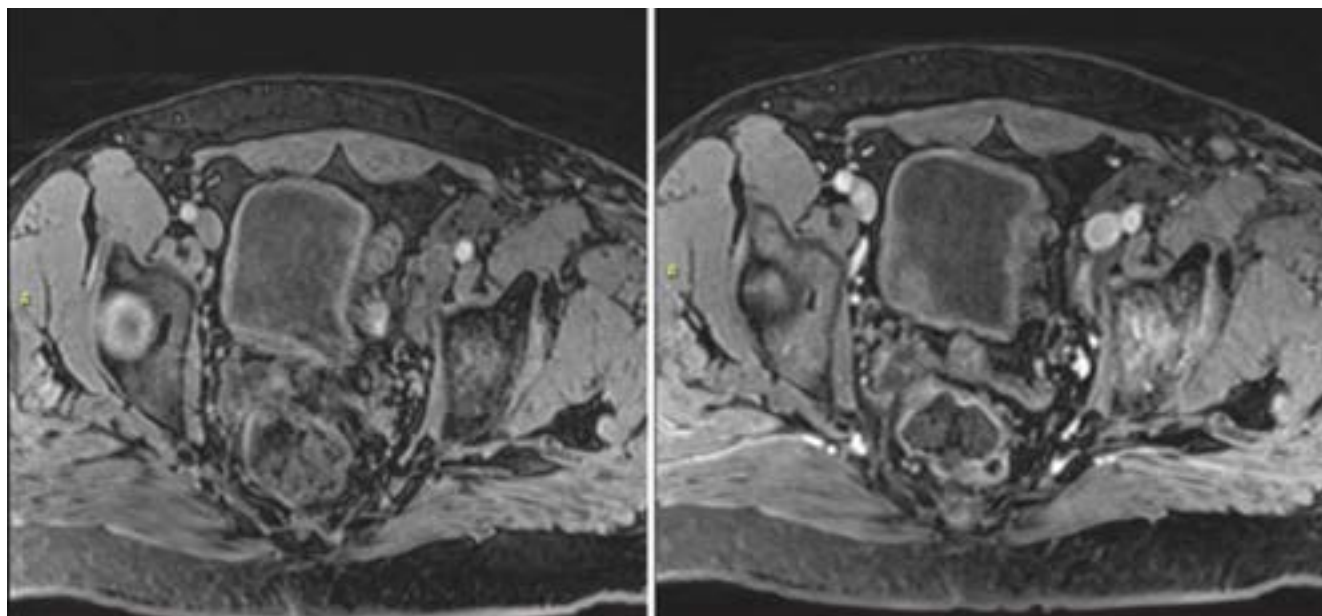


Figure 3. Pelvic MRI with IV contrast showed soft tissue enhancement in the left thigh and confirmed the extensive soft tissue hemangioma in this region

Whole-body bone scan and following SPECT acquisition were performed four hours after IV injection of 740 MBq (20 mCi) Tc-99m-methylene diphosphonate [Tc-99m MDP], using a dual-head variable angle gamma camera with a low-energy high-resolution parallel-hole collimator (Fig. 4).

Discussion

As we report in our case, vascular proliferation and replacement of bone matrix with fibrous tissue lead to bone destruction and osteolysis [5–7]. The etiology of the disease is still unknown. Notably,

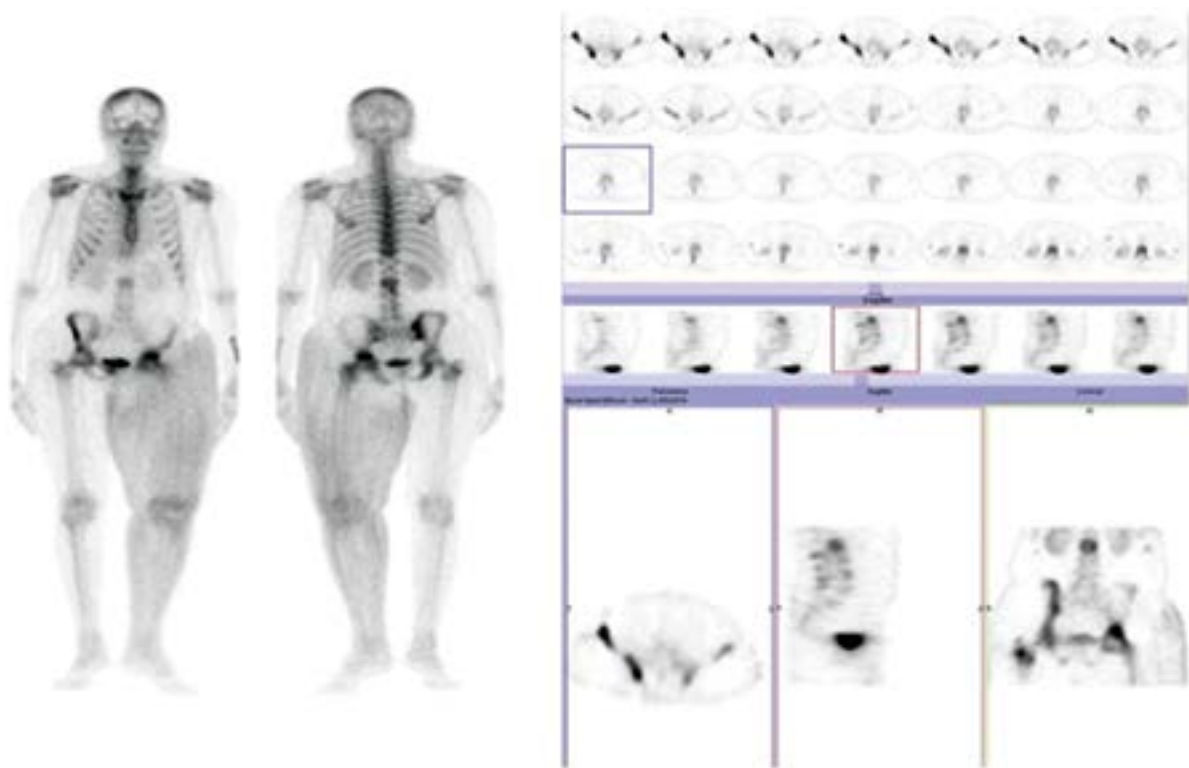


Figure 4. Tc-99m MDP whole-body bone scan showed multiple zones of absent tracer uptake in the T12, L1 and L3–L5 vertebrae, sacrum, left sacroiliac joint, left iliac bone and right femoral head, as well as increased tracer activity in the left femoral head and left thigh swelling. SPECT images on the right side, also confirmed the whole-body scan findings

suspicion of the vanishing-bone disease should be considered only after excluding the other significant differential diagnosis such as infection, malignancy, inflammatory and endocrine pathologies. Despite the benign pathology of the disease, the prognosis is unpredictable with possibly serious consequences like pathologic fractures [3].

It was mentioned that increased Tc-99m MDP uptake in the affected bony regions may indicate the active phase of bone disease [8]; however, limited photopenic involved sites in the whole-body bone scan were reported in the sacroiliac joint [9], mandible [10], lumbar spine [11] and left lower rib cage [8].

Conflict of interest

None declared.

References

- Ruggieri P, Montalti M, Angelini A, et al. Gorham-Stout disease: the experience of the Rizzoli Institute and review of the literature. *Skeletal Radiol.* 2011; 40(11): 1391–1397, doi: [10.1007/s00256-010-1051-9](https://doi.org/10.1007/s00256-010-1051-9), indexed in Pubmed: [20972870](https://pubmed.ncbi.nlm.nih.gov/20972870/).
- Patel DV. Gorham's disease or massive osteolysis. *Clin Med Res.* 2005; 3(2): 65–74, indexed in Pubmed: [16012123](https://pubmed.ncbi.nlm.nih.gov/16012123/).
- Nikolaou VS, Chytas D, Korres D, et al. Vanishing bone disease (Gorham-Stout syndrome): A review of a rare entity. *World J Orthop.* 2014; 5(5): 694–698, doi: [10.5312/wjo.v5.i5.694](https://doi.org/10.5312/wjo.v5.i5.694), indexed in Pubmed: [25405099](https://pubmed.ncbi.nlm.nih.gov/25405099/).
- Flörchinger A, Böttger E, Claass-Böttger F, et al. [Gorham-Stout syndrome of the spine. Case report and review of the literature]. *Rofo.* 1998; 168(1): 68–76, doi: [10.1055/s-2007-1015184](https://doi.org/10.1055/s-2007-1015184), indexed in Pubmed: [9501937](https://pubmed.ncbi.nlm.nih.gov/9501937/).
- Papadakis GZ, Millo C, Bagci U, et al. 18F-NaF and 18F-FDG PET/CT in Gorham-Stout Disease. *Clin Nucl Med.* 2016; 41(11): 884–885, doi: [10.1097/RLU.0000000000001369](https://doi.org/10.1097/RLU.0000000000001369), indexed in Pubmed: [27648707](https://pubmed.ncbi.nlm.nih.gov/27648707/).
- Gorham LW, Stout AP. Massive osteolysis (acute spontaneous absorption of bone, phantom bone, disappearing bone); its relation to hemangiomas. *J Bone Joint Surg Am.* 1955; 37-A(5): 985–1004, indexed in Pubmed: [13263344](https://pubmed.ncbi.nlm.nih.gov/13263344/).
- Posadas MD, Viejo Stuart S, Romano O, et al. Gorham-Stout syndrome: a case report. *Eur Rev Med Pharmacol Sci.* 2014; 18(1 Suppl): 81–83, indexed in Pubmed: [24825048](https://pubmed.ncbi.nlm.nih.gov/24825048/).
- Yang RH, Chen PCH, Chang CP, et al. Gorham's disease: the disappearing bone. *Clin Nucl Med.* 2013; 38(5): 361–364, doi: [10.1097/RLU.0b013e318286bf93](https://doi.org/10.1097/RLU.0b013e318286bf93), indexed in Pubmed: [23486335](https://pubmed.ncbi.nlm.nih.gov/23486335/).
- Brown RD, Studentsova Y, Margouleff D. Vanishing bone disease of the pelvis. *Clin Nucl Med.* 2004; 29(11): 709–711, indexed in Pubmed: [15483484](https://pubmed.ncbi.nlm.nih.gov/15483484/).
- Park SB, Choi JY, Kim SJ. Gorham-Stout Disease Affecting the Mandible: Bone Scintigraphy and Computed Tomography Findings. *Clin Nucl Med.* 2017; 42(10): 779–781, doi: [10.1097/RLU.0000000000001800](https://doi.org/10.1097/RLU.0000000000001800), indexed in Pubmed: [28806245](https://pubmed.ncbi.nlm.nih.gov/28806245/).
- Mabille L, Berenger N, Laredo JD, et al. Vanishing vertebra. *Clin Nucl Med.* 1997; 22(1): 49–51, indexed in Pubmed: [8993876](https://pubmed.ncbi.nlm.nih.gov/8993876/).