

# Diagnostic value of cerebral perfusion scintigraphy in evaluation of intracranial arteriovenous malformations — preliminary report

Anna Nocuń<sup>1</sup>, Maciej Szajner<sup>2</sup>, Krzysztof Gil<sup>3</sup>,  
Janina Zaorska-Rajca<sup>1</sup>

<sup>1</sup>Chair and Department of Nuclear Medicine, Skubiszewski Medical University of Lublin, Poland

<sup>2</sup>Chair and Department of Interventional Radiology and Neuroradiology, Skubiszewski Medical University of Lublin, Poland

<sup>3</sup>Chair and Clinic of Neurosurgery and Paediatric Neurosurgery, Skubiszewski Medical University of Lublin, Poland

[Received 2 IV 2004; Accepted 13 IV 2004]

## Abstract

**BACKGROUND:** Arteriovenous malformations (AVM) markedly alter the distribution of the regional cerebral blood flow, as they consist of abnormal arteries and veins with no resistance vessels between them. The aim of this study was to evaluate diagnostic utility of cerebral perfusion scintigraphy (dynamic phase and SPECT) in patients with AVM.

**MATERIAL AND METHODS:** Nineteen patients were examined. All the patients had been previously diagnosed with AVM and qualified for intravascular embolization. Brain scintigraphy was performed with <sup>99m</sup>Tc-ECD and included dynamic phase and SPECT imaging. The regional blood flow was evaluated visually and semi quantitatively, based on comparison between the activity in the two symmetrical regions of interest. Differences higher than 10% were considered significant. Cerebral angiography combined with intravascular embolization was carried out after a scintigraphic examination.

**RESULTS:** Based on angiograms, the diameter of the AVM nidus was estimated and varied from 1.0 cm to 9.0 cm. In 13 cases, AVM were visible in the dynamic scintigraphy as areas of increased tracer activity. In each case, SPECT images showed the AVM nidus as a region of decreased tracer accumulation. Hypoperfusion in the brain tissue adjacent to the nidus was seen in 15 subjects. In one patient cerebellar diaschisis was present. The average ratio of activity in the region of AVM to activity in the normally perfused tissue calculated by semiquantitative analysis was  $77.5 \pm 10.9\%$ .

**CONCLUSION:** Cerebral perfusion scintigraphy (SPECT images and dynamic scintigraphy) allows one to identify perfusion disturbances caused by the presence of intracranial AVM.

**Key words:** cerebral arteriovenous malformations, cerebral perfusion scintigraphy, SPECT, angiography

## Introduction

Arteriovenous malformations, colloquially referred to as angiomas, constitute 4% of intracranial tumours and are innate malformations of brain blood vessels in terms of their structure and function. They can be characterised by the presence of pathological arteriovenous connections with a high blood flow. These connections can be present in the form of direct fistulae between an artery and a vein, or a knot of distended and entangled blood vessels — the so-called nidus. It is possible to distinguish between several kinds of angiomas on the basis of their size, the type of vessel as well as their microscopic image. The aforementioned kinds include arteriovenous, arterial, venous, capillary, cavernous and other angiomas. From the clinical point of view, AVM manifests itself as an intracranial tumour (epileptic seizures, deficiency signs, increased intracranial pressure) or the first symptom of AVM can be intracranial (subarachnoid) haemorrhage. The medical treatment of AVM consists in removal or closure of the nidus by means of a surgical operation, embolization, or stereotactic radiotherapy with gamma rays. Very little relevant literature concern-

Correspondence to: Anna Nocuń  
Department of Nuclear Medicine  
Skubiszewski Medical University of Lublin, SPSK 4  
ul. Jaczewskiego 8, 20–954 Lublin, Poland  
Tel/fax: (+48 81) 72 44 389, e-mail: anna@nocun.com

ing the role of SPECT in the evaluation of the treatment results of brain arteriovenous malformations through intravascular embolization encouraged us to analyse the problem.

The aim of this study was to demonstrate scintigraphic evaluation of cerebral perfusion in patients with intracranial haemangiomas. Our report has a preliminary character and is planned to be a part of more comprehensive research, which will include further important aspects of this issue.

## Material and methods

Nineteen patients (9 women and 10 men) from the age of 12–67 years (the average age was 28.6 years) were studied. All the patients had been previously diagnosed with intracranial AVM and subsequently qualified for the intravascular embolization procedure. All the patients were in good clinical condition and had no symptoms of recent intracranial haemorrhage. In 10 patients the haemorrhage had been present in the past. For 16 patients it was to be the next embolization, 3 patients were also treated with gamma rays. In addition to this, 8 persons were treated because of epilepsy which was caused by the presence of AVM. In 2 cases angioma was located in cerebellum hemisphere, in the remaining cases it was situated supratentorially.

Brain scintigraphy was performed after the intravenous administration of  $^{99m}\text{Tc}$ -ECD (ethylcysteinate dimer) in doses from 491 to 925 MBq. The examinations were carried through with two-head gamma-camera VARICAM (GE Medical Systems), connected with dedicated computer system XpertPro. The activity above the head and neck was recorded immediately after the administration of the radioisotope and the acquisition was performed over a period of 1.5 minutes with the resolution of 2 seconds in anterior-posterior and posterior-anterior projections. Brain SPECT was carried out 20 minutes after radiotracer administration. Acquisition was performed, using high-resolution collimator,  $128 \times 128$

matrix, with one projection for each  $3^\circ$  in a  $360^\circ$  orbit for a total of 120 projections. The images were reconstructed with Metz filter and attenuation coefficient of 0.11.

SPECT images were analysed visually and based on semi-quantitative method with the help of the Compart program (Compart, Warsaw, Poland), which defined regions of interest in transverse intersections at the cerebellar level and supratentorially, dividing the cerebral cortex of each hemisphere into 6 sectors. The activity in a given sector was compared with the opposite side, and differences higher than 10% were considered as significant [1]. In the case of one patient with angioma located in the medial line of the body, regions were defined manually and the activity within the pathological change was compared with the region of normal brain tissue in its direct proximity. Radionuclide study was performed prior to angiography, which was followed by intravascular embolization.

Angiography was carried out under general anaesthesia with an injection into right femoral artery. A diagnostic catheter was introduced successively into each of the main brain arteries, a contrast medium was administered and angiographic images were obtained, using Siemens equipment (Multistar).

## Results

SPECT results are contained in Table 1 and angiographic results in Table 2. Figures 1–4 illustrate scintigraphic and angiographic changes in selected cases. The example of semiquantitative method is depicted by Figure 5.

In all cases, angiography showed the presence of brain angioma. Based on this examination the largest diameter of the angioma nidus was determined in each case. These varied from 1.0 cm to 9.0 cm (the average was 3.2 cm).

In the dynamic scintigraphy (DF, dynamic phase), AVM were visible in the first seconds of the acquisition, as the regions of

**Table 1. Results of scintigraphic imaging in patients with AVM**

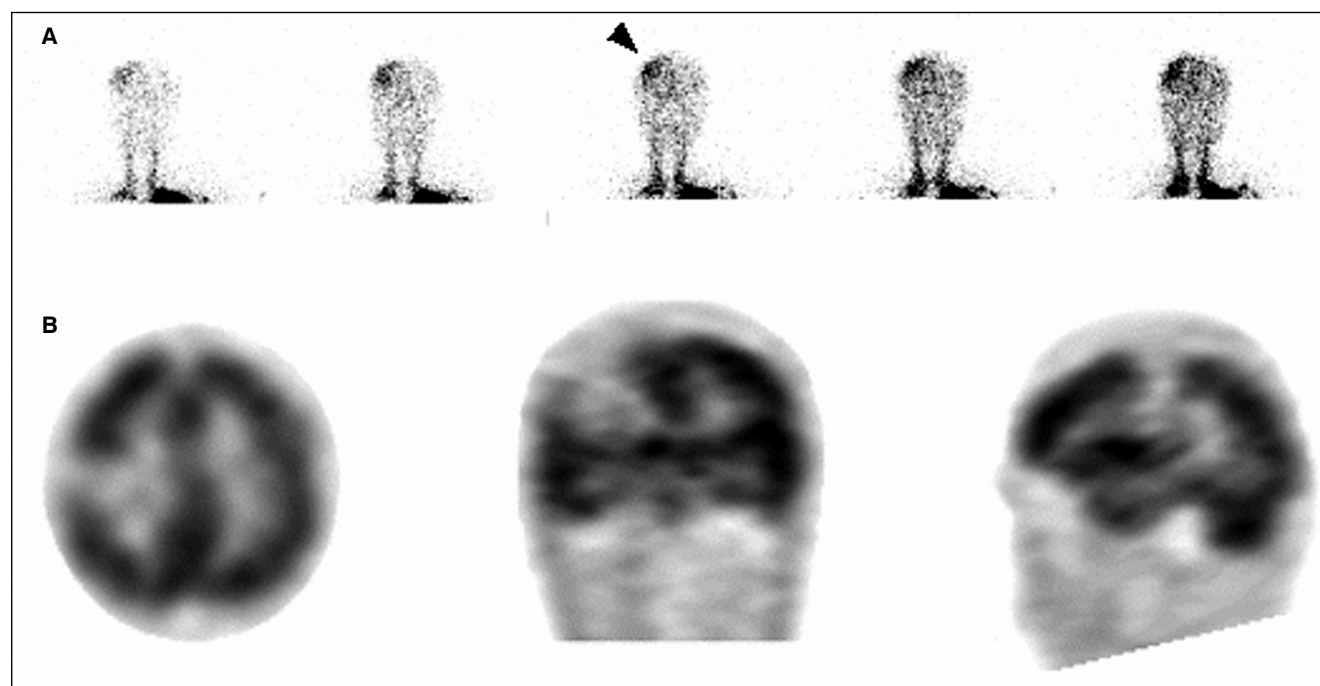
No.	Initials	Age [years]	Localization of AVM	Coefficient AVM/N	Number of sectors	Visualization in DF
1	TW	12	Left parieto-frontal region	52%	2	+
2	PP	17	Left cerebellar hemisphere	71%	1	+
3	KR	20	Central structures	73%	2	+
4	GK	50	Right temporal region	86%	2	-
5	DR	15	Right frontal region	87%	1	-
6	MA	24	Left fronto-temporal	60%	6	+
7	RK	52	Bilateral parietal region	89%	1	-
8	JW	16	Right thalamus	77%	3	+
9	DJ	18	Right parieto-occipital region	87%	2	+
10	TP	24	Right occipital region	89%	2	+
11	MS	26	Right parietal region	74%	1	+
12	HG	67	Right parietal region	70%	4	-
13	MK	13	Left fronto-temporal region	80%	1	+
14	KE	16	Left fronto-temporal region	69%	2	+
15	HZ	48	Left cerebellar hemisphere	85%	1	+
16	IR	25	Right parietal region	81%	1	-
17	PK	23	Right parietal region	66%	1	+
18	KL	49	Left temporal region	88%	1	-
19	GW	29	Right thalamus	89%	1	+

AVM/N — the ratio of activity in the AVM region to activity in normally perfused tissue; DF — dynamic phase

**Table 2. Angiographic findings in patients with AVM**

No.	Initials	Age [years]	The largest diameter of a nidus [cm]	Feeders of AVM
1	TW	12	1.5	LMCA
2	PP	17	3.5	LIPCA, LSCA
3	KR	20	6.0	BMCA, BACHa, BACA, BPCA
4	GK	50	1.5	RPCA
5	DR	15	2.0	RACA
6	MA	24	9.0	BACA, LMCA
7	RK	52	3.0	BACA
8	JW	16	2.0	RMCA
9	DJ	18	3.0	RMCA
10	TP	24	2.0	RPCA
11	MS	26	5.0	RMCA
12	HG	67	1.0	RMCA
13	MK	13	4.5	RMCA
14	KE	16	2.0	LMCA
15	HZ	48	2.0	LIPCA
16	IR	25	1.0	RMCA
17	PK	23	4.5	RMCA
18	KL	49	1.5	LPCA
19	GW	29	6.0	RMCA, BPCA

ACA — anterior cerebral artery; SCA — superior cerebellar artery; MCA — middle cerebral artery; AChA — anterior choroidal artery; PCA — posterior cerebral artery; R — right; L — left; B — bilateral; IPCA — inferior posterior cerebellar artery



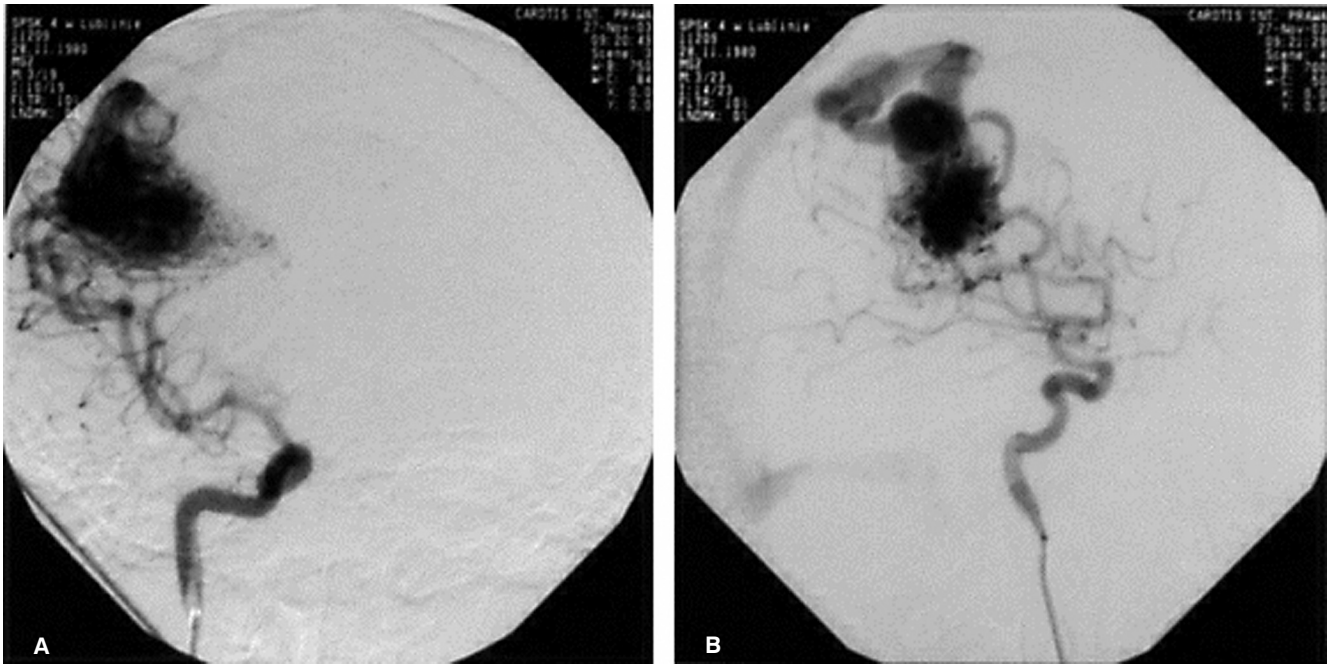
**Figure 1.** Scintigraphy in case 17. **A.** Dynamic phase in A-P projection, showing a site of increased activity in the right cerebral hemisphere (arrow); **B.** SPECT, showing hypoperfusion in the right fronto-parietal region.

increased accumulation of the isotope in 13 patients (68%), including the patients in whom the diameter of the nidus was smaller than 3 cm in 5 cases (50%) and in all cases of AVM larger than or equal with 3 cm. In each patient, SPECT examination showed the nidus of angioma as a region of decreased accumulation of the radiotracer.

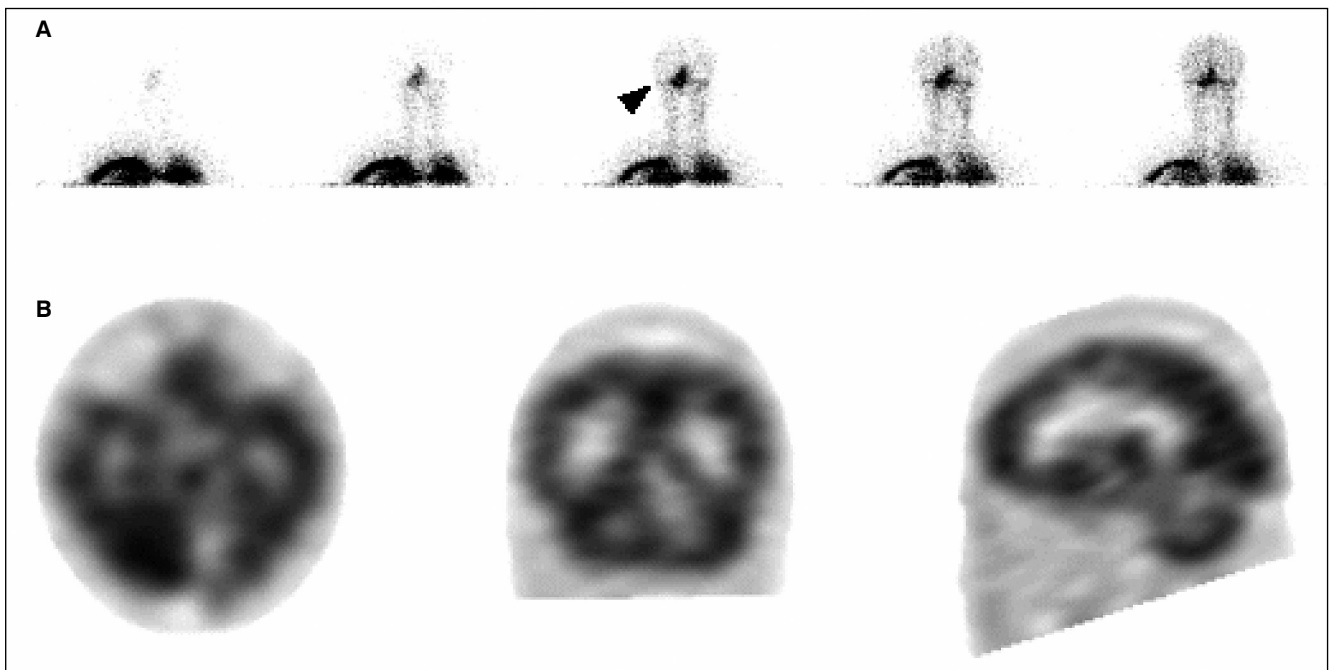
In 15 subjects (78%) (cases 1–4, 6, 8, 11–19) hypoperfusion of the adjacent region was observed, including all patients with

a pathological change larger than 3 cm in diameter. In one case (in a patient no. 6) with a change whose diameter was 9 cm a decreased perfusion in cerebellar hemisphere opposite the cerebral hemisphere with AVM was observed.

As far as semiquantitative evaluation is concerned, the activity in the changed region, expressed, as percentage ratio to the opposite side (AVM/N coefficient), varied from 52% to 89% (the average of  $77.5\% \pm 10.9\%$ ). In the case of the patient with a diag-



**Figure 2.** Right internal carotid angiograms in case 17, showing an AVM fed by the middle cerebral arterial branches. **A.** A-P projection; **B.** Lateral projection.



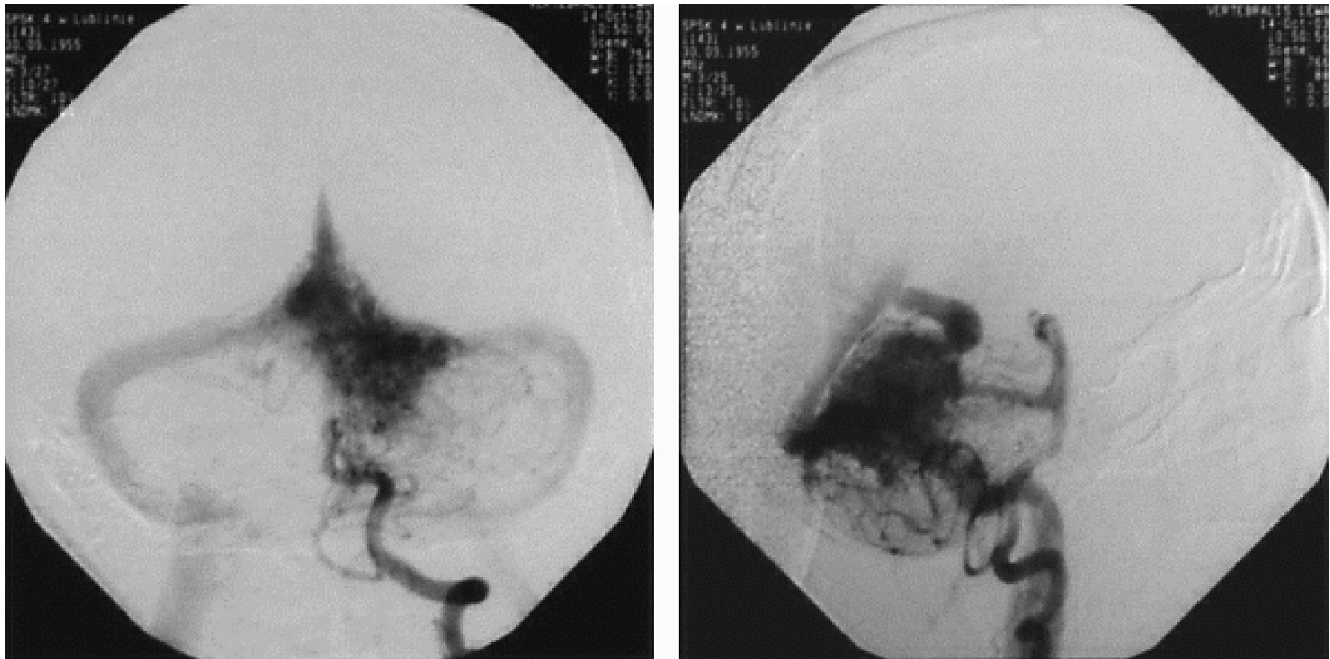
**Figure 3.** Scintigraphy in case 15. **A.** A region of increased activity (arrow) in the left cerebellar hemisphere is seen in dynamic phase (projection P-A); **B.** Hypoperfusion in the left cerebellar hemisphere in SPECT.

nosed cerebellar diaschisis, the blood flow in the cerebellar hemisphere contralateral to angioma was 87% of the blood flow in the other cerebellar hemisphere.

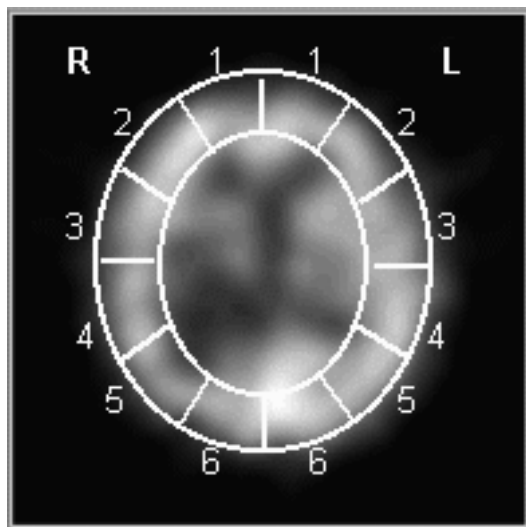
### Discussion

Arteriovenous angiomas are characteristic for the decreased resistance of blood flow which in consequence results in stealing

blood from the healthy parts of the brain, where blood flow resistance in capillary vessels is higher. The regions of decreased perfusion may be present in the closest proximity of angioma or in a remote region in the same or opposite hemisphere [2]. As a consequence of surgical treatment or embolization, in the region with disturbed autoregulation, normalisation of the blood flow or various degrees of hyperemia may be observed [2–5]. The visualization of blood flow redistribution proves to be very signifi-



**Figure 4.** Left vertebral angiograms in case 15, showing an AVM fed by the branches of the inferior posterior cerebellar artery. **A.** A-P projection; **B.** Lateral projection.



R	1	2	3	4	5	6
AVM/N	0.97	1.00	0.89	0.73	0.70	0.82

**Figure 5.** Regions of interest in case 12, dividing the cerebral cortex of each hemisphere into 6 sectors. Perfusion in the right sectors 3–6 is significantly decreased, compared with the left hemisphere. AVM/N — the ratio of activity in the AVM region to activity in normally perfused tissue.

cant in the post-surgical treatment of a patient and in the planning of the next stage of angioma treatment, especially because of adverse consequences of hyperperfusion in the form of cerebral oedema and intracranial haemorrhage. Perfusion brain scintigra-

phy is a non-invasive method which allows safe diagnosis of the disturbances of brain blood flow. The usefulness of this method for the imaging of ischaemia and hyperaemia in AVM was described in a number of papers [2–6]. The necessity to confirm in follow-up study the remission of hyperaemia, diagnosed by SPECT performed after embolization and before the next phase of embolization or surgical operation, is particularly emphasised, as it allows to avoid disastrous complications. SPECT constitutes a complementary method to angiography. Angiography enables decision-making as to the choice of treatment and which highlights all elements of angioma: blood-supplying arteries, the nidus of angioma and the veins carrying blood from it. In this examination, the stealing phenomenon is characterised by a worse filling of contrasting agent in other arteries in the region of the same blood vessel system where angioma is present. In angiography of the arteries opposite to angioma, this “stealing” may cause the blood vessels close to AVM or angioma itself to be filled with blood by communicating arteries.

In the group examined by us, all AVM were recognisable as regions of decreased accumulation of radiotracer. No disturbances in the blood flow in the opposite cerebral hemisphere were observed. In the case of one patient, there was ischaemia of the cerebellar hemisphere located opposite to angioma (diaschisis cerebellaris). This symptom is defined as a reduction in the metabolism and blood flow in the cerebellar hemisphere contralateral to a supratentorial cerebral lesion, such as a malignant tumour, infarction, intracranial haematoma, or angioma [7, 8]. Brain injuries of different causes can impair neuronal impulses and interrupt connections (corticopontocerebellar pathway is said to be commonly involved) with other cerebral regions, which may be distant from the original lesion. Cerebral regions receiving poor afferent signals become hypo-functioning, decrease their metab-

olism and appear as low-uptake areas in SPECT images [8]. The most commonly seen pattern of this phenomenon-crossed cerebellar diaschisis, was present in only one examined patient with the largest of all lesions.

In 15 cases hypoperfusion of the region adjacent to the nest was observed. Since no CT or MRI studies were carried out, it is not possible to ascertain whether the region of hypoperfusion observed in SPECT in the vicinity of angioma nidus was a result of structural or functional changes. Disturbances of perfusion determined by SPECT greater than structural changes in CT and MRI are described in papers, where the above-mentioned techniques were used simultaneously [2, 5, 9]. This proves SPECT to be useful in the planning of treatment, predicting complications and controlling therapy in the case of surgery and embolization as well as radiosurgical procedures. There are reports which have confirmed the high sensitivity of angioscintigraphy in the evaluation of the remission of changes after the use of the aforementioned treatment method [10].

## Conclusions

The above-mentioned report is of preliminary character. However, it allows one to draw the following conclusions:

1.  $^{99m}\text{Tc}$ -ECD SPECT imaging can be used to assess the perfusion disturbances (on the level of capillary blood vessels) in the area adjacent to the AVM nidus and also in the case of remotely located brain structures.
2. The dynamic phase of scintigraphic examination provides additional information on the dynamics of blood flow through the nidus of AVM, especially in the case of large lesions.

## References

1. Tash K, Asenbaum S, Bartenstein P et al. European Association of Nuclear Medicine procedure guideline for brain perfusion SPECT using  $^{99m}\text{Tc}$  labelled radiopharmaceuticals. *Eur J Nucl Med*. 2002; 29: 36–42.
2. Takeuchi S, Abe H, Nishimaki K et al. Cerebral haemodynamic changes after endovascular treatment of arteriovenous malformations. *Acta Neurochirurgica* 1994; 127: 142–150.
3. Ogasawara K, Yoshida K, Otawara Y et al. Cerebral blood flow imaging in arteriovenous malformations complicated by normal perfusion pressure breakthrough. *Surg Neurol* 2001; 56: 380–384.
4. Kuroda S, Ushikoshi S, Moukin K et al. Postoperative hyperperfusion in dural arteriovenous fistula associated with venous ischaemia: case report. *Surg Neurol* 1998; 49: 406–411.
5. Takeshita G, Toyama H, Nakane K et al. Evaluation of cerebral blood flow changes on perifocal brain tissue SPECT before and after removal of arteriovenous malformations. *Nucl Med Commun* 1994; 15: 461–468.
6. Bloom M, Jacobs S, Pile-Spellmann J et al. Cerebral SPECT imaging: effect on clinical management. *J Nucl Med* 1996; 37: 1070–1073.
7. Leo G, Flores I, Futami S, Hoshi H et al. Crossed Cerebellar Diaschisis: Analysis of Iodine-123-IMP SPECT imaging. *J Nucl Med* 1995; 36: 399–402.
8. Catafau AM. Brain SPECT in clinical practice. Part I: Perfusion. *J Nucl Med* 2001; 42: 259–271.
9. Fukumitsu N, Tsuchida D, Ogi S, Uchiyama M, Mori M et al. Dynamic and static cerebral perfusion scintigraphy of cerebral arteriovenous malformations. *Clin Nucl Med* 2003; 28: 64–65.
10. Leber K, Aigner R, Nicoletti R et al. Dynamic and static evaluation of cerebral arteriovenous malformations to evaluate radiosurgical treatment. *Stereotact Funct Neurosurg* 1996; 66 (Suppl 1): 269–277.