

Screening for acute myocarditis — is scintigraphy with ^{99m}Tc -Anti- -Granulocyte BW 250/183 an answer?

Alicja Hubalewska¹, Dariusz Dudek², Jacek Dubiel²,
Ewa Płaczekiewicz-Jankowska¹, Bohdan Huszno¹,
Anna Staszczak¹, Wiesław Frasiak³

¹Nuclear Medicine Unit, Chair and Department of Endocrinology

²2nd Department of Cardiology, Institute of Cardiology *Collegium Medicum*, Jagiellonian University, Krakow, Poland

³Pathomorphology Department, The John Paul II Hospital, Krakow, Poland

[Received 4 VI 2004; Accepted 24 XI 2004]

Abstract

BACKGROUND: Myocarditis is most often caused by Coxsackie B virus, influenza viruses, and echoviruses. It is usually self-restricting and ending in full recovery, but in some patients the infection leads to congestive cardiomyopathy. It is difficult to identify patients with myocarditis using clinical criteria, laboratory tests, ECG and ultrasonography, and currently a myocardial biopsy is required to establish the diagnosis. The risk of complications, sampling error and costs of this procedure underline the need of non-invasive but sensitive methods of imaging. Several radiopharmaceuticals have been used so far to confirm inflammation: ^{67}Ga , ^{99m}Tc -nanocolloids and ^{111}In -leucocytes. Scintigraphy with radiolabeled autologous white blood cells (WBCs) is considered a very useful method in identifying sources of inflammation but is difficult to perform and time-consuming.

AIMS: The aim of our study was to investigate whether scintigraphy with ^{99m}Tc -Anti-Granulocyte BW 250/183 antibody is a valuable diagnostic method in evaluating focal and diffuse

inflammation of the heart and could therefore be suggested for use in screening for acute myocarditis.

MATERIAL AND METHODS: A two dimensional scintigraphy and SPECT mode of heart imaging with the use of ^{99m}Tc -Anti-Granulocyte antibody (740 MBq) was performed on 14 subjects (11 males and 3 females) aged 25–60 years with a positive myocardial biopsy confirming an inflammatory process in the myocardium. After i.v. administration of the tracer a 1 minute series of planar scans was performed within the first 60 minutes. Delayed static scans were performed at 1, 2, 4 and 24 hours. **RESULTS:** The scintigraphic scans revealed the uptake of the tracer in the heart area in 13 patients, confirming active inflammatory process. Follow-up scintigraphy was performed 3–5 months after the first study, when the control myocardial biopsy was negative. The results of the study showed the concordance between myocardial biopsy and scintigraphy results in patients with an inflammatory process in the heart.

CONCLUSIONS: Scintigraphy with the use of ^{99m}Tc -Anti-Granulocyte seems to be a useful diagnostic method in evaluating patients with suspected myocarditis, but further studies are needed to establish its sensitivity and specificity.

Keywords: ^{99m}Tc -Anti-Granulocyte BW 250/183 antibody, myocardial inflammation, myocarditis, scintigraphy, myocardial biopsy

Introduction

Definite histopathologic evidence of acute myocardial inflammation is obtained in only 10% of patients presenting signs and symptoms of unexplained cardiomyopathy [1]. Clinical diagnosis of myocarditis is usually very difficult due to varying clinical presentation ranging from asymptomatic cases to fatal acute heart insufficiency. Diminished physical performance, fatigue, palpitations and shortness of breath predominate, but in some patients malignant ventricular arrhythmias might be the leading symptoms. Enzyme assays as well as immunologic tests have proved a weak correlation with the disease's severity and may even be negative in some cases. The lack of a definite clinical picture of the disease, non-specific laboratory tests and non-specific electrocardiographic and echocardiographic findings obscure the diagnosis.

Correspondence to: Alicja Hubalewska
Chair and Department of Endocrinology Nuclear Medicine Unit
Collegium Medicum, Jagiellonian University
ul. Kopernika 17, 31–501 Krakow, Poland
Tel: (+48 12) 424 75 11, fax: (+48 12) 424 73 99
e-mail: alahuh@endo.cm-uj.krakow.pl

Viral infections are the main etiological factors in Europe and North America [2], and include Coxsackie viruses, adenovirus and echovirus, while in South America the disease is most often caused by parasite infection – known as Chagas disease. Acute myocarditis infrequently develops during viral epidemics. Inflammatory process may involve cardiomyocytes, interstitial tissue and connective tissue at varying degrees, and rarely the large epicardial vessels. Heart involvement in the inflammatory process is most often focal, but may also be heterogeneous or diffuse. In most cases it is a self-restricting process ending in full recovery. It remains unclear why in some patients the infection leads to congestive cardiomyopathy.

There is a hypothesis that the destruction and fibrosis of the myocardium are a consequence of an immunological reaction to viral particles. The reaction is caused by cross-reaction of antigen structures of viruses and cells of the myocardium. The presence of AMLA-IgM, ASA-IgM, and IgM in a myocardial biopsy sample was shown in 70–80% of cases of acute myocardial inflammation. Viruses are usually eliminated from cardiac tissue within 2–3 weeks [3], but incomplete virus elimination results in persistent inflammation that further stimulates an autoimmune process leading to the progressive destruction of cardiomyocytes and the development of congestive heart disease [4, 5].

Currently, a myocardial biopsy is required to establish the diagnosis of acute myocarditis. This biopsy is an invasive procedure that carries a certain risk of complication [6], and the cost of the procedure is relatively high. Therefore, a new diagnostic technique for the early and non-invasive evaluation of myocarditis has been long awaited. Current methods of myocardial biopsy may be inadequate to detect the presence of inflammation, and the results may be false negative, especially in cases of focal disease, which appears to be more frequent than disperse inflammation. Since sampling errors makes the test insensitive in such cases, additional methods of evaluation are needed.

For many years, new sensitive methods of non-invasive detection of inflammatory processes in the heart have been sought and the techniques of its scintigraphic detection have been improved [7, 8]. All inflammatory processes typically involve increased blood supply, the leakage of fluid, small molecules and proteins, and the infiltration of cells. Scintigraphic imaging of inflammation can be achieved in various ways, depending on which aspect of the inflammatory process is to be addressed. Non-specific markers (e.g. radiolabeled non-specific immunoglobulins or liposomes) accumulate due to locally enhanced blood supply and vascular permeability. It should be noted that all radiopharmaceuticals tend to accumulate to some extent in such non-specific ways. Specific markers of inflammation are obtained by radiolabeling white blood cells isolated from the patient (which are further reinjected) or by directly targeting leukocyte antigens or receptors.

For almost two decades, ^{111}In has been the primary radionuclide used to label leukocytes for imaging areas of suspected inflammation. The diagnostic procedure using $^{99\text{m}}\text{Tc}$ radiolabeled autologous blood cells (WBCs) is laborious and time-consuming. Isotope imaging studies with the use of labeled antigranulocyte monoclonal antibodies that are now available due to the rapid development of immunological technologies hold the promise of

the non-invasive highly sensitive diagnosis of myocarditis. The techniques for radiolabeling with $^{99\text{m}}\text{Tc}$ have become available [8, 9] and are being more widely used in many centres: e.g. $^{99\text{m}}\text{Tc}$ -labeled monoclonal antibody Fab'-fragments [$^{99\text{m}}\text{Tc}$ -anti-NCA-90 IMMUMN3; LeukoScan®] or $^{99\text{m}}\text{Tc}$ -labeled monoclonal specific antibody [$^{99\text{m}}\text{Tc}$ -anti-CEA-NCA-95 BW 250/183; Anti-Granulocyte], which we used in our study. In addition, a wide variety of peptides binding to leukocyte receptors have been investigated, including cytokines such as interleukin-1, interleukin-2, interleukin-8, derivatives of platelet factor 4, and complementary factors such as C5a [9].

The aim of the study was to investigate whether scintigraphy with $^{99\text{m}}\text{Tc}$ -Anti-Granulocyte is a valuable diagnostic method in evaluating focal and diffuse inflammation of the heart and therefore could be suggested in screening for acute myocarditis. An additional aim of the study was to establish the optimal acquisition procedure in the studies using $^{99\text{m}}\text{Tc}$ -Anti-Granulocyte which is a new tracer employed in the scintigraphic evaluation of the heart.

Material and methods

Heart scintigraphy with the use of $^{99\text{m}}\text{Tc}$ -Anti-Granulocyte BW 250/183 antibody, manufactured by CIS BIO INTERNATIONAL (Gif-sur-Yvette, France), was performed in 14 subjects (11 males and 3 females) aged 25–60 years (mean 44.8 ± 10.7 years) with a positive myocardial biopsy confirming an inflammatory process in the heart. None of the patients studied received any anti-inflammatory treatment prior to the scintigraphic assessment. All of the patients included in the study presented signs and symptoms of heart insufficiency and they were hospitalised in the Department of Cardiology due to aggravating heart failure. Left ventricular ejection fraction (LVEF) was 14–42% (mean $25\% \pm 10.4\%$) at the beginning of the study. General hypokinesis of the heart was found using echocardiography. Coxsackie virus infection was confirmed in 8 of the patients by serological studies.

Histopathological classification was based on the Dallas criteria [10] and proved an active inflammatory process in twelve of the patients, with myocarditis defined as myocardial necrosis, degeneration, or both, in the absence of significant coronary artery disease with an adjacent inflammatory infiltrate with or without fibrosis. Borderline myocarditis was found in two remaining patients (i.e. the inflammatory infiltrate too sparse or the myocyte damage not apparent).

Heart scintigraphy with the use of $^{99\text{m}}\text{Tc}$ -Anti-Granulocyte BW 250/183 was performed in all patients using a double-head gamma camera (E-Cam, Siemens, Erlangen, Germany) equipped with high resolution collimators. A radiotracer of 740 MBq (20 mCi) activity was given intravenously. Following the administration of the radiotracer a 1 minute series of planar scans were performed within the first 60 minutes. Delayed static scans were performed at 1, 2, 4 and 24 hours. In ten of the fourteen patients, the $^{99\text{m}}\text{Tc}$ -Anti-granulocyte scintigraphy was repeated 3–5 months after the first study, when the control myocardial biopsy was negative (anti-inflammatory drugs were discontinued before that scintigraphy). Three of the four patients not tested had not given their consent to be examined, including the patient with a negative result from the first test, and one patient died.

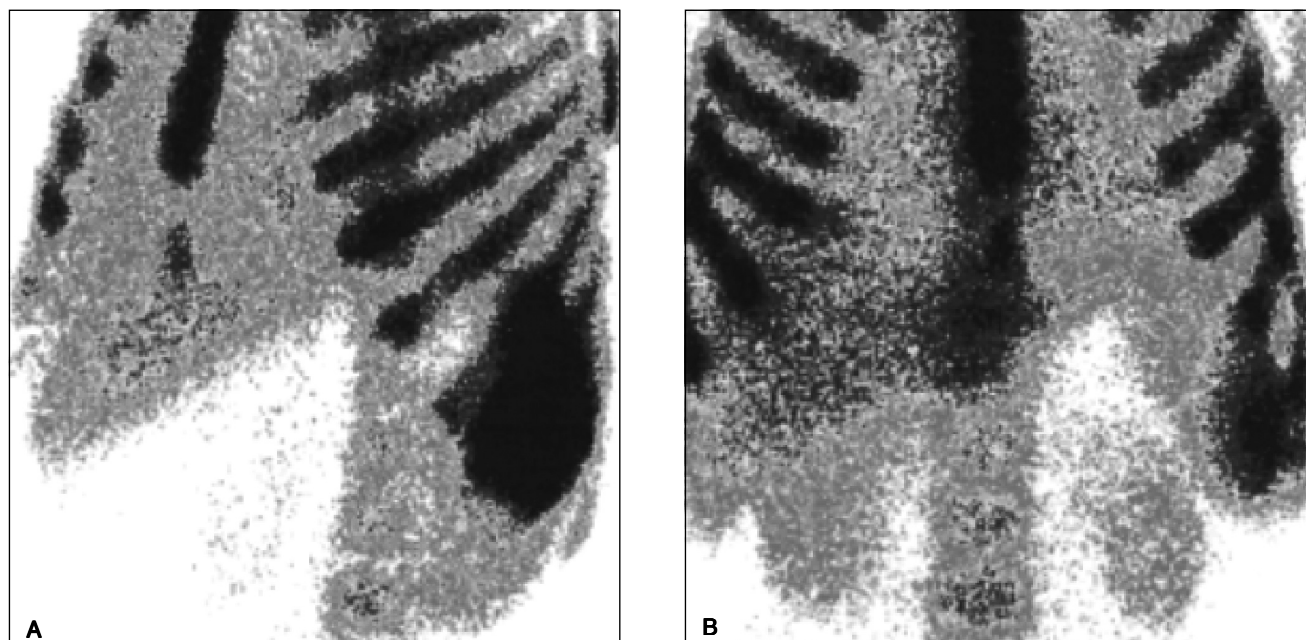


Figure 1. Positive result of two-dimensional scintigraphy with ^{99m}Tc -Anti-Granulocyte BW 250/183. The scintigraphy revealed accumulation of the tracer in cardiac area. **A.** Anterior view; **B.** LAO45 view.

Results

The first scintigraphic scan revealed the uptake of the tracer in the heart area in 13 patients, confirming an active inflammatory process. The patients were diagnosed with myocarditis and treated accordingly with anti-inflammatory drugs. An increase of LVEF (20–63%; mean value — $33 \pm 13.2\%$) was noted in echocardiographies in all patients. A check-up scintigraphy with the use of ^{99m}Tc -Anti-Granulocyte BW 250/183 was performed again in ten patients after the resolution of all clinical symptoms of myocarditis accompanied by negative results of a myocardial biopsy. The scintigraphy revealed no abnormalities in nine of them and detected the uptake of the tracer in the heart area in one patient, with the accumulation of ^{99m}Tc -Anti-Granulocyte in the postero-inferior wall of the heart. In the latter patient, the myocardial biopsy that was negative had been taken from the anterior wall. A further scintigraphic examination performed three months later proved negative in this patient.

No hypersensitivity reactions after the intravenous injection of ^{99m}Tc -Anti-Granulocyte BW 250/183 were observed. Static scans taken 1 and 2 hours following administration of the tracer did not add any important information to the study. Delayed static scans performed at 4 and 24 hours were found to be most useful. One of the positive results of ^{99m}Tc -Anti-granulocyte BW 250/183 scintigraphy is presented in Figure 1.

Discussion

It remains controversial whether myocardial biopsy should be performed routinely in all cases of suspected myocarditis as it is an invasive method carrying a risk of complications. We believe, that scintigraphy with ^{99m}Tc -Anti-Granulocyte BW 250/183 is an interesting method that is safe and accurate enough to be con-

sidered a screening tool for testing patients with suspected myocarditis before a decision on myocardial biopsy is made. It might be of special value in those patients in whom traditional methods have yielded equivocal data.

Many radiopharmaceuticals have been used so far to confirm the inflammatory process in the heart: $^{67\text{m}}\text{Ga}$, $^{99\text{m}}\text{Tc}$ -nanocolloid, ^{111}In -leucocytes, ^{111}In -Oxine, MIBG and autologous antibodies against myosin labeled with ^{111}In (^{111}In -Mioscint — antimyosin monoclonal antibody). Scintigraphy applied to the use of antimyosin monoclonal antibody has been a valuable and sensitive method in evaluating myocarditis [11, 12], but is no longer available as ^{111}In indium-labeled antimyosin is not produced anymore due to economic reasons. One of the antimyosin studies revealed myocarditis to be present in 10% of patients with unexplained myocarditis [13]. In certain cases of viral infection the inflammatory process in the heart may not cause the damage of cardiomyocytes. The results of scintigraphy with the use of antimyosin monoclonal antibody might therefore be negative in such cases regardless the active inflammation.

The use of radiolabeled leukocyte scintigraphy is nowadays a routine procedure in most nuclear medicine departments for the investigation of different inflammatory pathologies involving leukocytic infiltration [14–16]. It could be performed either by radiolabeling white blood cells isolated from the patient which is a very demanding procedure, or preferably by directly targeting leukocyte antigens or receptors [7–9]. Agents which preferentially bind to granulocytes are most suitable for visualising the site of acute inflammation. The most widely used and described one is LeukoScan (with ^{99m}Tc -labeled monoclonal antibody Fab'-fragments) scintigraphy. The radiolabeled antibody molecule is small, only a Fab' fragment with one binding arm and devoid of the immunogenic Fc portion of the immunoglobulin, and reactive with a granulocyte surface antigen, NCA90 [16]. There are numerous

reports in medical journals of the usefulness of this marker in the diagnosis of various inflammatory processes most often in bones and joints [18, 19], as well as in abdominal tissues and of its use in seeking unknown source of infection [20]. In heart studies, this marker has successfully been used to confirm the inflammation localised in heart valves and around the endomyocardial electrode — pacemaker electrode tip infection [17]; and has proved useful in confirming inflammatory infiltration after transmyocardial laser revascularisation (TMLR). There is not much data available so far on the application of this marker in the diagnosis [21] and monitoring of myocarditis.

The tracer we used in the study — ^{99m}Tc -Anti-Granulocyte BW 250/183 (^{99m}Tc -labeled monoclonal CEA-NCA specific antibody) is another marker employed in the diagnosis of inflammatory processes. It is similar to LeucoScan and easy to prepare compared with previously the most often used autologous leukocytes labeled with ^{111}In . It reacts with more than 90% of granulocytes in the peripheral blood as well as with granulocytes in the bone marrow but does not impair granulocyte function, and the investigation has no effect on blood granulocyte count. The indications for the use of this radiolabeled molecule include immunoscintigraphy of inflammation (including the skeleton, the intestinal tract and other soft tissues and organs) and immunoscintigraphy of red bone marrow. The results of our study showed this method to be sensitive in determining myocarditis compared with the results of myocardial biopsy. We believe it might also be used to monitor the severity and extent of an inflammatory process in the heart without the need of further control biopsies. Nevertheless further studies involving greater numbers of patients are needed before definite conclusions can be drawn and new clinical recommendations made. Further indications for the test should be searched for, and if its high sensitivity is confirmed it might also be considered in evaluating patients with clinical presentation of myocardial infarction and normal coronary angiograms if myocarditis is suspected [22–23]. Another group of patients that could benefit from this test are those with vague clinical symptoms of myocarditis, which might be obscured by the presence of severe coronary artery disease [24]. The wider use and usefulness of this technique is yet to be established by further carefully planned studies recruiting patients in whom scintigraphy with ^{99m}Tc -Anti-Granulocyte BW 250/183 could help in establishing the diagnosis and therefore improve outcomes.

Conclusions

The results of the study showed the concordance between myocardial biopsy and scintigraphy results in patients with an inflammatory process in the heart. Therefore, scintigraphy with the use of ^{99m}Tc -Anti-Granulocyte seems to be a useful diagnostic method in evaluating patients with suspected myocarditis, but further studies are needed to assess its sensitivity and specificity.

An additional aim of the study was to establish an optimal acquisition procedure in scintigraphic studies using ^{99m}Tc -Anti-Granulocyte antibody in the evaluation of the heart. Based on our results, it seems to be indicated that delayed static scans should be performed after 4 and 24 hours following the administration of the tracer. Performing both planar and SPECT techniques of data acquisition is most useful in providing scans yielding the most

accurate interpretation. The wider use and usefulness of this technique is yet to be established by further carefully planned studies recruiting patients in whom scintigraphy with ^{99m}Tc -Anti-Granulocyte BW 250/183 antibody could facilitate diagnosis and therefore improve outcomes.

References

1. Mason JW, O'Connell JB. Clinical merit of endomyocardial biopsy. *Circulation* 1989; 79: 971–979.
2. Kandolf R, Hofschneider PH. Viral heart disease. *Springer Semin Immunopathol*, 1989; 11: 1–13.
3. Martino TA, Liu P, Sole MJ. Viral infection and the pathogenesis of dilated cardiomyopathy. *Circ Res*, 1994; 74: 182–188.
4. McManus BM, Kandolf R. Evolving concepts of cause, consequence and control in myocarditis. *Curr Opin Cardiol* 1991; 6: 418–427.
5. Barry W. Mechanisms of immune-mediated myocyte injury. *Circulation*; 1994; 89: 2421–2432.
6. Deckers JW, Hare JM, Baughman KL. Complications of transvenous right ventricular endomyocardial biopsy in adult patients with cardiomyopathy: a seven-year survey of 546 consecutive diagnostic procedures in tertiary referral center. *J Am Coll Cardiol* 1992; 19: 43–47.
7. Becker W, Goldenberg DM, Wolf F. The use of monoclonal antibodies and antibody fragments in the imaging of infectious lesions. *Semin Nucl Med* 1994, 2: 142–153.
8. Coleman RE, Datz FL. Detection of inflammatory disease with radiolabeled cells. *Diagnostic Nuclear Medicine*. 4th Edition. Lippincott Williams and Wilkins. A Wolters Kluwer Company, Philadelphia 2003.
9. Rennen HJ, Boerman OC, Oyen WJ, Corstens FH. Scintigraphic Imaging of Inflammatory Processes. *Med Chem Rev*, 2004, 1, 27–38.
10. Aretz HT. Myocarditis: the Dallas criteria. *Hum Pathol* 1987; 18: 619–624.
11. Narula L, Malhotra A, Yasuda T et al. Usefulness of antimyosin antibody imaging for the detection rheumatic myocarditis. *Am J Cardiol* 1999; 84: 946–950.
12. Lauer B., Kuhl U., Souvatzoglou M., Vosberg H., Schultheiss HP. Antimyosin scintigraphy for diagnosis and follow-up of patients with clinically suspected myocarditis. *Z Kardiol* 1998; 87: 691–698.
13. Dec GW, Palacios I, Yasuda T et al. Antimyosin antibody cardiac imaging: its role in the diagnosis of myocarditis. *J Am Coll Cardiol* 1990; 16: 97–104.
14. Becker W. The contribution of nuclear medicine to the patient with infection. *Eur J Nucl Med* 1995; 22: 1195–1211.
15. Chianelli M, Mather SJ, Martin-Comin J, Singapore A. Radiopharmaceuticals for the study of inflammatory process: a review. *Nucl Med Commun* 1997; 18: 437–455.
16. Corstens FHM, van der Meer JWM. Nuclear Medicine: nuclear medicine's role in infection and inflammation. *Lancet* 1999; 354: 765–770.
17. Gratz S, Becker W. Infection scintigraphy with ^{99m}Tc -labeled monoclonal antibody Fab'-fragments (LeukoScan). Zuckschwerdt Verlag, Munchen, Bern, Wien, New York 1999.
18. Harwood SJ, Camblin JG, Hakki S et al. Use of technetium antigranulocyte monoclonal antibody Fab' fragments for the detection of osteomyelitis. *Cell Biophysics*, 1994; 24/25: 99–107.
19. Becker W, Bair J, Behr T et al. Detection of soft-tissue infections and osteomyelitis using a technetium-99m-labeled anti-granulocyte monoclonal antibody fragment. *J Nucl Med* 1994; 35: 1436–1443.
20. Becker W, Palestro CJ, Winship J et al. Rapid imaging of infections with a monoclonal antibody fragment (LeukoScan). *Clin Orthop* 1996; 329: 263–272.
21. Gratz S, Raddatz D, Hagenah G, Behr T, Behe M, Becker W. ^{99m}Tc -labeled antigranulocyte monoclonal antibody FAB'-fragments versus echocardiography in the diagnosis of subacute infective endocarditis. *Intern Journ Cardiol*, 2000; 75: 75–84.

22. Sarda L, Colin P, Boccarda F et al. Myocarditis in patients with clinical presentation of myocardial infarction and normal coronary angiograms. *J Am Coll Cardiol* 2001; 37: 786–792.
23. Vilain D, Collet JP, Sarda L, Choussat R, Montalescot G, Farragi M. Acute myocarditis presenting as acute myocardial infarction and sudden death with complete atrioventricular block: value of antimyosin scintigraphy. *J Nucl Cardiol* 1999; 6: 547–548.
24. Kwok OH, Chau EM, Wang EP, Chow WH. Coronary artery disease obscuring giant cell myocarditis — a case report. *Angiology* 2002; 53: 599–603.

