

# Usefulness of $^{99m}\text{Tc}(\text{V})$ - -dimercaptosuccinic acid scintigraphy in the assessment of response to external radiation therapy in soft tissue sarcoma in Giant Schnauzer dog

Pradip R. Chaudhari<sup>1</sup>, Domokos Mathe<sup>2</sup>, Lajos Balogh<sup>2</sup>,  
Gabor Andocs<sup>2</sup>, Gyozo A. Janoki<sup>2</sup>

<sup>1</sup>Laboratory Nuclear Medicine Section, Bhabha Atomic Research Centre,  
Tata Memorial Centre Annex, Mumbai, India

<sup>2</sup>Department of Applied Radioisotopes, Frederic Joliot-Curie National  
Research Institute of Radiobiology and Radiohygiene, Budapest, Hungary

[Received 15 VII 2005; Accepted 26 VII 2005]

## Abstract

A nine-year-old male black Giant Schnauzer dog was referred for the scintigraphic evaluation with a history of malignant fibrosarcoma with a rapidly growing non painful mass on the left shoulder region quite near to the site of an operation performed four months ago. We carried out oncological scintigraphy using pentavalent  $^{99m}\text{Tc}$  labelled dimercaptosuccinic acid [ $^{99m}\text{Tc}(\text{V})$ -DMSA], a tumour localising radiopharmaceutical agent. The study was performed to assess the margins, vascularity of the tumour and response to the cancer therapy. Uniform intense radiopharmaceutical uptake was observed in the lesion indicating its margins, vascularity and malignant nature. The dog was subjected to

external radiation therapy to control the growth of the cancer and to bring the tumour mass to an operable size. The dog was followed up with  $^{99m}\text{Tc}(\text{V})$ -DMSA scintigraphy pre-irradiation and post-irradiation. Immediately after the post-irradiation scintigraphy, the dog was operated on. During the surgery, resection of the tumour margins was performed carefully using a hand held gamma probe to assure that no tumour tissue was left inside. In conclusion, the authors would like to state that  $^{99m}\text{Tc}(\text{V})$ -DMSA oncoscintigraphy is valuable in the assessment and evaluation of therapy in canine soft tissue cancer.

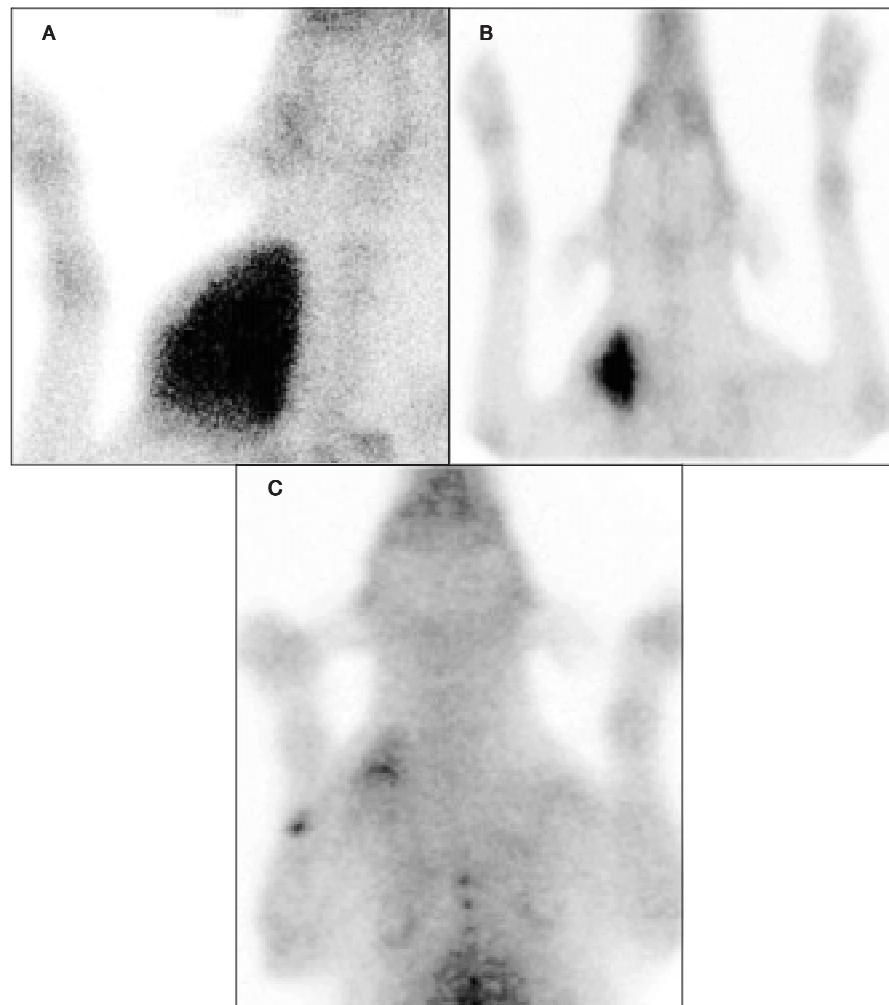
**Key words:**  $^{99m}\text{Tc}(\text{V})$ -DMSA canine cancer, scintigraphy

## Introduction

Cancer incidence in dogs is quite high; mainly in the form of osteosarcoma, breast carcinoma and other soft tissue tumours like fibrosarcoma and mastocytoma. Cancer detection and its management is an important aspect in animal cancers. Scintigraphy has been in routine use for the detection and management of a variety of cancers in human beings. Scintigraphy for animal cancer management is uncommon and very few centres are involved in this work.

$^{99m}\text{Tc}(\text{V})$ -DMSA is a diagnostic radiopharmaceutical agent for soft tissue cancer. It has been reported with good efficacy in diagnosis of primary site, its size and metastatic lesions in soft tissue tumours in humans [1, 3, 10]. Papantoniou et al. have shown that DMSA scintimammography has an advantage and could improve the detection of non-palpable in situ breast carcinomas [9]. Similarly, Kiratli et al. and Wang et al. found applicability with good detection sensitivity of  $^{99m}\text{Tc}(\text{V})$ -DMSA for hepatocellular carcinoma and retinoblastoma respectively [6, 11]. Ohta et al. repor-

*Correspondence to:* Pradip R. Chaudhari  
Laboratory Nuclear Medicine Section, Bhabha Atomic Research Center  
Tata Memorial Center Annex  
Mumbai-400 012, India  
Tel: +91 2224149428, fax: +91 222457098  
e-mail: pradipchaudhari@hotmail.com



**Figure 1.**  $^{99m}\text{Tc(V)}$ -DMSA scintigraphy **A.** Pre RT **B.** Post RT; **C.** Post operation.

ted that  $^{99m}\text{Tc(V)}$ -DMSA could demarcate the lesion well and was useful in following up recurrent extra abdominal fibromatosis [8]. There are several reports regarding the sensitivity of  $^{99m}\text{Tc(V)}$ -DMSA scintigraphy in medullary thyroid carcinoma [7]. Hirano et al. suggests the clinical utility of  $^{99m}\text{Tc(V)}$ -DMSA in imaging primary brain tumours and differentiating their histological malignancy grade non-invasively [4]. Kobayashi et al. found that low-grade malignant and highly recurrent benign lesions, which often recur after surgery, were detected more accurately with  $^{99m}\text{Tc(V)}$ -DMSA Scintigraphy than with  $^{67}\text{Ga}$ -citrate scintigraphy [5]. There are only a few reports about  $^{99m}\text{Tc(V)}$ -DMSA scintigraphy in dogs for the diagnosis of soft tissue cancer [2]. In the present study, the authors used  $^{99m}\text{Tc(V)}$ -DMSA imaging for assessment of the response of fibrosarcoma to external radiation therapy.

### Case report

A nine-year-old male black Schnauzer dog was referred for scintigraphic evaluation with a history of a large, growing, hard mass in the right shoulder region at the site of an operation performed four months ago. The general condition of the dog was very good with no history of pain, lameness or weight loss. At the

time of examination, the mass felt hard and homogeneous. The dog showed no signs of pain upon palpation and otherwise there were no abnormal findings.

### Scintigraphy

Scintigraphy was performed using Penta-DMSA® [ $^{99m}\text{Tc(V)}$ -DMSA] obtained from Medi-Radiopharma Ltd, Budapest, Hungary.  $^{99m}\text{Tc}$  pertechnetate was eluted from dry gel generator and labelling was done according to the prescribed protocol. 450 Mbq of the radiopharmaceutical was injected intravenously. Imaging studies were performed under general anaesthesia. Static images of the tumour mass were acquired at three hours post injection of  $^{99m}\text{Tc(V)}$ -DMSA. The study was performed at a different time period during the cancer management and the scans are shown in Figures 1 A, B and C. These scans were acquired in a dorsoventral position with 300 k counts using a large field of view single head digital SPECT (single photon emission computed tomography) gamma camera (Nucline X-ring, Mediso Ltd., Budapest, Hungary) with LEGP (low energy general purpose) collimator. Image processing of all images was done using Interview® software. The scintigraphy was performed three times:

pre-irradiation, post-irradiation just before surgery and two weeks later. Pre-surgery scintigraphy was utilized for careful resection of the tumour margins using a hand held gamma probe to assure that no tumour tissue was left inside. The region of interest was drawn on the primary tumour and on the shoulder region pre and post irradiation, to compare the change in size in terms of response to the radiation therapy. It was found that pre irradiation the ROI size, on the basis of radiopharmaceutical uptake, was 14702 mm<sup>2</sup> and post irradiation it was measured at 1888 mm<sup>2</sup>.

### External radiation therapy

Radiation therapy was performed using a <sup>60</sup>Co-irradiator (Gammatron, Siemens, Germany), three times a week for two weeks with 12 Gy exposure. The total dose delivered was 72 Gy. The radiation therapy was given in dorsoventral position keeping the tumour mass exactly under the beam while the rest of the area was protected using lead shielding to prevent radiation exposure to the left lobe of the lung. The whole procedure was performed under anaesthesia.

### Discussion

The role of <sup>99m</sup>Tc(V)-DMSA is well known in the diagnosis of primary soft tissue malignancies. In the present case, scintigraphic procedure provided valuable information about the size, vascularity and nature of the tumour mass. In this study, the usefulness of scintigraphy is shown in the follow-up and treatment evaluation in cancer therapy in animals. There was a significant reduction in tumour mass on the basis of tumour uptake using region of interest (ROI) quantification. The dog was operated on after radiation therapy. The oncoscintigraphy was performed before operation and the residual tumour tissue was detected using a hand-held gamma probe and removed very efficiently. No apparent recurrence was present in the following six months. Besides <sup>99m</sup>Tc(V)-DMSA scintigraphy can also be used for mapping tumour margins and then replacing the diagnostic radionuclide with a therapeutic one for radionuclide therapy. For this purpose, Rhenium is a beta energy emitting radionuclide suitable for radioisotope therapy with the added advantage of having a similar chemistry to Technetium. Therefore <sup>99m</sup>Tc(V)-DMSA distribution quantitatively predicts <sup>188</sup>Re(V)-DMSA distribution, and hence can be easily used as a diagnostic agent followed by radionuclide therapy. In conclusion we would like to state that diagnostic scintigraphy using <sup>99m</sup>Tc(V)-DMSA gives information about tumour functionality non-invasively which is useful in understanding the treatment response and disease process. This information is of value for the management of soft tissue cancer in animals.

### Acknowledgements

The authors would like to thank Mrs. Csilla Dirner, Zsuzsa Suhajda, Ella Hrisztodulakis, Mr. Karoly Haller and Norbert Fesus for technical assistance. This study was supported by BOYSCAST Grant No. HR/BY/L-15/2000 and OTKA Grant No. T-034465.

### Footnotes

This work was carried out at the Department of Applied Radioisotopes, National Research Institute of Radiobiology and Radiohygiene, Budapest, Hungary.

### References

1. Ambrus E, Rajter M, Ormandi K et al. Value of <sup>99m</sup>Tc-MIBI and <sup>99m</sup>Tc(V)-DMSA scintigraphy in evaluation of breast mass lesions. *Anticancer Res* 1997; 17: 1599–1605.
2. Balogh L, Andocs G, Perg E et al. Oncological scintigraphy in dogs with <sup>99m</sup>Technetium MIBI and DMSA(V)- Two case reports. *Vet Quart* 2001; 23: 52–56.
3. Blower PJ, Kettle AG, O'Doherty MJ, Coakley AJ, Knapp FF Jr. <sup>99m</sup>Tc(V)-DMSA quantitatively predicts <sup>188</sup>Re(v)-DMSA distribution in patients with prostate cancer metastatic to bone. *Eur J Nucl Med* 2000; 27: 1405–1409.
4. Hirano T, Otake H, Shibasaki T, Tamura M, Endo K. Differentiating histologic malignancy of primary brain tumours: pentavalent technetium-<sup>99m</sup>Tc-DMSA. *J Nucl Med* 1997; 38: 20–26.
5. Kobayashi H, Sakahara H, Hosono M et al. Soft-tissue tumours: diagnosis with Tc-<sup>99m</sup>(V) diercapsuccinic acid scintigraphy. *Radiology* 1994; 190: 277–280.
6. Kiratli PO, Kiratli H, Ercan MT. Visualization of orbital retinoblastoma with technetium-<sup>99m</sup>(v) dimercaptosuccinic acid. *Ann Nucl Med* 1998; 12: 157–159.
7. Limouris GS, Giannakopoulos V, Stavrika A, Toubanakis N, Vlahos L. Comparison of In-111 pentetretotide, Tc-<sup>99m</sup>(V)-DMSA & I-123 mIBG Scintimaging in neural crest tumours. *Anticancer Res* 1997; 17: 1599–1605.
8. Ohta H, Komibuchi T, Tomihara M, Watanabe H, Fujikawa S, Shintaku M. <sup>99m</sup>Tc(V)-DMSA and <sup>67</sup>Ga-citrate images in a patient with recurrent extraabdominal fibromatosis. *Ann Nuc Med* 1998; 12: 221–223.
9. Papantoniou V, Sotiropoulou M, Stipsaneli E et al. Scintimammographic findings of in situ ductal breast carcinoma in a double phase study with Tc-<sup>99m</sup>(V)DMSA. *Clin Nucl Med* 2000; 25: 434–439.
10. Papantoniou V, Christoulidou J, Papadaki E et al. <sup>99m</sup>Tc(V)-DMSA scintimammography in the assessment of breast lesions: comparative study with <sup>99m</sup>Tc(V)-MIBA. *Eur J Nucl Med* 2001; 28: 923–928.
11. Wang SJ, Lin WY, Wey SP, Shen LH, Ting G. Pentavalent Tc-<sup>99m</sup> dimercaptosuccinic acid imaging of hepatocellular carcinoma. *Neoplasma* 1999; 46: 264–268.