

# The role of gated myocardial perfusion scintigraphy (GMPS) in myocarditis: a case report and review of the literature

Hamid Javadi<sup>1</sup>, Sara Jallalat<sup>1</sup>, Gholamreza Pourbehi<sup>2</sup>,  
Shahriar Semnani<sup>1</sup>, Mehdi Mogharrabi<sup>1</sup>, Iraj Nabipour<sup>2</sup>,  
Mohammadreza Ravanbod<sup>2</sup>, Abdullatif Amini<sup>2</sup>, Majid Assadi<sup>3</sup>

<sup>1</sup>Golestan Research Centre of Gastroenterology and Hepatology (GRCGH),  
Golestan University of Medical Sciences (GUOMS), Gorgan, Iran

<sup>2</sup>The Persian Gulf Nuclear Medicine Research Centre, Bushehr University  
of Medical Sciences, Bushehr, Iran

<sup>3</sup>The Persian Gulf Marine Medicine Biotechnology Research Center,  
Bushehr University of Medical Sciences, Bushehr, Iran

[Received 3 VI 2011; Accepted 16 IX 2011]

## Abstract

Acute myocarditis is one of the most challenging diagnoses and treatments in cardiology. The acute viral myocarditis diagnosis is usually based on high suspicion, history taking, and physical examination. Likewise, the use of chest radiography, electrocardiography (ECG), and echocardiography is helpful in making a final diagnosis, but all are non-specific. In addition, in imaging query, magnetic resonance imaging (MRI) depicts some degree of cardiac inflammation in the course of myocarditis. Myocardial perfusion imaging (MPI) has also been shown to be useful in diagnosis, and this noninvasive technique diminishes the need for myocardial biopsy. The current study presents the diagnostic and prognostic role of MPI in a 25-year-old patient

with suspected myocarditis. The patient underwent gated-technetium-99m-labelled, methoxyisobutyl isonitrile, single photon emission computed tomography (Gated <sup>99m</sup>Tc-MIBI SPECT) that showed nonheterogeneous absorption with remarkable decreased radiotracer uptake in the myocardium in both stress and rest phases. In addition, the gated mode demonstrated decreased wall motion and thickening of the myocardium with a sum motion score (SMS) of 28, a sum thickening score (STS) of 15, and a measured LVEF of 34%. The study concludes that <sup>99m</sup>Tc-MIBI SPECT imaging is a useful modality in the preparation of supplementary diagnostic and prognostic information in viral myocarditis.

**Key words:** myocarditis, gated myocardial perfusion scintigraphy (GMPS), echocardiography, electrocardiography (ECG)

Nuclear Med Rev 2011; 14, 2: 112–115

## Introduction

Myocarditis occurs at any age from different causes, mostly viral in origin [1]. Some believe that myocarditis is an autoimmune phenomenon excited by direct viral infection [2]. Most cases of viral myocarditis are very mild and therefore tend to be hard to detect clinically [3]. In contrast, some cases are severe and lead to considerable heart failure or even sudden death resulting from electrical instability or poor contraction of the heart [3]. Acute myocarditis is one of the most challenging diagnoses and treatments in cardiology. The acute viral myocarditis diagnosis is usually based on high suspicion, history, and physical examination. Likewise, the use of chest radiography, electrocardiography (ECG), and echocardiography is helpful in making a final diagnosis, but all are non-specific [4]. At present, a right ventricular, endomyocardial biopsy is accepted as the gold standard, but its sensitivity is questionable because of its focal nature. Recent laboratory methods are based on the recognition of overlaps in virus-mediated injury, inflammation, and the autoimmune process. Continuing in imaging query, magnetic resonance imaging (MRI) depicts some degree of cardiac inflammation in

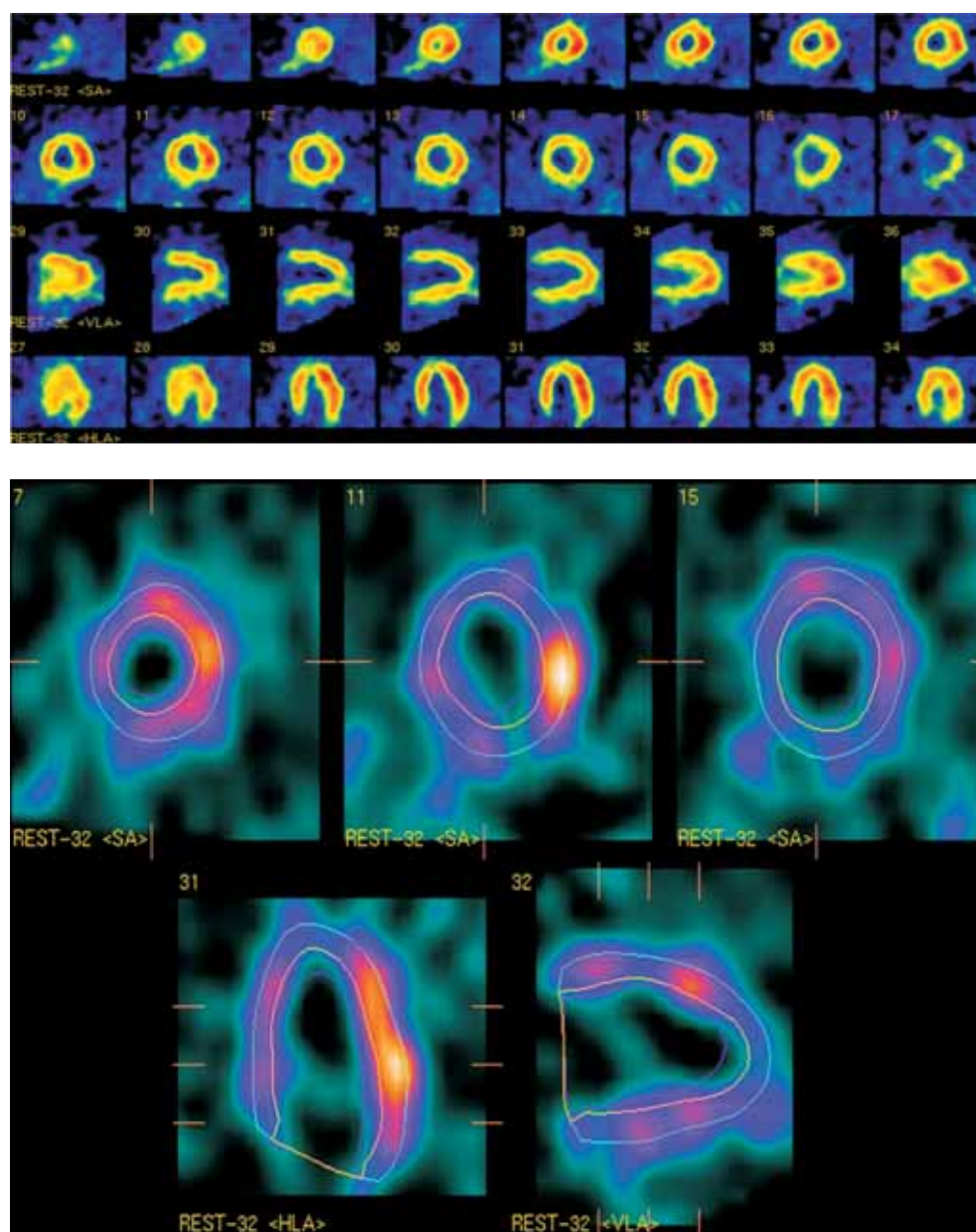
Correspondence to: Majid Assadi, M.D.  
The Persian Gulf Nuclear Medicine Research Centre, Bushehr  
University of Medical Sciences  
Bushehr 3631, Iran  
Tel: 0098-771-2580169, fax: 0098-771-2541828  
e-mail: assadipoya@yahoo.com, asadi@bpums.ac.ir

the course of myocarditis. Myocardial perfusion imaging (MPI) has also been shown to be useful in diagnosis, and this noninvasive technique diminishes the need for myocardial biopsy [2, 4]. The study presents the diagnostic and prognostic roles of MPI in a patient suspected for myocarditis.

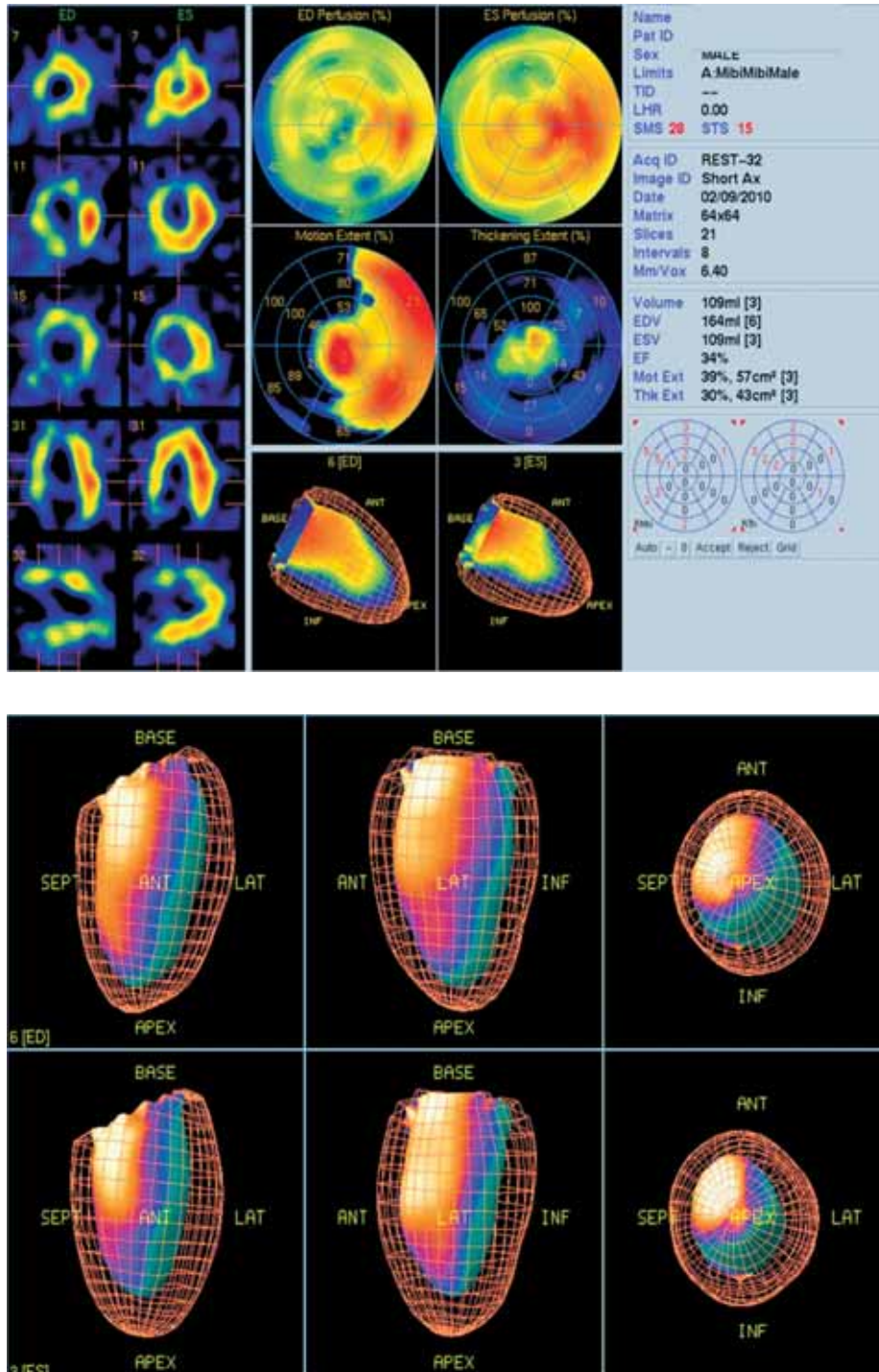
### Case report

A 25-year-old Caucasian man returned home from mountain climbing showing signs of a viral infection. His symptoms became worse and he was referred to hospital with severe viral infection symptoms. He was ill and suffered from vigorous chest pain on admission; further and insidiously, he became confused and a decreased level of consciousness was obvious.

In his work-up, echocardiography showed a left ventricular ejection fraction (LVEF) of 20% with severe decrease in heart wall motion and thickening. His ECG showed a trigeminal rhythm. With conservative therapy and good care, the patient got better and was discharged. His probable diagnosis was viral myocarditis resulting from a coxsackie-originated infection. In subsequent echocardiography exams after two and six months, LVEFs reported 29% and 32%, respectively. The patient was referred to the nuclear medicine centre and underwent gated-technetium-99m-labelled, methoxyisobutyl isonitrile, single photon emission computed tomography (Gated  $^{99m}\text{Tc}$ -MIBI SPECT). It showed nonheterogeneous absorption with remarkably decreased radiotracer uptake in the myocardium in both stress and rest phases (Figure 1). In addition, the gated mode demonstrated decreased wall motion and thickening of the



**Figure 1.** The gated-technetium-99m-labelled, methoxyisobutyl isonitrile, single photon emission computed tomography (Gated  $^{99m}\text{Tc}$ -MIBI SPECT) showed nonheterogeneous absorption with remarkable decreased radiotracer uptake in the myocardium in the vertical, horizontal, and short axes of the left ventricle views.



**Figure 2.** The gated-technetium-99m-labelled, methoxyisobutyl isonitrile, single photon emission computed tomography (Gated <sup>99m</sup>Tc-MIBI SPECT) demonstrated decreased wall motion and thickening of the myocardium with a sum motion score (SMS) of 28, a sum thickening score (STS) of 15, and an estimated left ventricle ejection fraction (LVEF) of 34%.

myocardium with a sum motion score (SMS) of 28, a sum thickening score (STS) of 15, and a measured LVEF of 34 % (Figure 2).

### Discussion

Myocarditis is an inflammatory process of the myocardium accompanied by cellular necrosis resulting from both infec-

tious causes, usually viral agents, and non infectious causes. Many types of viral infections can cause myocarditis but the most common are Coxsackie B and adenovirus [1, 2].

Most patients show generalized pain and other signs and symptoms of viral illness; mild myocarditis may not show any abnormality. However, in severely affected patients such as the case presented, myocarditis may lead to life-threatening congestive



heart failure and arrhythmias [3]. The initial stages of myocarditis are due to direct cytopathic effects on the atrial and ventricular myocardium; delayed stages of advanced decompensation may occur after myocyte destruction.

Viral myocarditis is a serious problem where rapid diagnosis is essential for the clinician to assess the prognosis and consider accurate treatment, but there is no single test that is solely able to detect, confirm, or rule out this disorder. Often the diagnosis of myocarditis is not straightforward because it is dependent on the severity of the heart involvement and on the host's responsiveness to pathogenic agents. However, its diagnosis can be based on some clinical signs and symptoms and on some laboratory and radiographic findings. History taking, physical examination, and imaging modalities are necessary to rule out non-inflammatory processes that may mimic viral myocarditis (e.g. congenital heart disease and genetic myopathies). The evaluation studies include electrocardiogram (ECG), chest X-ray, blood tests, imaging modalities, and endomyocardial biopsy (EMB) [3]. Specific markers for acute myocarditis in routine blood studies are lacking. Although cardiac enzymes, including creatine kinase and troponins, are usually increased, the increases are non-specific. ECG findings in myocarditis patients are extremely variable [5].

The cardiac silhouette showing on the chest radiograph is often enlarged, but it may also have a normal size and configuration [4]. Echocardiographic findings may be extremely different, from marked LV motion and thickening abnormalities to a normal situation [3, 6, 7]. Cardiovascular magnetic resonance (CMR) imaging has been revealed to be a helpful diagnostic modality in this query, but even so, because of a lack of sensitivity (8%) its role has decreased.

In imaging query, anatomical imaging modalities are often not suitable for the early recognition of infection because such procedures are focused solely on morphological alterations [8], while nuclear methods can find an inflammatory process simply because they are based on functional issues [9].

Consequently, two radiopharmaceuticals, including antimyosin antibody and <sup>67</sup>Gallium, have received attention as a screening technique with a high sensitivity (91–100%) and a negative predictive value (93–100%) in the identification of myocardial necrosis [10]. However, due to their limited accessibility, radiation exposure, and the need for some delayed views, their application has been limited.

In recent years, equipment for myocardial scintigraphy with gating methods, which are able to assess simultaneous perfusion and function, has been used in the diagnosis of myocarditis [7]. <sup>99m</sup>Tc-MIBI, a favourable radiotracer, was previously used for the evaluation of myocardial injury in patients with myocarditis [11], and Sun et al. [12] showed promising results with gated-myocardial perfusion scintigraphy (GMPS) in viral myocarditis reports. They showed a good correlation between the degree of diminished perfusion as a marker of myocarditis with ST-T changes and myocardial enzyme levels. Their study showed that GMPS items (e.g. sum motion score (SMS), sum thickening score (STS), sum stress score (SSS), sum rest score (SRS), ejection fraction (EF),

and lung-to-heart (L/H) ratio) had prognostic value in the survival of patients with myocarditis [12]. The same findings were reported by Lee et al. [13] and De Winter et al. [14], who showed that GMPS provides further data in addition to clinical and perfusion information for the prediction of cardiac death. GMPS parameters had good correlation with echocardiographic items [15].

## Conclusions

In the case presented in this study, GMPS using <sup>99m</sup>Tc-MIBI radiotracer was a valuable modality, and the study concluded that <sup>99m</sup>Tc-MIBI SPECT imaging is a useful modality in the preparation of supplementary diagnostic and prognostic information in viral myocarditis.

## References

1. Frishman WH, Zeidner J, Naseer N. Diagnosis and management of viral myocarditis. *Curr Treat Options Cardiovasc Med* 2007; 9: 450–464.
2. Soongswang J, Durongpisitkul K, Ratanarapee S et al. Cardiac troponin T: its role in the diagnosis of clinically suspected acute myocarditis and chronic dilated cardiomyopathy in children. *Pediatr Cardiol* 2002; 23: 531–535.
3. Dennert R, Crijns HJ, Heymans S. Acute viral myocarditis. *Eur Heart J* 2008; 29: 2073–2082.
4. Checchia PA, TJ K. Acute viral myocarditis: diagnosis. *Pediatr Crit Care Med* 2006; 7 (suppl): S8–S11.
5. Dec GW, Jr, Waldman H, Southern J, Fallon JT, Hutter AM, Jr, Palacios I. Viral myocarditis mimicking acute myocardial infarction. *J Am Coll Cardiol* 1992; 20: 85–89.
6. Take M, Sekiguchi M, Hiroe M, Hirose K. Long-term follow-up of electrocardiographic findings in patients with acute myocarditis proven by endomyocardial biopsy. *Jpn Circ J* 1982; 46: 1227–1234.
7. Abdel-Aty H, Boye P, Zagrosek A et al. Diagnostic performance of cardiovascular magnetic resonance in patients with suspected acute myocarditis: comparison of different approaches. *J Am Coll Cardiol* 2005; 45: 1815–1822.
8. Becker W, Meller J. The role of nuclear medicine in infection and inflammation. *Lancet Infect Dis* 2001; 1: 326–333.
9. Rennen HJ, Boerman OC, Oyen WJ, Corstens FH. Imaging infection/inflammation in the new millennium. *Eur J Nucl Med* 2001; 28: 241–252.
10. Kiratli PO, Tuncel M, Ozkutlu S, Caglar M. Gated myocardial perfusion scintigraphy in children with myocarditis: can it be considered as an indicator of clinical outcome? *Nucl Med Commun* 2008; 29: 907–914.
11. Lagana B, Schillaci O, Tubani L et al. Lupus carditis: evaluation with technetium-99m MIBI myocardial SPECT and heart rate variability. *Angiology* 1999; 50: 143–148.
12. Sun Y, Ma P, Bax JJ et al. <sup>99m</sup>Tc-MIBI myocardial perfusion imaging in myocarditis. *Nucl Med Commun* 2003; 24: 779–783.
13. Lee KJ, McCrindle BW, Bohn DJ et al. Clinical outcomes of acute myocarditis in childhood. *Heart* 1999; 82: 226–233.
14. De Winter O, Velghe A, Van de Veire N et al. Incremental prognostic value of combined perfusion and function assessment during myocardial gated SPECT in patients aged 75 years or older. *J Nucl Cardiol* 2005; 12: 662–670.
15. Martin AB, Webber S, Fricker FJ et al. Acute myocarditis. Rapid diagnosis by PCR in children. *Circulation* 1994; 90: 330–339.