

Uterine leiomyosarcoma metastatic to the pancreas

Anna Rygula¹, Michał Kowalski¹, Marcin Ziętek^{2,3} 

¹Student Research Group of Oncology, Department of Oncology, Wrocław Medical University, Wrocław, Poland

²Department of Oncology, Wrocław Medical University, Wrocław, Poland

³2nd Department of Surgical Oncology, Lower Silesian Oncology, Pulmonology and Haematology Centre, Wrocław, Poland

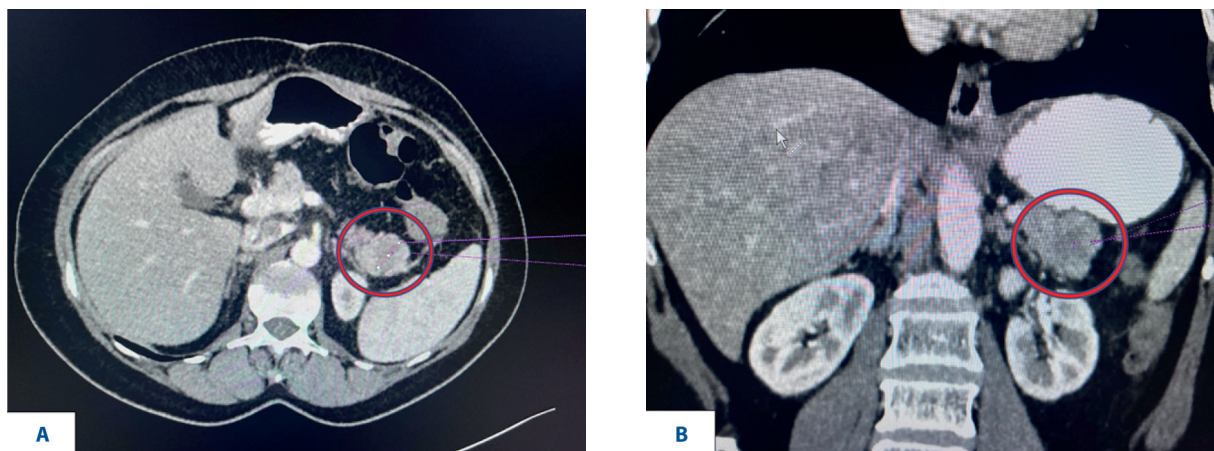


Figure 1. Computed tomography images of the metastatic pancreatic tumor before excision. **A** – image of a 5 cm tumor in the tail of the pancreas – transverse view; **B** – image of a 5 cm tumor in the tail of the pancreas – coronal view

In July 2021, a 57-year-old woman with a medical history of uterine leiomyosarcoma, diagnosed and excised in 2016, was referred to the Lower Silesian Oncology Center. PET-CT results revealed a nodular lesion of 6.7x5.8x7 cm in the pelvis and a focal lesion in the tail of the pancreas. In August 2021, the patient underwent a laparotomy to remove a retroperitoneal tumor and the vaginal stump. The pancreatic tail tumor was not excised due to the repeated laparotomy and the local advancement of the pelvic tumor. The histopathological examination revealed leiomyosarcoma G2 and infiltration of leiomyosarcoma in the sigmoid colon. Subsequently, a median relaparotomy was performed to excise the tail tumor, and an examination of the postoperative material revealed metastatic leiomyosarcoma (fig. 1). The patient was offered adjuvant

doxorubicin chemotherapy but refused treatment. Radical surgery is recommended to treat retroperitoneal sarcomas, and complete cross resection is associated with improved survival [1, 2]. Adjuvant therapy typically involves doxorubicin or ifosfamide chemotherapy [2]. Incomplete mass removal should not be performed if the tumor is unresectable, as it worsens the patient's prognosis.

References

1. Dominguez DA, Sampath S, Agulnik M, et al. Surgical Management of Retroperitoneal Sarcoma. *Curr Oncol.* 2023; 30(5): 4618–4631, doi: 10.3390/currenol30050349, indexed in Pubmed: 37232807.
2. Mehren Mv, Kane J, Agulnik M, et al. Soft Tissue Sarcoma, Version 2.2022, NCCN Clinical Practice Guidelines in Oncology. *Journal of the National Comprehensive Cancer Network.* 2022; 20(7): 815–833, doi: 10.6004/jnccn.2022.0035.

How to cite:

Rygula A, Kowalski M, Ziętek M. *Uterine leiomyosarcoma metastatic to the pancreas.* *NOWOTWORY J Oncol* 2023; 73: 255.

This article is available in open access under Creative Common Attribution-Non-Commercial-No Derivatives 4.0 International (CC BY-NC-ND 4.0) license, allowing to download articles and share them with others as long as they credit the authors and the publisher, but without permission to change them in any way or use them commercially.