

Pushing the age limit and reducing the number of contraindications of liver resections in cancer-bearing patients — a case report

Konrad Kobryń, Łukasz Masiór, Michał Grąt, Bogusław Najnigier,
Paweł Nyckowski, Waldemar Patkowski, Marek Krawczyk

Liver resections are performed in increasing numbers due to oncological indications. Thus, the indications for surgical treatment of liver tumors are constantly expanding. Advanced age and other comorbidities often exclude this group of patients from treatment by liver resection.

Patient C.S. (80 y.a., height 166 cm, weight 97 kg, ASA = 4) with risk factors was admitted for resection of metastatic lesions (adenocarcinoma) of the cecum to the liver. The patient was diagnosed with hypertension, atherosclerosis, stable coronary heart disease, type 2 diabetes, chronic renal failure (eGFR = 37), obesity, degenerative spinal lesions, sigmoid colon diverticulitis, dystonic tremor of the head. Previously operated upon and had amputation of the uterus with appendages (2005), cholecystectomy, right hemicolectomy (2012) complicated by respiratory failure with the need for ventilation seven days post-surgery. Prior to surgery, the patient had imaging tests such as ultrasound, CT and MRI scans of the abdomen, which confirmed a 55mm metastatic tumor in the seventh segment of the liver. The results were analyzed during a radiological and surgical consultation in order to prepare the safest available surgical access and the scope of the planned resection. A cardiac echocardiography was performed and the patient had a cardio-, neuro- and anesthetic consultation. The patient was fully informed about the high risk of complications and possible operational failure.

During surgery a right hemihepatectomy was performed. The resected lobe weighed 712 g. Blood loss was < 500 ml, 2 units RBC and 2 units FFP were transfused. The surgery and the postoperative period proceeded without serious complications. The only problem was a short-lived biliary fistula, which healed spontaneously.

Age and comorbid conditions are often a contraindication for surgery, but with proper medical support, the opportunity to interact with other professionals and thorough preparation of the patient and the team of surgeons, the risk of failure can be significantly minimized. A modern, personalized, multidisciplinary approach towards each patient can expand indications and reduce contraindications for hepatic resection.

Przesuwanie granicy wieku i zmniejszanie liczby przeciwwskazań do resekcji wątroby u obciążonych onkologicznych chorych — opis przypadku

Resekcje wątroby ze wskazań onkologicznych są coraz częściej wykonywaną operacją. Wskazania do leczenia operacyjnego nowotworów wątroby stale są rozszerzane, wciąż jednak zaawansowany wiek pacjenta oraz inne towarzyszące choroby często wykluczają tę grupę chorych z leczenia resekcją wątroby.

Chora C.S. (lat 80, wzrost 166 cm, masa ciała 97 kg, ASA = 4) obciążona internistycznie została zakwalifikowana do resekcji zmiany przerzutowej gruczolakoraka kątnicy do wątroby. W wywiadzie nadciśnienie tętnicze, uogólniona miażdżyca, stabilna choroba niedokrwienna serca, cukrzyca typu 2, przewlekła niewydolność nerek (eGFR = 37), otyłość, stany zwyrodnieniowe kręgosłupa, uchyłkowość esicy, drżenie dystoniczne głowy. Stan po amputacji macicy z przydatkami (2005), po cholecystektomii, po hemikolektomii prawostronnej (2012) powikłanej niewydolnością oddechową z koniecznością wentylacji 7 dni od operacji. Wykonano USG, TK i MR jamy brzusznej, które potwierdza-

ły guz przerzutowy o średnicy 55 mm w VII segmencie wątroby. Wyniki tych badań były dokładnie omówione na konsylium radiologiczno-chirurgicznym w celu zaplanowania najbezpieczniejszego dostępu i zakresu planowanej resekcji. Wykonano echokardiografię serca i konsultowano chorą kardiologicznie, neurologicznie oraz anesteziologicznie. Pacjentka była w pełni poinformowana o wysokim ryzyku powikłań i ewentualnego niepowodzenia operacji. Podczas operacji wykonano hemihepatektomię prawostronną. Resekowana część wątroby ważyła 712 g. Utrata krwi w czasie operacji < 500 ml, przetoczono 2 j. KKCz oraz 2 j. FFP. Chora zniosła zabieg operacyjny i okres pooperacyjny bez powikłań. Jedynym problemem była krótkotrwała przetoka żółciowa, która zagoiła się samoistnie. Wiek i choroby towarzyszące często stanowią przeciwwskazanie do leczenia operacyjnego, jednak przy odpowiednim zapleczu medycznym, możliwości współpracy z innymi specjalistami oraz dokładnym przygotowaniem chorego i zespołu przeprowadzającego operację ryzyko niepowodzenia znacznie spada. Zatem nowoczesne, indywidualne, wielospecjalistyczne podejście do chorego pozwala rozszerzać wskazania i zmniejszać przeciwwskazania do resekcji wątroby.

NOWOTWORY Journal of Oncology 2015; 65, 6: 539–542

Key words: liver metastases, colorectal liver metastases, liver resection

Słowa kluczowe: przerzuty, guzy wtórne wątroby, resekcja wątroby

Background

Surgical resection of the liver is an established and widely performed treatment for oncological indications of primary and secondary hepatic cancer [1]. Thus, with the appropriate anaesthesiological management and advances in hepatopancreatobiliary (HPB) surgery the indications for surgical treatment of liver tumors are constantly expanding, reducing morbidity and mortality in major hepatectomy [2–5]. Currently survival rate in patients with colorectal liver metastases ranges from 40–70% [6]. Advanced age and the presence of many comorbidities often exclude this group of patients from surgical treatment. Currently, major liver resections in the elderly, is a debatable topic, with few studies conducted so far [5].

Case report

Here we present a case of an 80 year old female (C.S.) who underwent a right hemicolectomy in September 2012, due to a tumor of the caecum (histologically identified as adenocarcinoma) and who was referred to our Department in May 2013, with a single, confirmed by fine needle aspirational biopsy (FNAB) guided by ultrasound, metastasis to the liver. Previously she was disqualified from surgery by two other regional centers in Poland and concluded as having a tumor of unfortunate location, difficult for a surgical approach and radio-frequency ablation (RFA). The external diagnostic imaging results that came with the patient — Computer Tomography (CT) and Magnetic Resonance Imaging (MRI) both described a 45 mm lesion in the VII segment of the liver infiltrating its capsule and perhaps the right kidney. Apart from the typical blood tests we ran at admittance, we also examined specific tumor markers of the following: AFP 2,59 ng/ml, CEA — 18,58 ng/ml, Ca19-9 — 495,5 j/ml. The last two markers were greatly

elevated which is typical for colorectal liver metastasis (CRLM). In the abdominal ultrasound examination the lesion was described to be in segment VI on the border with segment VII, breaching the Gleason's Capsule and in the direct neighborhood of the right hepatic vein (RHV) and superior pole of the right kidney. Furthermore the tumor was located 10 mm from the confluence of the right portal vein and its segmental branches.

The patient had been previously diagnosed with the following comorbidities: hypertension, atherosclerosis, stable coronary heart disease, type 2 diabetes, chronic renal failure (eGFR = 37), obesity, degenerative spinal lesions, sigmoid colon diverticulitis, dystonic tremor of the head. In order to qualify the patient for surgery numerous consultations were necessary. Therefore an ECG and cardiac ultrasound were performed and a cardiologist was consulted. A neurological examination was performed by a consultant neurosurgeon and neurologist, a thyroid ultrasound and FT3, FT4 and TSH were reported on by an endocrinologist and thyroid hormone levels were normalized.

Due to the amputation of the uterus with both sided ovariectomy in 2005 she was examined by a gynaecologist. Further consultations by a nephrologist, gastroenterologist and anesthesiologist were carried out making the patient available for surgery. This type of preparation was crucial due to the patient's age, comorbidities and the last surgical procedure (right hemicolectomy — 2012) complicated by respiratory failure with the need of ventilation during the first seven post-operative days. All the clinical and diagnostic imaging results were discussed by a team of radiologists and surgeons in order to plan and predict any issues that could occur during surgery. The patient was informed about the high risk of complications and was admitted to surgery after signing a written consent.

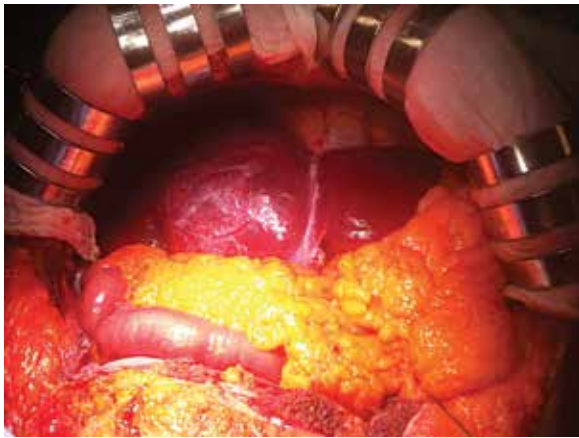


Figure 1. Colorectal liver metastases *in situ*

A right hemihepatectomy was performed by a team of three surgeons with minimal intraoperative blood loss, without periods of hypotension, with a diuresis of 50 ml/h and CVP of 9 mm H₂O. The operating time was just under 5 hours and 2 units of blood and 2 units of fresh frozen plasma were transfused (baseline Hgb level = 11,02 g/dl). The liver presented approximately 15% steatosis in macroscopic evaluation confirmed in a latter histopathology examination (figure 1). The resected lobe weighed 712 g (figure 2). The patient was extubated in the OR with good vitals and top respiration (SaO₂ — 96%).

On the 4th post-operative day (POD) a biliary fistula appeared. Within 10 days the amount of bile gradually lessened, with no fever and no abdominal pain. However, in the 2nd week post-surgery due to a scarce amount of bile still being drained from the abdomen, an ERCP was carried out. A 12 cm (10Fr) stent was placed in the left hepatic duct. The patient was discharged from hospital two weeks later with no clinical symptoms of bile leakage or other complications.

Three months later the stent was removed during a secondary ERCP. The patient was discharged the same day in good general condition. By that time the laceration was fully healed.

Discussion

The intention of this paper is to emphasize the importance of appropriate general management of elderly patients prior to surgery as a safe and risk-minimizing protocol. Certain authors conclude that the appropriate selection of patients for liver resection gives the best results [7]. With this we can agree, as long as we don't discard elderly patients, since there still remain controversies concerning whether advanced age increases peri-operational risk and effect morbidity [8]. With the improvement of medical treatment in all fields of medicine and longer overall survival, we are looking at a natural expansion of candidates awaiting liver resection. We predict that very soon the mean age of operated patients might reach the 3rd decade. Operating an 80 year old patient

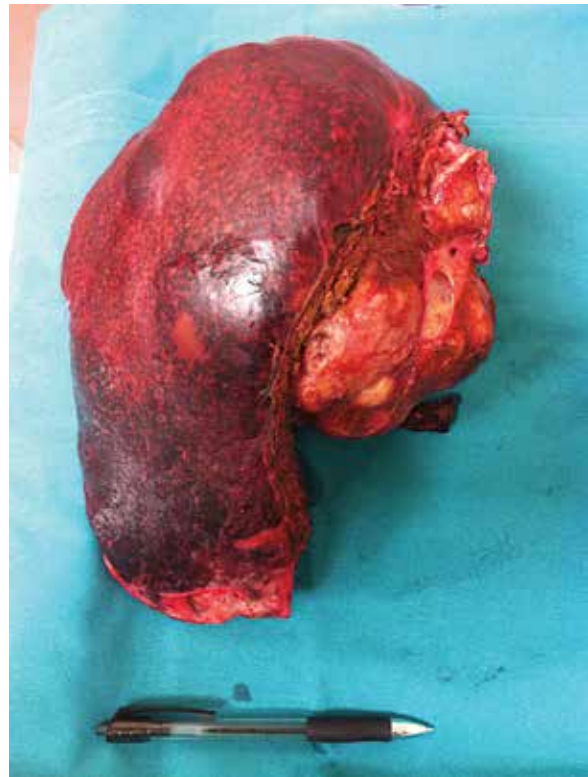

Figure 2. Removed right lobe of the liver along with tumor

with much comorbidity, such as the one reported in the paper, will be acceptable and more common amongst HPB centers. Moreover, it is reported that surgery being performed due to hepatocellular carcinoma (HCC) and colorectal liver metastasis (CRLM) is comparably safe in the elderly as it is in the younger group of patients [9–11]. Major liver resections are as challenging for general surgeons as they are for HPB surgeons, but this group of patients need as much assistance as any other. Only a multidisciplinary team of experts with the appropriate facilities can face the challenge. However this doesn't mean that general surgery units should routinely disqualify elderly patients from surgery. Stratification should be applied, which in the case of the above mentioned patient, referral to a HPB center is compulsory. In cases with less advanced tumors treatment could be carried out at the primary center. In addition, elective liver resections among the elderly are considered safe as long as the patient group is carefully selected [10, 11]. Despite the decision about qualifying an advanced age patient for surgery, it should always be an individual approach and every team preparing for this kind of surgery should go through the potential complications that may occur and already have a plan on how to treat them prior to surgery. Modern surgery is able to deal with the elderly [11], however this issue will be discussed and talked over many times in the future.

Conflict of interest: none declared

Lek. Konrad Kobryn

Katedra i Klinika Chirurgii Ogólnej,
Transplantacyjnej i Wątroby
Warszawski Uniwersytet Medyczny
ul. Banacha 1a, 02-097 Warszawa
e-mail: konradkobryn@gmail.com

Paper received: 23 August 2015

Accepted: 29 September 2015

References

1. Fong Y, Brennan MF, Cohen AM et al. Liver resection in elderly. *Br J Surg* 1997; 84: 1386–1390.
2. Grat M, Grzegorzczak K, Lewandowski Z et al. Intraoperative injuries during liver resection: analysis of 1,005 procedures. *Hepatol Int* 2012; 6: 498–504.
3. Cho SW, Steel J, Tsung A et al. Safety of liver resection in the elderly. How important is age? *Ann Surg Oncol* 2011; 18: 1088–1095.
4. Aldrighetti L, Arru M, Caterini R et al. Impact of advanced age on the outcome of liver resection. *World J Surg* 2003; 27: 1149–1154.
5. Grąt M, Hołowko W, Lewandowski Z et al. Early post-operative prediction of morbidity and mortality after a major liver resection for colorectal metastases. *HPB* 2013; 15: 352–358.
6. Zeman M, Kryj M, Czarnecki M et al. Chirurgiczne leczenie przerzutów raka jelita grubego do wątroby — doświadczenia własne. *Nowotwory J Oncol* 2012; 62: 5–9.
7. Zacharias T, Jaeck D, Oussoultzoglou E et al. First and repeat resection of colorectal liver metastases in elderly patients. *Ann Surg* 2004; 240: 858–865.
8. Adam R, Frilling A, Elias D et al. Liver Met Survey Centres. Liver resection of colorectal metastases in elderly patients. *Br J Surg* 2010; 97: 366–376.
9. Huang J, Li BK, Chen GH et al. Long-term outcomes and prognostic factors of elderly patients with hepatocellular carcinoma undergoing hepatectomy. *J Gastrointest Surg* 2009; 13: 1627–1635.
10. Chiappa A, Zbar AP, Biella F et al. Validity of hepatic resection for cancer in the elderly. *Ann Ital Chir* 2002; 73: 397–401.
11. Hirokawa F, Hayashi M, Miyamoto Y et al. Surgical outcomes of clinical characteristics of elderly patients undergoing curative hepatectomy for hepatocellular carcinoma. *J Gastrointest Surg* 2013; 17: 1929–1937.
12. Belghiti J, Hiramatsu K, Benoist S et al. Seven hundred forty seven hepatectomies in the 1990; an update to evaluate the actual risk for liver resection. *J Am Coll Surg* 2000; 191: 38–46.

Sprostowanie

W publikacji pt. „Znaczenie receptora progesteronowego w luminalnych rakach piersi” *NOWOTWORY J Oncol* 2015; 65: 383–388 omyłkowo podano niewłaściwą kolejność autorów.

Właściwa kolejność to: Wojciech Kuncman, Marcin Braun, Radziszlaw Kordek

Redakcja