

Intravascular brachytherapy after percutaneous recanalization of occluded femoral artery: a case report

Piotr Walichiewicz¹, Brygida Białas², Jerzy Piecuch³, Marek Fijałkowski²,
Krzysztof Ślosarek¹, J. Arendt³

The paper presents the use of intravascular brachytherapy after percutaneous recanalization and angioplasty of the femoral artery in a 65-year old patient with hypertension, a history of heavy smoking, and early stage diabetes. The patient was admitted to hospital with rest ischaemia of the right crus and trophic skin changes in that region. After primary pharmacological treatment angiography was performed revealing the femoro-popliteal artery to be occluded in the distal part of the adductor canal. The patency of the artery was established. Subsequently the occluded part of the artery was completely dilated without residual stenosis. Control angiography revealed good contrast flow through the dilated artery and correct configuration of the arteries below the open and dilated part of the femoro-popliteal artery. These arteries were, however, anatomically narrow. On clinical examination the pulse was present on peripheral arteries, while cyanosis of the right foot and the pain had disappeared. To prevent restenosis after angioplasty intravascular brachytherapy was performed with Microselectron ¹⁹²Ir. A PARIS catheter was used as the applicator. It was introduced into the artery using the same access as angiography and angioplasty. The target for irradiation was the dilated part of the artery with bilateral 1.5cm margins – altogether 10 cm. One dose of 15 Gy was applied 2 mm from the inner surface of the arterial wall (2 mm from the applicator surface). There were no early side effects after the treatment.

Zastosowanie brachyterapii śródnaczyniowej po udrożnieniu odcinkowej niedrożności tętnicy udowej: opis przypadku

Przedstawiono i omówiono przypadek 65-letniego chorego, u którego zastosowano śródnaczyniową brachyterapię HDR po udrożnieniu tętnicy udowej. Chory, z nadciśnieniem, nałogowy palacz papierosów, ze świeżo rozpoznaną cukrzycą, został przyjęty do szpitala z objawami spoczynkowego niedokrwienia kończyny dolnej prawej oraz zmianami troficznymi skóry w obszarze niedokrwienia. Po wstępnym leczeniu farmakologicznym u chorego wykonano angiografię. Badanie to wykazało niedrożność tętnicy udowej w dystalnym odcinku kanału przywodzicieli. Tętnicę udrożniono i wykonano angioplastykę zwężonego odcinka tętnicy. Uzyskano pełne poszerzenie tętnicy. W kontrolnej angiografii stwierdzono dobry przepływ przez poszerzoną tętnicę oraz prawidłowy przebieg naczyń tętniczych poniżej udrożnionej i poszerzonej zmiany. Tętnice te jednak były w całości wąskie. Klinikalnie stwierdzono powrót tętna na tętnicach obwodowych, ustąpienie sinicy oraz dolegliwości. W celu utrwalenia efektu angioplastyki balonowej zdecydowano się wykonać u chorego brachyterapię śródnaczyniową z użyciem Microselectronu ¹⁹²Ir. Jako aplikator zastosowano cewnik typu PARIS. Wprowadzono go do naczynia z tego samego dostępu, z którego wykonano angiografię i angioplastykę. Podano jednorazową dawkę o wysokości mocy 15 Gy na odległość 2 mm poza średnicę wewnętrzną tętnicy (2 mm od powierzchni aplikatora). Napromieniono odcinek poszerzanej tętnicy z obustronnym marginesem 1,5 cm, łącznie na długości 10 cm. We wczesnym okresie pozabiegowym nie obserwowano żadnych powikłań.

key words: intravascular brachytherapy, femoral artery, percutaneous angioplasty

słowa kluczowe: brachyterapia śródnaczyniowa, tętnica udowa, przezskórna angioplastyka

¹ Department of Radiotherapy

² Department of Brachytherapy

The Maria Skłodowska-Curie Memorial Cancer Center and Institute of Oncology, Gliwice, Poland

³ Department of General Surgery, Hospital No 1, Bytom

Introduction

Percutaneous balloon angioplasty is a well-known standard for non-surgical treatment of arterial stenosis. However the relatively low popularity of this method is, probably, the results of a high rate of restenosis, which reaches some 40% [1, 2, 3]. Three factors are responsible for such a high restenosis rate [4]. Firstly, the elastic recoil is obviously a reaction of the elastic arterial wall to mechanical pressure. Effects of this phenomenon might be observed immediately after dilation. The second factor is the retraction of scarred tissue after arterial wall trauma caused by the pressure of the balloon [5]. The third factor responsible for restenosis is hypertrophy of the intima within the dilation site. It has been shown in several studies that this process is stimulated by the reaction of the adventitia to the pressure of the balloon [6, 7]. Every excessive dilation of the artery lumen brings on three reactions – (i) platelet and fibrine deposition, (ii) vessel wall hemorrhage and (iii) inflammation. Myofibroblasts activated within the adventitia migrate to the intima, where they present a number of phenotype features typical for smooth muscle cells.

Schopol and Lierman in 1991 were the first to apply intravascular brachytherapy to prevent restenosis after angioplasty. The goal of intravascular brachytherapy is to minimize the reactions to balloon angioplasty and stent implantation, including the inflammatory process. In recently published data the frequency of restenosis after percutaneous transluminal angioplasty with intravascular brachytherapy reaches 13% during 12 months observation and 25% during 6 years of follow-up [8].

Case report

A 65-year old patient presented symptoms of acute ischemia of the right crus. There was severe pain of the limb and cyanosis of right foot. Some symptoms, such as intermittent claudication, had been observed three years earlier. At the onset of the disease the distance of claudication was some 400 meters, becoming progressively shorter and towards the end of December 1999 rest ischemia with cyanosis and trophic skin changes of the right crus was present. On admission objective examination revealed cyanosis of distal phalanges of digits I, II and III and cold skin of right foot. There was no pulse on the posterior tibial and dorsal arteries of the right foot. For the previous three years the patient had been treated for arterial hypertension. For many years he had been smoking up to 30 cigarettes per day. Laboratory examination on admission and during hospitalization revealed diabetes. During hospitalization heparin, pentoxifylline and xantinol were applied as continuous intra-venous infusions causing pain relief. On January 12th 2000 the patient was transported to the Institute of Oncology in Gliwice. There angiography was performed from the femoral approach. Using typical Seldinger technique an arterial sheath size 8 F (CORDIS) was introduced into the artery. As radiological contrast 75% UROGRAFIN

(Schering AG) was used. Angiography revealed an occlusion of femoral superficial artery within the distal part of the adductor canal [Fig. 1]. Through the arterial sheath the leader for angioplasty (CORDIS) was introduced and the artery lumen was restored. Subsequently an angioplasty balloon (CORDIS) 7 mm in diameter was in-

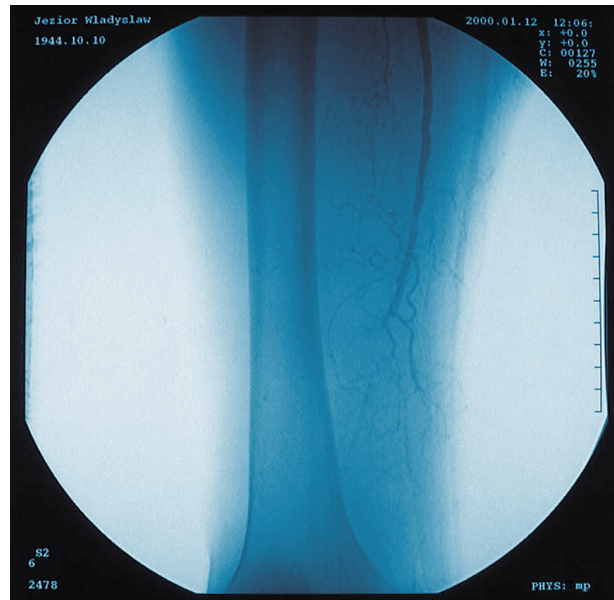


Fig. 1. Angiography of the femoro-popliteal artery before recanalization and angioplasty

roduced and filled in the place of the stenosis (pressure of 12 atm for 5 minutes). Thus the artery was completely dilated without residual stenosis. [Fig. 2] Control angiography showed good passage of contrast through the dilated artery and proper configuration of arteries below the open and dilated part of the femoral superficial arte-

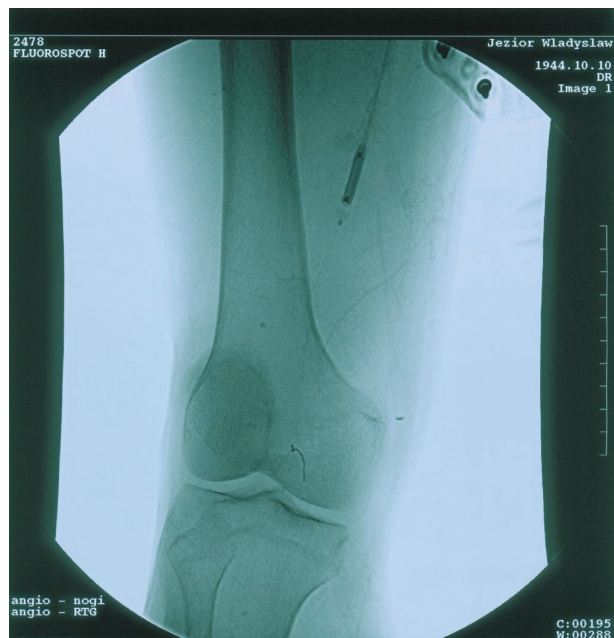

Fig. 2. Angioplasty of femoro-popliteal artery

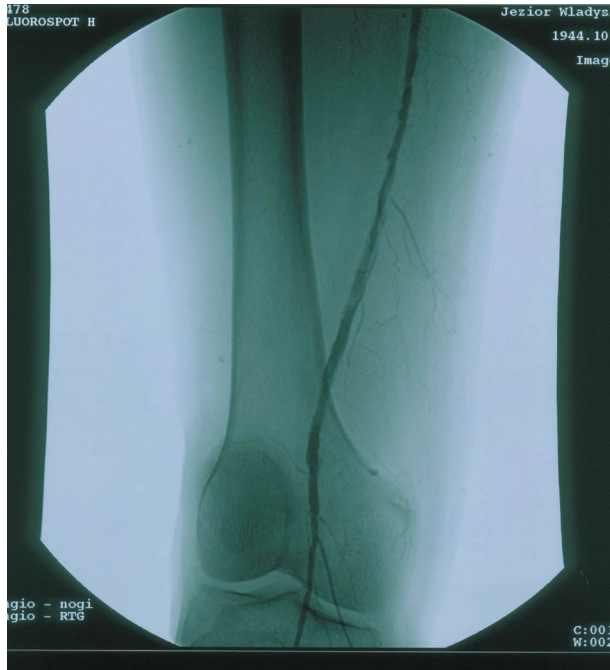


Fig. 3. Angiography of the femoro-popliteal artery after recanalization and angioplasty

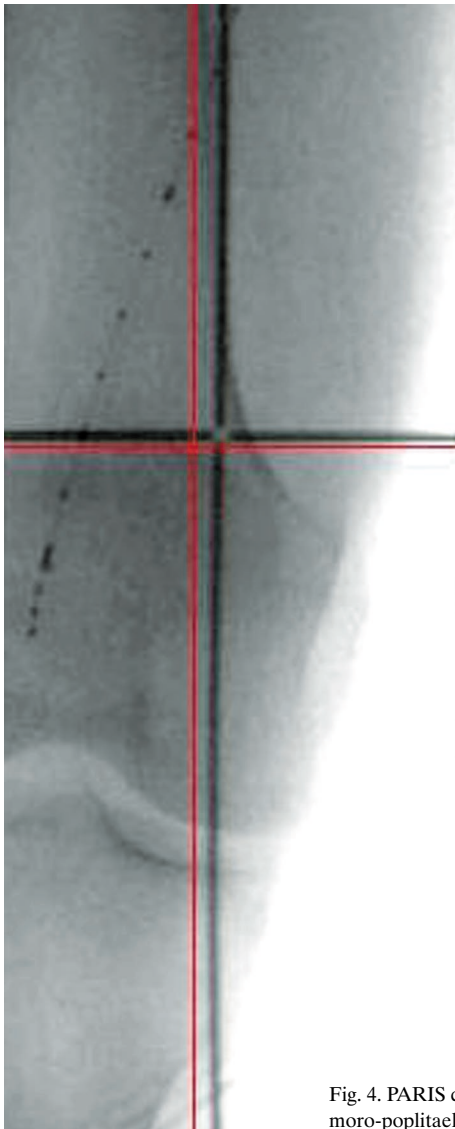

Fig. 4. PARIS catheter in the femoro-popliteal artery

ry. These arteries were, however, anatomically narrow. [Fig. 3] On clinical examination the pulse on peripheral arteries was present, cyanosis of the right foot and pain passed. To prevent the restenosis after angioplasty intravascular brachytherapy was performed with Microselectron ^{192}Ir (Nucletron). A PARIS catheter (Nucletron) with a centering balloon (7 mm) was used as applicator. It was introduced into the artery through the same

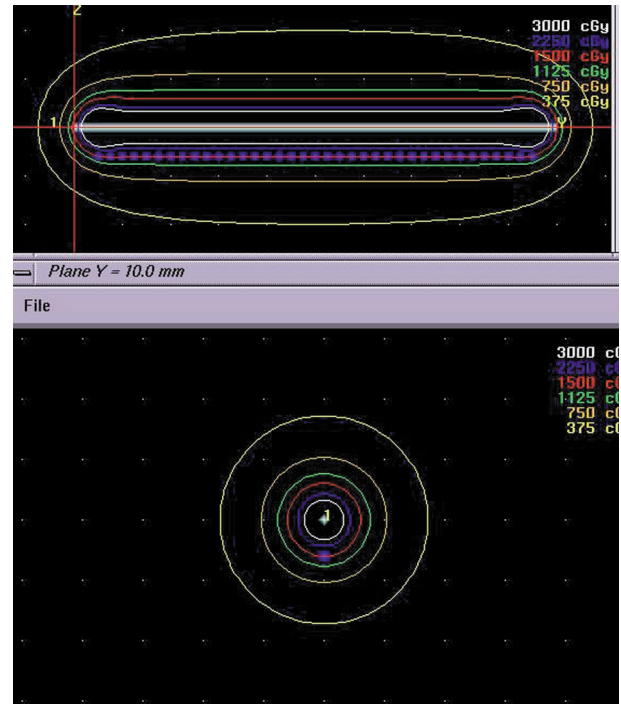


Fig. 5. Dose distribution in the irradiated volume

access as that for angiography and angioplasty. The tip of this catheter was placed below the dilated part of artery [Fig. 4] The target for irradiation was the dilated part of the artery with bilateral margins of 1.5 cm, altogether a distance of 10 cm. One dose of 15 Gy high was applied 2mm from the surface of the arterial wall (i.e. 2 mm from the applicator surface). Irradiation lasted 10 minutes and 44 seconds. [Fig. 5] After irradiation the patient returned to the Surgical Ward of the 1st Hospital in Bytom. There were no side effects nor any adverse effects following the interventions.

Discussion

In the stenosis or occlusion of peripheral arteries surgical treatment is generally applied. Balloon angioplasty as an alternative for surgery does not have the expected level of popularity because of a high restenosis rate. Intravascular brachytherapy is a valuable complement of percutaneous transluminal angioplasty of peripheral arteries. This method definitely decreases the number of restenoses. However it also significantly raises the costs of treatment. Nevertheless patients with peripheral ischemia with additional risk factors due to advanced stages of the disease

profit from this method and in their case it appears to be the elective form of treatment. The additional risk factors mentioned above might limit the efficacy of surgical treatment and increase the risk of complications of general anesthesia. Advanced ischemia in peripheral parts of limbs may cause trophic changes which, in turn, may complicate the healing process. In case of coexisting diabetes one may observe accelerated atherosclerosis and microangiopathy, as well as skin lesions. Increased blood glucose causes immunodeficiency which raises the risk of local bacterial infection. Atherosclerosis is usually a generalized process. Patients with changes in peripheral arteries, especially those advanced in age, very often suffer from ischemic heart disease or ischemic stroke. A history of infarct or stroke may be a relative counterindication for general anesthesia. Arterial hypertension is one of the reasons for the progression of atherosclerotic changes in arterial walls. Hypertension also increases the sensitivity of the arterial wall to raised serum lipid level. Atherosclerotic arteries decrease in flexibility and cannot be involved in arterial pressure regulation. Thus atherosclerosis may bring on hypertension which, in turn, may be a counterindication for anaesthesia. In such cases percutaneous transluminal angioplasty with intravascular brachytherapy may be considered to be the treatment of choice.

Piotr Walichiewicz M.D. Ph.D

Department of Radiotherapy,
The Maria Skłodowska-Curie Memorial Cancer Center
and Institute of Oncology
Wybrzeże Armii Krajowej 15
44-101 Gliwice
Poland

References

1. Johnston KW. Femoral and popliteal arteries: re-analysis of results of angioplasty. *Radiology* 1992; 183: 767-771.
2. Post MJ, Borst C, Pasterkamp G, et al. Arterial remodelling in atherosclerosis and restenoses: a vague concept of a distinct phenomenon. *Atherosclerosis* 1995; 118 Suppl: 115-123.
3. Murray RRJ, Hewes RC, White RU, et al. Long segment femoropopliteal stenoses: is angioplasty a boon or a bust? *Radiology* 1987; 162: 473-476.
4. King SB III. Restenosis following angioplasty. In: Waksman R (ed.) *Vascular Brachytherapy*. Haag Nucletron; 1996.
5. Mintz GS, Popma JJ, Pichard AD, et al. Mechanisms of later arterial responses to transcatheter therapy: A serial quantitative angiographic and intravascular ultrasound study. (abstr) *Circulation* 1994; 90: 124.
6. Staab M, Edwards W, Sritvatsa S, et al. Adventitial injury and cellular response markedly affect arterial remodeling and neointimal formation. *Circulation* 1995; 92: 1-93.
7. Waksman R, Robinson K, Signan S, et al. Balloon overstretch injury correlates with neointimal formation and not with vascular remodelling in the pig coronary restenosis model. *J Am Coll Cardiol* 1994; Feb: 138A.
8. Schopol B, Lierman D, Pohlit LJ, et al. Ir-192 Endovascular brachytherapy for avoidance of intimal hyperplasia after percutaneous transluminal angioplasty and stent implantation in peripheral vessels: 6 years experience. *Int J Rad Oncol Biol Phys* 1996; 36: 835-840.

Paper received: 3 March 2000

Accepted: 12 June 2000