

Chondrosarcoma of the larynx: a case report and review of the literature

Piotr Jackiewicz, Andrzej Kawecki, Anna Nasierowska-Guttmejer, Romuald Krajewski

Chondrosarcoma is a very rare neoplasm of the larynx. Only 250 cases of chondrosarcoma have been reported in this localization. The paper presents the case of a 61-year old man, in whom chondrosarcoma of the larynx was diagnosed. He underwent total laryngectomy as the treatment of choice. Histopathological examination of the postoperative specimen confirmed the diagnosis of mixed structure chondrosarcoma consisting of chondroma and chondrosarcoma tissue arising from the cricoid cartilage. Surgical margins were negative. Based on the literature the necessity of total laryngectomy in advanced chondrosarcoma of the larynx and problems connected with diagnosis of the tumor and with attempts of conservative treatment were also discussed. Rare occurrence, slow and silent growth and histopathological picture resembling chondroma – those factors make the proper diagnosis difficult to establish. Conservative surgery ought to be always considered. There are no criteria established which allow to apply the method of treatment that is best functionally and oncologically. Such criteria ought to be based on clinical staging and histopathological grading.

Chrzęstniakomięsak krtani; opis przypadku i przegląd literatury

Chrzęstniakomięsak (chondrosarcoma) jest rzadko występującym nowotworem krtani. Do tej pory w literaturze opisano około 250 przypadków chrzęstniakomięsaka w tej lokalizacji. W niniejszej pracy przedstawiono przypadek 46-letniego mężczyzny, u którego w oparciu o badanie kliniczne i histopatologiczne rozpoznano wysokodojrzałego chrzęstniakomięsaka krtani. Przeprowadzono radykalne leczenie operacyjne, polegające na laryngektomii. Badanie mikroskopowe materiału operacyjnego potwierdziło rozpoznanie chrzęstniakomięsaka o budowie mieszanej, złożonej z chrzęstniaka i chrzęstniakomięsaka, rozwijającego się w chrząstce pierścieniowatej. Ocena marginesów chirurgicznych wykazała całkowite wycięcie guza. W oparciu o przegląd literatury uzasadniono konieczność wykonania radykalnej laryngektomii w przypadku zaawansowanego chrzęstniakomięsaka krtani. Omówiono także problem związany z diagnozą guza oraz próbami wykonywania operacji oszczędzających. Takie czynniki jak: rzadkie występowanie choroby, powolny i skryty wzrost guza oraz obraz histopatologiczny przypominający chrzęstniaka utrudniają postawienie właściwego rozpoznania. Operacje oszczędzające, polegające na częściowej laryngektomii, powinny być zawsze brane pod uwagę. Nie ma jednak jeszcze wypracowanych kryteriów, które pozwoliłyby na zastosowanie leczenia, gwarantującego najlepsze rezultaty funkcjonalne i onkologiczne. Kryteria te powinny opierać się na stopniu zaawansowania klinicznego i stopniu dojrzałości histopatologicznej. W celu opracowania optymalnego leczenia konieczne są dalsze badania kliniczne.

Key words: chondrosarcoma, chondroma, laryngeal tumors, laryngectomy, local recurrence

Słowa kluczowe: chrzęstniakomięsak, chrzęstniak, guzy krtani, laryngektomia, wznowa miejscowa

Introduction

Chondrosarcoma is a malignant tumor arising from cartilage. Etiology is unknown. More than 50% cases occur in persons over forty [1]. Chondrosarcoma represents the second most frequent, after osteosarcoma, primary sarcoma of bone. Most frequently it develops in the pelvis (31%) followed by femur and brachial joint region. It is the most common primary malignant tumor of ribs and

sternum [2]. 10% to 12% of chondrosarcomas involve the head and neck region [3]. In this localization chondrosarcoma is placed in paranasal sinuses, at the base of the skull, in maxilla, mandible and larynx. In regards for diagnostic difficulties, and controversy related method of treatment, chondrosarcoma of the larynx requires particular interest.

Although chondrosarcoma is the second most common malignant tumor of the larynx, it represents only small amount of all laryngeal tumors [4]. Till now, there are only about 250 of cases described in the literature. A case presented in this paper, treated in The Head and Neck Cancer Department of the Maria Skłodowska-Curie

The Head and Neck Cancer Department
The Pathology Department
The Maria Skłodowska-Curie Memorial Cancer Center
and Institute of Oncology, Warsaw, Poland

Memorial Cancer Centre in Warsaw is a typical example of the laryngeal chondrosarcoma.

Case report

A 61-year old man, non-smoking for the previous fifteen years, requested otolaryngeal examination due to persistent hoarseness. In the ENT examination and during direct laryngoscopy no abnormalities were found. The biopsy specimen did not contain any malignant infiltration. During a control ENT examination performed one year later a tumour indenting the light of the pharynx was found beneath the glottis. The mucosa over the tumour was not changed. Histopathological examination of tissue obtained from the tumor revealed highly differentiated G1 chondrosarcoma. Diagnosis was confirmed at the Pathology Dept. of the Maria Skłodowska-Curie Memorial Cancer Centre in Warsaw (prof. Mioduszewska).

On admission to the Dept. of Head and Neck Cancer of the Cancer Center in Warsaw hoarseness and stridor were the main symptoms. The patient was able to speak only in a whisper. He did not complain of dyspnea and claimed satisfactory tolerance of physical exercise. On examination we found a tumor covered with unchanged mucosa, protruding from the posterior wall of the larynx, directly beneath the glottis. No other pathology was found. Chest X-rays revealed no abnormalities.

The tumour was further diagnosed by computerised tomography (CT) – magnetic resonance imaging (MRI) was not performed due to the presence of metal plates – the effect of surgical treatment of post-traumatic fracture of the tibial bone.

The CT scan showed a tumour arising from the lamina and arch of the cricoid cartilage on the left. The lateral dimension of the tumour was 25 mm, its laryngeal indentation reaching 15 mm. Its upper margin reached the thyroid cartilage and infiltrated the vocal chord. The longitudinal dimension of the tumour reached 28 mm. Numerous calcifications could be discerned within the tumour. The CT scans are presented in Figure 1.

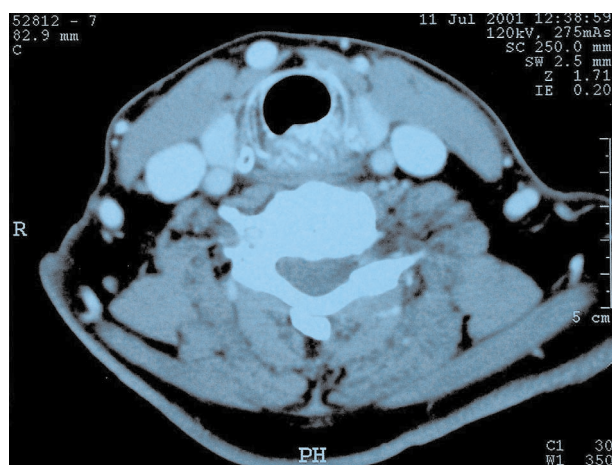

Figure 1. CT scan demonstrates infiltration of thyroid cartilage by tumor

Malignant infiltration included 75% of the cricoid cartilage circumference and almost the entire posterior wall of the larynx. The patient was referred for radical surgical treatment i.e. total laryngectomy.

Surgical details. After collar incision the sternohyoid muscles were dissected and separated (not cut). Then the larynx was dissected and cut first from the trachea and then from the pharyngeal wall and the thyrohyoid membrane. The hyoid bone with its muscular appendages was preserved intact. A double layer of stitches was used for the pharynx, which was then covered by the preserved sternohyoid muscles. The stump of the trachea was attached to the skin.

Postoperative recovery was uneventful. For the first 14 days after surgery the patient was fed via a gastric tube, which was removed on day 14.

Pathological examination of the excised larynx was performed at the Pathology Dept. of the Maria Skłodowska-Curie Memorial Cancer Centre and Institute of Oncology in Warsaw. The dimensions of the entire surgically obtained specimen were 6.5 x 4 x 4 cm. The dimensions of the tumour were 2.8 x 2.2 x 1.7 cm. It was composed of white-greyish, shiny, hard tissue with the margins surrounded by a pseudocapsule. Microscopic examination revealed mixed texture, containing both chondroma and highly differentiated chondrosarcoma. Within the sarcoma fields polynuclear cells located within cartilage lacunas were discerned. Nuclear cells were hyperchromatic and polymorphic; some with mitotic figures present. Neoplastic infiltration reached the posterior cricoarytenoid muscle, where the most narrow surgical margin was identical with the connective tissue pseudocapsule. The distance between the tumour and the margin reached 4 cm at the level of the glottis, 1.5 cm at the level of the trachea and 1.6 cm within the pharyngeal mucosa. The tumour did not infiltrate the thyroid cartilage.

The patient was under careful follow-up. He was qualified for logopaedic therapy on discharge. For 10 months after operation there have been no signs of local recurrence or metastases.

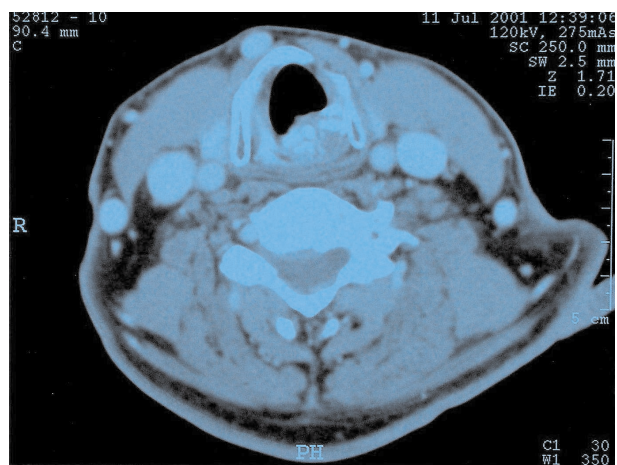


Figure 2. CT scan demonstrates tumor arising from lamina arch of the cricoid cartilage on the left

Discussion

Chondrosarcoma of the larynx is most common among individuals between 40 and 70 yrs. of age. It is more common among male subjects.

As far as etiopathology is concerned, ionising radiation remains one of the main risk factors. Literature presents cases of chondrosarcoma in patients previously treated with irradiation applied to the laryngeal region [5]. Other conditions predisposing to laryngeal chondrosarcoma are: Ollier's disease, the Maffucci syndrome and Paget's disease.

The most common localisation for laryngeal chondrosarcoma is the interior surface of the cricoid cartilage, while it is a rare finding within the thyroid cartilage. It usually develops as a submucosal mass located subglottically, infiltrating the thyroid cartilage and the vocal chords. It usually projects into the larynx causing respiratory deficiency and hoarseness. External tumour growth is a rare feature.

First clinical symptoms are not characteristic. The patient usually seeks medical attention due to prolonged hoarseness. In more advanced cases one may observe stridor and dyspnea at rest. Rarely, when external growth is observed, dysphagia or a discernable neck tumour are the earliest symptoms [6].

Slow local progression and, therefore, slow symptomatic progression combined with the most common subglottic and submucosal growth are the most common reasons for delayed diagnosis. The case we report, in which almost a year passed before correct diagnosis was made is, by no means, a singular case. Sometimes it takes some three years to make correct diagnosis [7]. One must keep in mind that histopathologic examination of specimens obtained from a submucosal tumour will usually render falsely negative results.

Cartilage tissue usually gives rise to chondromas or highly developed chondrosarcomas. Microscopical examination reveals them to be made of cartilage cells and it is often difficult to decide whether they are benign or malignant. In order to set the correct diagnosis numerous biopsies must be examined. The histopathologist searches for sarcoma fields characterised by increased cell count in which cells are placed irregularly within cartilage lacunas and divided by hyaline interstitium. Within the chondrosarcoma one may discern polymorphic and polynuclear giant cells with hyperchromatous, irregular nuclei. Sporadically mitotic figures may be observed. Laryngeal chondrosarcoma has a tendency to infiltrate blood vessels.

In this particular case the tumour, reaching some 2.8 cm in diameter was located typically – on the cricoid cartilage, it infiltrated the neighbouring tissues and was surrounded by a narrow connective tissue pseudocapsule, which developed from the surrounding tissues. Microscopically it presented not only as chondrosarcoma, but also as chondroma.

Chondrosarcoma is characterised by slow local growth and a low possibility of distant metastases. So-

me cases, characterised by low histopathological differentiation have been described. Chondrosarcoma dedifferentiatum is a unique form of the tumour of low differentiation. It is characterised by the presence of low differentiation foci not unlike rhabdomyosarcoma or fibrosarcoma within an otherwise highly differentiated tumour mass. The course of chondrosarcoma dedifferentiatum is similar to the course of other low-differentiated bone sarcomas [8].

In cases of chondrosarcoma the treatment of choice is total excision within healthy tissue margins. Due to the maiming arising from total laryngectomy in this particular localisation sparing operations must be considered. It is difficult to state when to perform sparing surgery and when to decide in favour of total laryngectomy. Some authors suggest that total laryngectomy is performed when neoplastic infiltration covers more than half the diameter of the cricoid cartilage. However there are reports of total excisions of the cricoid cartilage with concomitant reconstruction of this part of the larynx. Such procedures allow to maintain the function of the larynx and are oncologically radical [7, 9].

These decisions have to be made individually, after MRI and/or CT visualisation. In case of sparing operations recurrence is reported in over half of the patients, while in case of total laryngectomy – only in 16 % [10]. It is also important that even highly differentiated chondrosarcoma of the larynx in 10% of cases produces distant metastases [11, 12]. The risk of distant metastases depends on the natural history of the tumour and is more likely in case of recurrence. Another important issue is precise histopathological diagnosis. One biopsy obtained during direct laryngoscopy may suggest the presence of a highly differentiated tumour, but may allow for false results – chondrosarcomas of the larynx tend to be heterogeneous and often contain some amount of highly differentiated tissue. Only the examination of the entire tumour will allow for complete diagnosis. In case of low-differentiated chondrosarcomas sparing procedures cannot be considered curative.

In the case, which we report the CT scan had revealed, that neoplastic infiltration covered 75% of the diameter of the cricoid cartilage. Longitudinally the tumour infiltrated along the posterior wall of the larynx towards the arytenoid cartilage, including the vocal chord and, laterally, the thyroid cartilage. Thickening of the posterior wall of the larynx could be discerned up to its superior edge. Considering such advancement total laryngectomy was the only oncologically acceptable solution. The patient received full information concerning the character of the disease and its prognosis and gave consent to total laryngectomy.

The role of irradiation in the treatment of differentiated chondrosarcomas is controversial. Generally the tumour is considered resistant to conventional radiotherapy. However attempts are made at radical radiotherapy in highly advanced cases, where total laryngectomy is technically impossible, and in those patients who do not give consent to total laryngectomy. Literature also of-

fers reports of irradiation after incomplete resection, in cases of local recurrence and as adjuvant therapy. Although the results appear promising they must be analysed critically, because the number of reported cases is very low (altogether 13 patients) [13]. At present radiotherapy is not the recommended method of radical treatment either of the primary tumour or of the recurrence. There is also no data to suggest that it can be routinely applied as adjuvant therapy. Some hope is offered by methods, which allow for high ratio of linear energy transmission. Their results in other localisations of chondrosarcoma are very promising, however the availability of this method is very limited.

We have come across no reports of promising results of chemotherapy applied in case of highly differentiated chondrosarcomas of the larynx.

In very advanced cases with laryngeal obstruction and dyspnea, in patients with poor overall condition CO₂ laser therapy may be palliatively applied to remove airway obstruction [14].

Laryngeal chondrosarcoma is characterised by favourable prognosis. Curability reaches some 75-85%. It must be remembered that a 5-year disease free period is not the equivalent of curation, because recurrences may be observed even after 20 or 30 years after therapy completion [4].

Piotr Jackiewicz M.D.

Department of Head and Neck Cancer
The Maria Sklodowska-Curie Memorial Cancer Center
and Institute of Oncology
Roentgena 5, 02-781 Warsaw, Poland

11. Nikolai P, Ferlito A, Sasaki CT Et al. Laryngeal chondrosarcoma: incidence, pathology, biological behavior and treatment. *Ann Otol Rhinol Laryngol* 1980; 89: 567-571
12. Lavertu P, Tucker HM. Chondrosarcoma of the larynx: case report and management philosophy. *Annals of Otolaryngology, Rhinology & Laryngology*. 1984; 93: 452-456.
13. Gripp S, Pape H, Schmitt G. Chondrosarcoma of the larynx: The role of radiotherapy revisited – A case report and review of the literature. *Cancer* 1998; 82: 108-15.
14. Bough ID Jr., Chiles PJ, Fratalli MA et al. Laryngeal chondrosarcoma: two unusual cases. *Am J Otolaryngol* 1995; 16: 126-31.

Paper received: 25 March 2002

Accepted: 21 June 2002

References

1. Malawer MM, Link MP, Donaldson SS. Sarcomas of bone. W: DeVita VT Jr, Helman S, Rosenberg SA, (red.) *Cancer Principles and Practice of Oncology*. Wyd. 5. Philadelphia: Lippincot – Raven Publishers; 1997, 1785-853.
2. Pritchard DJ, Lunke RJ, Taylor WF et al. Chondrosarcoma: A clinicopathologic statistical analysis. *Cancer* 1980; 45:149-57.
3. Burkey BB, Hoffman HT, Baker SR et al. Chondrosarcoma of the head and neck. *Laryngoscope* 1990;100: 1301-5.
4. Neel HB III, Unni KK. Cartilaginous tumors of the larynx: a series of 33 patients. *Otolaryngol Head Neck Surg* 1982;90: 201-7.
5. Glaubiger DL, Casler JD, Garrett WL et al. Chondrosarcoma of the larynx after radiation treatment for vocal cord cancer. *Cancer* 1991;68: 1828-31.
6. Ross DE. Chondrosarcoma of the larynx invading thyroid gland. *Laryngoscope* 1971; 81: 379-86.
7. Bogdan CJ, Maniglia AJ, Eliachar I et al. Chondrosarcoma of the larynx: Challenges in diagnosis and management. *Head and Neck*1994;16: 127-34.
8. Nakayama M, Brandenburg JH, Hafez GR. Dedifferentiated chondrosarcoma of the larynx with regional and distant metastases. *Ann Otol Rhinol Laryngol* 1993; 102: 785-91.
9. Nakano Y, Asakura K, Himi T et al. Chondrosarcoma of larynx: a case successfully reconstructed after total cricoidectomy. *Auris, Nasus, Larynx*. 1999; 26:207-11.
10. Kozelsky TF, Bonner JA, Foote RL et al. Laryngeal chondrosarcomas: The Mayo Clinic experience. *J Surg Oncol* 1997;65:269-73.