

Long-term results of postoperative radiotherapy in adult patients with incompletely excised infratentorial low grade astrocytoma

Elżbieta Pluta, Bogdan Gliński, Teresa Szpytma, Jadwiga Nowak-Sadzikowska

Introduction. Infratentorial low grade astrocytoma (ILGA) occurs rarely in adult patients and accounts for about 3% of all intracranial tumors. The basic method of treatment for ILGA is surgery. Complete resection results in high local control rate and the role of postoperative irradiation in management of partially resected tumors is not clearly determined.

The aim of this study was to evaluate the efficacy of postoperative irradiation in adult patients with incompletely excised ILGA.

Material and methods. Between 1975 and 1995, thirty one adult patients with incompletely excised ILGA received postoperative irradiation with curative intent. All patients were treated with megavoltage gamma rays (^{60}Co). The total dose ranged from 50 to 60 Gy (mean; 54 Gy) and was delivered with daily fraction of 1.8-2 Gy. The treatment volume covered the tumor being area with a margin of 1-2 cm.

Results. Tolerance to treatment has been found to be good in 30 patients (97%). The overall 15-year actuarial survival rate was 62% in the entire group. Young patients, up to twenty years of age achieved a 15-year overall actuarial survival rate of 85%, older patients – 46%. This difference was statistically significant ($p=0.0205$).

Conclusion. Conventionally fractionated postoperative radiotherapy with doses of 50 to 60 Gy may improve long term results of adult patients with ILGA after uncomplete resection. Age is a significant prognostic factor – young patients, up to twenty years of age, show best survival.

Odległe wyniki pooperacyjnej radioterapii chorych dorosłych na podnamiotowe gwiazdki mózgu o niskiej złośliwości histologicznej

Wstęp. Podnamiotowe gwiazdki o niskiej złośliwości histologicznej (PGNZH) stanowią około 3% wszystkich guzów śródczaszkowych u dorosłych. Podstawową metodą leczenia tych nowotworów jest neurochirurgia, która w przypadku radykalnego usunięcia guza pozwala na uzyskanie wysokiego odsetka kontroli miejscowej. Rola uzupełniającego napromieniania po zabiegach niedoszczętnych nie jest określona w sposób jednoznaczny.

Cel pracy. Ocena wartości pooperacyjnej radioterapii chorych dorosłych na PGNZH po nieradykalnych zabiegach chirurgicznych.

Materiał i metody. W latach 1975-1995 napromieniano pooperacyjnie 31 chorych dorosłych na PGNHZ po nieradykalnych zabiegach chirurgicznych drogą kraniotomii. Radioterapię prowadzono w warunkach telegammaterapii ^{60}Co . Dawka całkowita wynosiła od 50 do 60 Gy (średnia 54 Gy), frakcjonowana po 1,8-2 Gy dziennie. Teren napromieniany obejmował pozostałość guza z marginesem 1-2cm.

Wyniki. Dobrą tolerancję leczenia wykazało 30 chorych, tj. 97% materiału. W całej omawianej grupie prognozowane całkowite przeżycie 15 letnie wyniosło 62%. Dla chorych młodych w wieku do 20 lat wyniosło ono 85%, w porównaniu do 46% w grupie chorych starszych. Różnica w przeżyciach była statystycznie istotna ($p=0,0205$).

Wnioski. Klasycznie frakcjonowana radioterapia pooperacyjna w dawce 50-60 Gy może poprawić przeżycie odległe chorych na PGNZH po nieradykalnych zabiegach chirurgicznych, Wiek chorych w istotny sposób determinuje rokowanie, najdłuższe przeżycia obserwuje się u chorych do 20 roku życia.

Key words: astrocytoma, radiotherapy

Słowa kluczowe: gwiazdziak, radioterapia

Introduction

Infratentorial low grade astrocytoma (ILGA) occurs rarely in adult patients and accounts for 3% of all intracranial tumors [1].

The therapeutic management of ILGA is almost exclusively surgical. Total excision is the treatment of choice, when possible, but approximately 40% of patients undergo subtotal resection. It may still be followed by prolonged survival and the role of postoperative irradiation in this group of patients is not clearly determined [1]. The objective of this study is to evaluate the efficacy of postoperative radiotherapy in adult patients with incompletely excised ILGA.

Material and methods

Between 1975 and 1995, 719 adult patients with primary intracranial tumors received postoperative irradiation with curative intent in the Center of Oncology in Cracow. The tumor was supratentorial in 625 (87%) cases, and infratentorial in 94 (13%). The distribution of pathological characteristics of 94 infratentorial tumors is given in Table I.

Table I. Histology of 94 infratentorial tumors treated with postoperative irradiation between 1975 and 1995 in Center of Oncology in Cracow (adult patients only)

Histology	N	%
ILGA	31	32
TBVO	41	43
Medulloblastoma	16	17
High grade astrocytoma	3	4
*other	3	4

ILGA- infratentorial low grade astrocytoma

TBVO-tumors of blood vessel origin

* two cases of ependymoma and one case of sarcoma

The present series consists of 31 cases of infratentorial low grade astrocytomas (ILGA). All patients underwent open craniotomy: for partial resection in 18 cases, and for subtotal removal in 13 cases. The diagnosis was histologically confirmed, all surgical specimens were evaluated by the same pathologist according to the criteria of the World Health Organisation classification [2]. By histological subtype six were fibrillary, twelve protoplasmic, and thirteen represented gemistocytic variant. Clinical characteristics of these 31 patients are presented in Table II.

Radiotherapy was started three to five weeks after surgery and was given with a ⁶⁰ Cobalt unit. The total dose ranged from 50 to 60 Gy (mean; 54 Gy) delivered with daily fractions of 1.8-2 Gy. We applied the two-field technique (oblique portals with wedges) in 26 patients and the three-field technique (parallel-opposed lateral portals with wedges and posterior) in 5 patients. The treatment volume covered the tumor residual with a margin of 1-2 cm.

Results

Tolerance to treatment

The treatment was generally well tolerated. All patients had mild erythema of the scalp. Signs and symptoms of in-

Table II. Clinical characteristics of 31 adult patients with ILGA treated with postoperative irradiation in the Center of Oncology in Cracow between 1975 and 1995

Characteristics	Number of patients	(%)
Age (years)		
16-20	11	35
21-45	20	65
Gender		
male	17	55
female	14	45
Tumor location		
hemisphere	22	71
vermis	9	29
Surgery		
subtotal resection *	11	35
partial**	20	65
Karnofsky's index [3]		
70% and more	21	68
60% and less	10	32
Neurological status according to the EORTC/MRC scale [4]		
1, 2	18	58
3	10	32
4	3	10
Dose		
50 Gy	15	48
over 50 Gy	16	52

* Subtotal resection – removal of the whole mass of the tumor except elements infiltrating deep brain structures

** Partial resection – removal of only some parts of tumor

creased intracranial pressure occurred in two cases, and resolved with steroid administration. One patient had intermittent vomiting which caused a three-day break in radiotherapy.

Survival

The length of survival was measured from the day of surgery, survival plots were generated using the Kaplan-Meier method [5]. The survival data was analysed using the Gehan modification of the Wilcoxon rank-sum analysis for comparing arbitrarily censored samples [6]. The survival of all 31 patients with ILGA is presented in Fig.1. and survival according to the age of patients is shown in Fig. 2.

In the whole group actuarial survival rate at 15-years was 62%. Actuarial 15-year survival for 12 patients in the age up to twenty years was 85%, and 46% for patients over than 20 years of age. The difference in survival was statistically significant ($p=0.0205$).

Treatment results according to clinical and therapeutic characteristics are presented in Table III.

Median survival time (MST) according to the clinical and therapeutic characteristics.

Recurrence was observed in 8 patients. Two relapses occurred within the first 5 years of follow-up, four between 6 and 8 years and two relapses were observed after

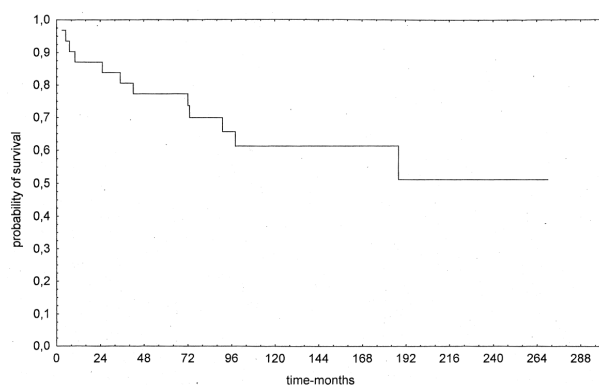


Figure 1. Actuarial overall survival of 31 patients with ILGA

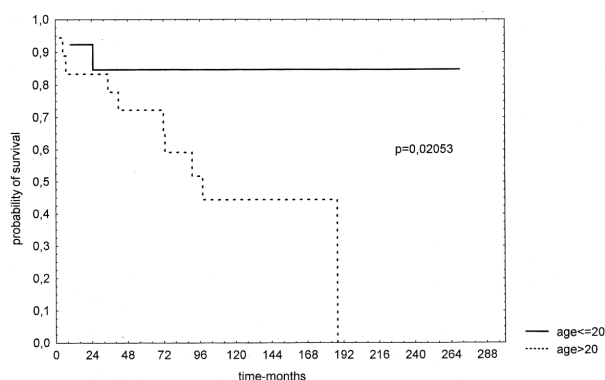


Figure 2. Actuarial overall survival according to the age of patients

Table III. Median survival time (MST) of 31 adult patients with ILGA treated with postoperative irradiation in the Center of Oncology in Cracow between 1975 and 1995 according to the clinical and therapeutic factors

Characteristics	MST(years)
Age (years)	
20 and less	11
more than 20	6
Gender	
male	10
female	8
Tumor location	
hemisphere	11
vermis	10
Neurological status	
1,2	10
3,4	7
Karnofsky's index [3]	
70 and more	11
50-60 and less	10
Surgery	
subtotal resection	11
partial	9
Total dose	
50 Gy	8
more 50 Gy	9

10 years of observation. All recurrences were located in the posterior fossa.

Discussion and conclusions

The place of radiation therapy in the treatment of well differentiated infratentorial astrocytoma in adults continues to be uncertain, in contrast to childhood cerebellar tumors. It is well known that two features distinguish brain tumors in children from those in adults. The most significant is a higher percentage of gliomas in children, due to the infrequent occurrence of other common tumors (ependymoma, meningioma), usually found in adults. The other important feature is that childhood neoplasms occur in the posterior fossa in about 65 to 75 per cent of the cases, whereas in adults tumors occur in the

supratentorial region. Adult patients with ILGA are quite rarely referred for radiotherapy, and for some phase of management. Therefore only a few institutions have enough cases to permit irradiation effect evaluation and the observation of the full course of the disease. Scanning the literature of the last twenty years we have found only four papers dealing with ILGA in adults [1, 7-9]. All this data represents a retrospective view and usually discusses small groups of patients who had been treated during a long period of time. It also demonstrates that the use of radiotherapy in the treatment of ILGA after macroscopically incomplete resection is controversial.

In the study of Leibel et al. the treatment groups were examined according to the completeness of surgical resection. For patients with incomplete resection, treated by surgery alone, the 5- and 10-year survival rates were 19% and 11% respectively. These rates were increased to 46% and 35% respectively, when radiation therapy was also given [8]. Since there is no reason to believe that those irradiated constituted a more favourable patient population it seems reasonable to conclude that irradiation significantly delayed death and may have led to permanent control of disease in some patients. In contrast, in Ilgren's data, of the 43 patients who had survived subtotal removal of tumors 11 (26%) underwent radiotherapy, whilst the remaining 32 (74%) received no further tumor specific treatment. Analysis of the data revealed no significant difference between the two groups in survival or recurrence-free survival rates [1].

To obtain a clearer view on the matter, we have reviewed our material from the years 1975 to 1995, and have tried to correlate the clinical and therapeutic aspects of 31 adult patients with incompletely resected ILGA who had received postoperative radiotherapy. The 10- and 15-year actuarial survival rates in our series were 78% and 62% respectively. Our results are comparable to those reported by other authors (Table IV.)

Our results indicate that age is the principal variable determining the survival times of patients. This finding is not new and has been noted in other reports. Hayostec has observed that prognosis is directly related to the age of patients with ILGA. Young subjects (up to twenty years of age) achieved the 10-year survival rate of 89%, as compared to 51% for older patients [7]. According to his ob-

Table IV. Results of postoperative irradiation in adults with incompletely removed ILGA

Author	No of patients	10-year survival
Ilgren et al. [1]	13	46%
Hayostek et al. [7]	44	61%
Leibel et al. [8]	11	64%
Liebner et al.[9]	18	50%
Present series	31	62%

servations survival rates in the present series were of 85% and 46% respectively.

The extent of surgery in our study did not correlate with survival. There was no statistical difference in prognosis between patients who had undergone subtotal resection of the tumor and those who had undergone partial excision only. The median survival time (MST) for the former group was 12 years, compared to 8 years for the latter. It should be noted, however, that all operations were non-radical, and thus the differentiation between subtotal and partial removal is subjective and may be conducted with a high risk of error.

Tumor location had no influence on survival time. For patients with hemisphere and vermis sites, the MST was 11 and 9 years respectively. The relevance of tumor location is unclear, some authors have observed better outcome in patients in whom tumors were located in the vermis, whereas other reported contradictory observations. One may speculate that complete removal of tumor tissue is easier to achieve in vermis located tumors [7, 9].

The sex of the patients did not significantly affect survival, similarly to Leibel's series [8].

We have not proved a prognostic value of Karnofsky's Performance Status and Neurological Status (NS) on the outcome of our patients, contrary to Hayostek's data in which NS appeared to be one of the most significant prognostic factors [7].

In our study, the outcome of patients who received a total dose of irradiation of 50 Gy was no worse than that of patients treated with higher doses up – to 60 Gy. Corresponding MST values were 8 and 9 years. This difference was not statistically significant. A review of literature suggests that optimal range of the total dose in radiotherapy of ILGA seems to lie somewhere between 50 and 60 Gy [1, 7-9].

Concluding, we can say that our experiences confirms that combined surgery plus radiotherapy with doses of 50 to 60 Gy may improve long term results in adult patients with infratentorial low grade astrocytomas after uncomplete resection. In this group of patients age is a significant prognostic factor, young subjects up to twenty years of age benefit of the best survival.

Furthermore, our findings must be viewed with caution because they are based on retrospective data of a treatment regimen used over the last 20 years. The optimal use of radiotherapy in the management of ILGA still ne-

eds be validated by the results of randomised clinical trials.

Elżbieta Pluta M.D.

Department of Radiotherapy
The Maria Skłodowska-Curie Memorial Cancer Center
and Institute of Oncology
Garncarska 11
31-115 Cracow, Poland
e-mail: z5plutae@cyf-kr.edu.pl

References

1. Ilgren EB, Stiller CA. Cerebellar astrocytomas: therapeutic management. *Acta Neurochir* 1986; 86: 11-26.
2. Zulch KJ. *Histological Classification of the Tumours of the Central Nervous System*. WHO; 1979, 29-30.
3. Karnofsky DA, Burchenal JM. The clinical evaluation of chemotherapeutic agents in cancer. In: Mc Lead J (ed.). *Evaluation of chemotherapeutic agents*. New York: Columbia Univ. Press; 1994, 191-205.
4. Karim ABF, Bleeche NM. A randomized trial on the efficacy of radiation therapy of the cerebral gliomas. Joint EORTC/MRC Protocol 22845, Appendix II, 1986.
5. Kaplan ME, Meier P. Non parametric estimation from incomplete observations. *J Am Stat Assoc* 1958; 53: 457-481.
6. Gehan EA. A generalized Wilcoxon test for comparing arbitrarily censored samples. *Biometrika* 1965; 52: 203-223.
7. Hayostek CJ, Shaw EG, Scheithauer B. Astrocytomas of the cerebellum. *Cancer* 1993; 15: 856-869.
8. Leibel S.A, Sheline G.E. The role of radiation therapy in the treatment of astrocytomas. *Cancer* 1975; 35: 1551-1557.
9. Liebner EJ, Pretto JI, Hochhauser M. Tumors of the posterior fossa in childhood and adolescence. *Radiology* 1964; 82: 193-201