

Ornithine decarboxylase activity as a marker of premalignancy in the gastrointestinal tract

Tomasz Wocial¹, Witold Bartnik¹, Krzysztof Przytulski¹, Anna Nasierowska-Guttmejer², Jerzy Ostrowski¹, Eugeniusz Butruk¹

Aim. There is no biochemical marker of premalignancy known to antedate the appearance of histological changes in the gut epithelium. Although increased ornithine decarboxylase (ODC) activity has been described as a marker of neoplastic potential, studies based on large material to assess the value of its measurement have not been reported. The aim of this study was to determine mucosal ODC activities in patients with premalignant and malignant conditions of the GI tract and to try to identify high risk patients.

Material and methods. Mucosal biopsy samples were obtained during endoscopy from 221 patients. ODC activity was measured using a L-[¹⁴C]-ornithine bioassay and results were expressed in pmol/mg protein/hour. Conventional histology was used to detect the presence of dysplasia, which was graded according to established criteria.

Results. ODC activity was significantly higher in all premalignant and malignant conditions than in normal tissues. However, our results have shown that high ODC activity does not always indicate malignancy and low activity does not exclude the increased neoplastic potential. We did not observe significant differences related to the degree of dysplasia in the epithelium.

Conclusion. Inability to differentiate premalignant conditions from cancer indicates that ODC bioassay is not a valuable marker of increased neoplastic potential.

Aktywność dekarboksylazy ornityny jako marker zmian przedrakowych w przewodzie pokarmowym

Cel. Dotychczas nie ma biochemicznego markera przemiany przedrakowej, który poprzedza pojawienie się zmian histopatologicznych w błonie śluzowej. Chociaż uważano, że takim markerem może być podwyższona aktywność dekarboksylazy ornityny (ODC), nie było dotychczas przekrojowych badań, przeprowadzonych na różnorodnym materiale, które potwierdziłyby przydatność oznaczeń tego enzymu. Celem pracy było określenie aktywności ODC w błonie śluzowej u chorych ze zmianami przedrakowymi i rakami przewodu pokarmowego oraz próba identyfikacji osób z wysokim ryzykiem nowotworowym.

Materiał i metoda. Zbadano 221 wycinków błony śluzowej pobranych w czasie badania endoskopowego. Aktywność ODC oznaczano za pomocą metody enzymatycznej z użyciem L-[¹⁴C]-ornityny, a wyniki przedstawiano w pmol/mg białka/godz. Histopatologicznie określano stopień dysplazji w badanych gruczołakach.

Wyniki. Aktywność ODC była znamienne wyższa we wszystkich stanach przedrakowych i rakach w porównaniu do prawidłowej błony śluzowej. Jednak wyniki badań wskazują, że wysoka aktywność enzymu nie zawsze wskazuje na istnienie nowotworu złośliwego, a niska aktywność nie pozwala wykluczyć zwiększonego ryzyka nowotworowego. Nie stwierdzono istotnych różnic w aktywności ODC w zależności od stopnia dysplazji w nabłonku.

Wniosek. Niemożność odróżnienia stanów przedrakowych i raków wskazuje, że aktywność ODC, oznaczana metodą enzymatyczną, nie może być uznana za przydatny marker zwiększonego ryzyka przemiany nowotworowej w przewodzie pokarmowym.

¹ Department of Gastroenterology, Medical Center for Postgraduate Education

² Department of Pathology, The Maria Skłodowska-Curie Memorial Cancer Center and Institute of Oncology, Warsaw, Poland

Key words: ornithine decarboxylase (ODC), polyamines, premalignant conditions in the gastrointestinal tract, markers of premalignancy

Słowa kluczowe: dekarboksylaza ornityny (ODC), poliaminy, stany przedrakowe w przewodzie pokarmowym, markery przednowotworowe

Introduction

Ornithine decarboxylase is the first and also the rate-limiting enzyme in the polyamine pathway and, therefore, a key regulatory enzyme in growth processes [1]. It converts ornithine to putrescine. ODC induction and putrescine accumulation occur in phases G₁ and G₂ of the cell cycle, whereas spermine and spermidine accumulate in phase S, together with RNA and DNA synthesis [2, 3]. Thus, changes in ODC activity reflect the rate of macromolecular synthesis. Sustained high ODC levels have been implicated as an essential component of tumour development and elevated levels have been found during neoplastic transformation. ODC activity in tumour tissue is generally several times higher than in the surrounding normal tissue or within inflamed areas [4, 5]. Preliminary studies have suggested that ODC activity can be a useful marker of neoplastic potential, being altered in certain premalignant conditions of the gastrointestinal tract. Increased ODC activity was found in the colonic mucosa in familial adenomatous polyposis (FAP). This increase was relatively slight in morphologically normal mucosa, but rose progressively in adenomatous polyps [6]. Among the FAP patients rectal ODC activity seemed to decrease in time after colon resection and ileorectal anastomosis [7, 8]. High ODC levels were reported in patients with sporadic colorectal adenomas, both in tumours and in morphologically normal mucosa [9, 10]. Moreover, some studies have suggested, that there is an important correlation between the activity of the enzyme and the presence of dysplasia in the epithelium. ODC levels were higher in the dysplastic Barrett's oesophageal mucosa than in the columnar epithelium without dysplasia [11, 12]. This data, usually based on small groups of patients, has not been confirmed in the course of studies based on large and varied clinical material.

We have examined 221 endoscopic biopsy specimens obtained from individuals with a variety of upper and lower gastrointestinal conditions known to predispose to malignancy, such as gastric atrophy in pernicious anaemia, chronic superficial and atrophic gastritis, previous gastric surgery, sporadic gastric, duodenal and colonic adenomatous polyps, familial adenomatous polyposis and extensive ulcerative colitis. We have performed 663 measurements (all assays were done in triplicate) to determine the relative activity of ODC in these tissues in comparison to normal controls and gastrointestinal cancers. In order to correlate ODC activity with the degree of dysplasia simultaneous biopsy specimens for histological grading were taken.

Material and methods

Upper GI tract studies

We studied biopsy specimens taken from control subjects (n=26), who had upper abdominal symptoms but normal upper GI endoscopy, subjects with chronic superficial gastritis (n=15), chronic atrophic gastritis (n=10), pernicious anemia (n=5), operated stomachs (partial gastrectomy, vagotomy and pyloroplasty) (n=20), gastric adenomas (n=15) and duodenal adenomas (n=15). Biopsies from proven gastric cancers (n=15) and cancers of the major duodenal papilla (n=10) were used as positive controls.

Colorectal studies

We studied biopsies from normal individuals, who were judged by the clinician to have functional symptoms and who had normal investigation results (including sigmoidoscopy or colonoscopy and biopsy – n=12), patients with extensive ulcerative colitis lasting longer than 10 years, currently active or quiescent (n=20), individuals with FAP (n=11) and adenomas (n=30). The extent and activity of ulcerative colitis were assessed using clinical, colonoscopic and histological criteria. Patients with FAP were studied before total colectomy. No colon cancers were found in the surgical specimens obtained from these patients. All studied sporadic adenomas were removed by endoscopic snare polypectomy. Colon cancer biopsies (n=17) served as positive controls.

Histopathological studies

The type of gastritis was based on the updated Sydney system [13]. In patients with ulcerative colitis an additional biopsy specimen was obtained from a site adjacent to that used for the ODC assay for histological grading of the degree of inflammation [14]. In patients with colonic adenomas dysplasia was evaluated and graded according to the generally accepted system described as low-, medium- or high-grade dysplasia [15]. The person grading specimens was blinded as to the ODC results.

ODC assay

Mucosal ornithine decarboxylase was assayed using a method previously described [16, 17]. Mucosal specimens were homogenised immediately at the endoscopy unit using Polytron PT1200 (Kinematica AG) in 300 ul of buffer containing 50 mM Hepes-NaOH (pH 7.5), 2.5 mM dithiothreitol (DTT), 0.25 mM pyridoxal 5-phosphate and 0.1 mM EDTA. Supernatants were frozen in -70°C until the ODC assay was performed. The reaction mixture consisted of 20 ul of homogenate, 0.25 mM pyridoxal 5-phosphate, 2.5 mM DTT, 50 mM Hepes-NaOH (pH 7.5), 0.1 mM EDTA with 0.2 uCi of L-[¹⁴C]-ornithine hydrochloride (Amersham International) in a total volume of 40 ul. The reaction tube was sealed with a plastic tip in which was embedded a 1.0 x 4.0 cm. square of Whatman no 1 filter paper soaked with 40 ul of beta-phenylethylamine. Tubes were incubated at 37°C for 60 minutes and the reaction was then stopped by adding 200 ul of 2 M citric acid. After further 60 minutes of incubation, the filter paper was removed, placed in 10

ml of scintillation liquid and counted in a Beckman's LS 6000 IC scintillation counter. Results were expressed as pmol of $[^{14}\text{C}]\text{O}_2$ released per hour per mg of tissue protein. The protein concentration of the homogenate was measured using the Bio-Rad Protein assay. All assays were performed in triplicate and included negative controls.

Statistical analysis

Results were presented as medians and interquartile ranges. Differences between groups were assessed by analysis of variance (ANOVA) and were considered to be significant if $p < 0.05$.

Results

Upper GI tract studies

Median mucosal ornithine decarboxylase activity was similar in the normal stomach (164, interquartile range (IQR) 108-270 pmol/mg protein/h) and in the duodenum (121, IQR 41-300 pmol/mg protein/h). ODC activity was significantly higher in biopsies from all studied pre-malignant conditions than in those from normal tissues, both in the stomach and the duodenum (Figure 1 and Figure 2). Although increased ODC activity was noted in patients with gastritis (652, IQR 446-1023 pmol/mg protein/h), no significant differences were observed regarding the type of inflammation (gastric atrophy in pernicious anaemia, chronic superficial or atrophic gastritis – Table I). Subjects, who had undergone gastric

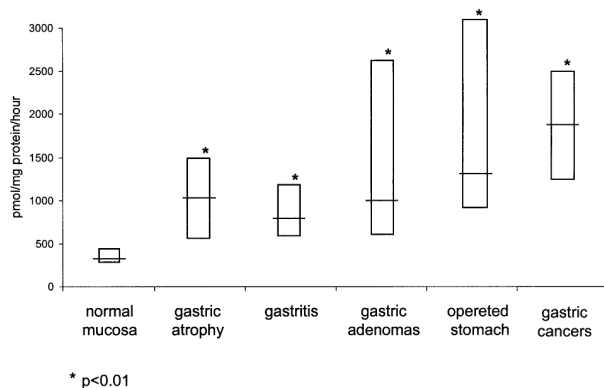


Figure 1. ODC activity in premalignant gastric conditions and gastric cancers in comparison to normal mucosa (medians with IQR)

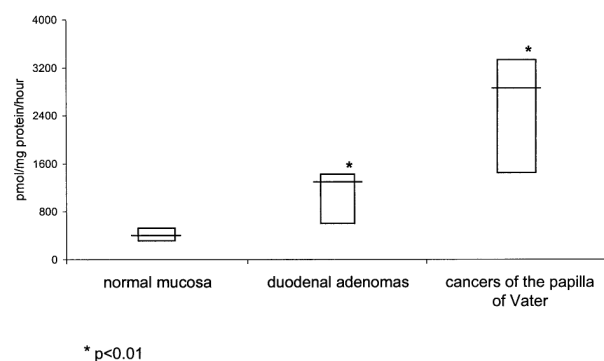


Figure 2. ODC activity in duodenal adenomas and cancers of the papilla of Vater in comparison to the normal duodenal mucosa (medians with IQR)

Table I. ODC activity in individuals with pernicious anaemia, chronic atrophic gastritis and chronic superficial gastritis (in pmol/mg protein/h)

Type of gastritis	Number	Median	Interquartile range
Gastric atrophy in pernicious anaemia	5	957	420-1478
Atrophic gastritis	10	1004*	597-1187
Superficial gastritis	15	1136*	430-1786

* $p > 0.05$ compared to median in gastric atrophy in pernicious anaemia

surgery 10 years prior to the study, had ODC activities similar to those observed in subjects with gastric or duodenal adenomas (1204, IQR 776-3213 vs 896, IQR 481-2543 and 1176, IQR 358-1336 pmol/mg protein/h, respectively). However, because of an overlap between the studied groups, ODC activity in the premalignant conditions did not differ significantly from that found in confirmed cancers ($p > 0.05$).

Colorectal studies

Median ODC activity in the normal colonic mucosa was 185 (IQR 41-300) pmol/mg protein/h. This activity was significantly elevated in the adenomatous polyps (1423, IQR 804-2198), familial adenomatous polyposis (929, IQR 75-1329), as well as in extensive ulcerative colitis (526, IQR 178-1309). However, because these results partly overlapped with those found in confirmed colon cancers (3582, IQR 1599-4654), high ODC activities did not always indicate premalignancy and low activities could not exclude an increased neoplastic potential (Figure 3).

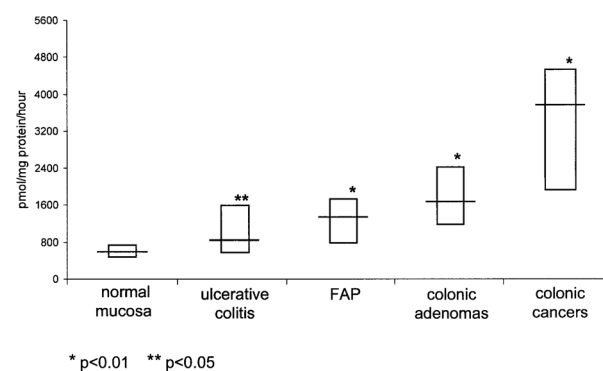


Figure 3. ODC activity in colonic premalignant conditions and cancers in comparison to normal mucosa (medians with IQR)

When subjects with ulcerative colitis were stratified into groups according to the clinical activity of the disease, a significant difference was recorded (Table II). There was no correlation between ODC activity and the degree of dysplasia in the colonic adenomatous polyps (Table III).

Table II. ODC activity in extensive ulcerative colitis in remission and in the active phase of the disease (in pmol/mg protein/h)

Activity of ulcerative colitis	Number	Median	Inrequantile range
Remission	9	289	186-345
Active disease	11	526*	399-1098

* p<0.01 compared to median in remission

Table III. ODC activity in colonic adenomas with low and/or medium grade and high grade dysplasia (in pmol/mg protein/h)

Degree of dysplasia	Number	Median	Inrequantile range
Low and/or medium grade	25	1523	835-2786
High grade	16	1423*	624-2564

* p>0.05 compared to median in low and/or medium grade dysplasia

Discussion

An ideal marker of proliferation and malignancy should be universal and should appear early in the cell cycle. Its level should increase simultaneously with proliferation and decrease when growth rates decline. It should be easily monitored and reflect rapid changes in proliferation. An optimal marker should also have a short half-life time permitting the assessment of growth arrest when the marker decays. Ornithine decarboxylase seems to be universal and fulfills these requirements. This enzyme appears during phase G₁ of the cell cycle and has an extremely short half-life (15-20 min) [3]. Changes in ODC activity correspond well with other growth parameters, although measurements are somewhat time-consuming and complicated for routine use. Initial studies performed on tissues of the human gastrointestinal tract were encouraging and suggested that ODC activity could be an accurate indicator of increased neoplastic potential [18, 19, 20]. There were reports of significant increases of this enzyme activity in colonic adenomas compared to normal-appearing tissue [9]. Rectal mucosal ODC activity has been shown to be higher in symptomatic patients with familial adenomatous polyposis than in asymptomatic family members. It was also elevated in abnormal polypoid mucosa, as compared with normal colon of FAP individuals [6]. Increased ODC activity found in dysplastic Barrett's epithelium suggested that it might be a useful marker for upper gastrointestinal tract malignancy [11, 12]. However, more recent studies were less optimistic. The importance of elevated ODC activity has been questioned mainly because of the overlap between normal and abnormal mucosal activities [21, 22]. Large inter-individual variations in the magnitude of increased enzyme activity were observed in the same gastrointestinal tumors. Some variations might be caused by intrinsic sampling problems [23, 24]. Although literature on ODC and polyamines is extensive, there have been no longitudinal studies to assess the serial use

of these measurements and their predictive value in the gastrointestinal malignancy.

In this study, we assessed the value of ODC activity as a potential marker of malignant risk both in the upper and lower gastrointestinal tract by comparing measurements in the normal epithelium, three types of proven cancers and in eight conditions that are known to predispose to malignancy. 221 mucosal biopsy samples were immediately homogenized in the endoscopy unit and stored at -70°C in order to conserve all the activity of this short-lived enzyme. We also modified the assessment of protein concentration in the supernatants to eliminate the influence of dithiothreitol on the final results. DTT has an ability to reduce copper and interfere with the standard protein assays. Tissue handling and storage are important factors in the observed variability of ODC measurements. The median ODC activities in normal tissues were similar in the upper and lower GI tract, although we recorded wide ranges within the studied groups. Significantly higher values characterized various premalignant conditions, and the highest activity was observed in confirmed cancers. However, because of overlapping results our measurements could not differentiate between these conditions. In other words, high activities did not always indicate premalignancy or malignancy and low values could not exclude increased neoplastic potential. In addition, no correlation was found between ODC activity and the degree of dysplasia in the colonic adenomas.

The exact mechanism of increased activity in dysplastic tissue remains unknown. Higher ODC values in the active phase of extensive ulcerative colitis (as compared to remission) might be caused by more increased regenerative processes in the colonic epithelium, rather than by increased neoplastic potential. We observed no differences within the stomach as far as the type of inflammation is concerned.

To summarize, we have identified differences in mucosal ornithine decarboxylase activity between control cases and many disease states. No significant differences have been shown, however, between premalignant and malignant conditions affecting the stomach, duodenum or colon. The degree of histological abnormality, such as epithelial dysplasia, did not correspond to the enzyme activity. The inability to differentiate groups at risk of gastrointestinal malignancy from cases of confirmed cancer indicates that ODC bioassay is not a valuable marker of increased cancer potential.

Prof. Witold Bartnik MD, PhD

Department of Gastroenterology
 Medical Center for Postgraduate Education
 The Maria Skłodowska-Curie Memorial Cancer Center
 and Institute of Oncology
 Roentgena 5, 02-781 Warsaw, Poland

References

1. Pegg AE. Recent advances in the biochemistry of polyamines in eukaryotes. *Biochem J* 1986; 234: 249-62.
2. Heby O, Persson L. Molecular genetics of polyamine synthesis in eukaryotic cells. *Trends Biochem Sci* 1990; 172: 153-8.
3. Hayashi S. Ornithine decarboxylase: Biology, Enzymology and Molecular Genetics. New York: Pergamon Press; 1989, 3-27.
4. Scalabrino G, Ferioli ME. Poliamins in mammalian tumours. *Adv Cancer Res* 1981; 35: 151-268.
5. Rozhin J, Wilson PS, Bull AW et al. Ornithine decarboxylase activity in the rat and human colon. *Cancer Res* 1984; 44: 3226-30.
6. Luk GD, Baylin SB. Ornithine decarboxylase as a biologic marker in familial colonic polyposis. *N Eng J Med* 1984; 311: 80-3.
7. Patchett SE, Alstead EM, Trzeciak L et al. Rectal mucosal ornithine decarboxylase activity in familial adenomatous polyposis after ileorectal anastomosis. *Gut* 1994; 35: 1624-6.
8. Farmer KCR, Phillips RKS. Colectomy with ileorectal anastomosis lowers rectal mucosal cell proliferation in familial adenomatous polyposis. *Dis Colon Rectum* 1993; 36: 167-71.
9. McGarrity TJ, Peiffer LP, Bartholomew MJ et al. Colonic polyamine content and ornithine decarboxylase activity as markers of adenomas. *Cancer* 1990, 66: 1539-43.
10. Narishawa T, Takahashi M, Niwa M et al. Increased mucosal ornithine decarboxylase activity in large bowel with multiple tumours, adenocarcinoma and adenoma. *Cancer* 1989; 63: 1572-6.
11. Garewal HS, Sampliner R, Gerner E et al. Ornithine decarboxylase activity in Barrett's esophagus: a potential marker for dysplasia. *Gastroenterology* 1988; 94: 819-21.
12. Garewal HS, Sampliner R, Alberts D et al. Increase in ornithine decarboxylase activity associated with the development of dysplasia in Barrett's oesophagus. *Dig Dis Sci* 1989; 34: 312-4.
13. Dixon MF, Genta RM, Yardley JH et al. Classification and grading of gastritis. The updated Sydney system. *Am J Surg Pathol* 1996; 20: 1161-81.
14. Ridell RH, Goldman H, Ransohoff DF. Dysplasia in inflammatory bowel disease: standardized classification with provisional clinical application. *Hum Pathol* 1983; 14: 931-68.
15. Morson BC, Dawson IMP, Day DW et al. Benign epithelial tumours and polyps. In: Morson and Dawson's gastrointestinal pathology, Ed 3. Oxford, London, Edinburgh, Boston, Melbourne: Blackwell Scientific Publications; 1990: 563-96.
16. Beaven MA, Wilcox G, Terpstra GK. A microprocedure for the measurement of $^{14}\text{CO}_2$ release from [^{14}C]carboxyl-labelled amino acids. *Anal Biochem* 1978; 84: 638-41.
17. Ostrowski J, Wojciechowski K, Konturek SJ et al. Inhibitory effect of EGF on secretory response of parietal cells is associated with an induction of ODC. *Am J Physiol* 1993; 264: C1428-33.
18. Braverman DZ, Stankiewicz H, Goldstein R et al. Ornithine decarboxylase: an unreliable marker for the identification of population groups at risk for colonic neoplasia. *Am J Gastroenterol.* 1990; 85: 723-6.
19. Luk GD, Silverman AL, Giardianello FM. Biochemical markers in patients with familial colonic neoplasia. *Semin Surg Oncol* 1987; 3: 126-32.
20. Lipkin M. Biomarkers for increased susceptibility to gastrointestinal cancer. Their development and application to studies of cancer prevention. *Gastroenterology* 1987; 92: 1083-6.
21. Desai TK, Parikh N, Bronstein JC et al. Failure of rectal ornithine decarboxylase to identify adenomatous polyp status. *Gastroenterology* 1992; 1103: 1562-7.
22. Sandler RS, Ulshen MH, Lyles CM et al. Rectal mucosal ornithine decarboxylase activity is not a useful marker of risk for colorectal neoplasia. *Dig Dis Sci* 1992; 37: 1718-24.
23. Hietala OA, Yum KY, Pilon J et al. Properties of ornithine decarboxylase in human colorectal adenocarcinomas. *Cancer Res* 1990; 50: 2088-94.
24. Patchett SE, Alstead EM, Butruk L et al. Ornithine decarboxylase as a marker for premalignancy in the stomach. *Gut* 1995; 37: 13-6.

Paper received: 25 March 2003

Accepted: 19 May 2003