

## Tumor thickness is strongly related to the presence of clinically silent metastases in the sentinel node of skin melanoma patients

Dariusz Nejc, Janusz Piekarski, Arkadiusz Jeziorski

*Background.* Introduction of sentinel node biopsy into clinical practice has allowed for the detection of subclinical phase metastases in regional lymph nodes.

*Aim.* Determination of clinical and pathologic features which predict the presence of metastases in sentinel node of skin melanoma patients.

*Material and methods.* Between December 1<sup>st</sup> 1999 and June 30<sup>th</sup> 2000 74 patients with skin melanoma were prospectively enrolled into the study. Eligibility criteria were: excised primary tumor, no signs and symptoms of regional and/or distant metastases. All patients underwent sentinel node biopsy: preoperative lymphoscintigraphy, intraoperative detection of gamma radiation and intraoperative staining. The relationship between the presence of metastases in the sentinel node and pathoclinical features of patient and tumor was assessed.

*Results.* The presence of metastases in sentinel nodes was directly related to primary tumor thickness ( $p < 0.05$ ;  $p_{\text{trend}} < 0.05$ ) and to the depth of skin infiltration within primary tumor ( $p < 0.05$ ;  $p_{\text{trend}} < 0.05$ ). Metastases in the sentinel nodes occurred three times more often in patients with ulcerated primary tumor, than in those without ulceration. Metastases in the sentinel node were most frequently found in patients in whom the primary tumor was located close to the median line of trunk. There was no statistically significant relationship between the age, sex, skin complexion, diameter of primary tumor, type of tumor growth and presence of metastases in the sentinel node ( $p > 0.05$ ).

*Conclusions.* Tumor thickness, depth of skin infiltration within primary tumor, ulceration of primary tumor and location of primary tumor close to the anterior or posterior median line of the trunk are related to the presence of metastases in the sentinel node in their asymptomatic phase.

### Grubość guza jest silnie związana z występowaniem bezobjawowych przerzutów w węzle wartowniczym u chorych na czerniaka skóry

*Wprowadzenie.* Wprowadzenie biopsji węzła wartowniczego u chorych na czerniaka skóry pozwala na wykrywanie przerzutów do węzłów chłonnych w fazie przedklinicznej.

*Cel.* Określenie, które czynniki kliniczno-patologiczne mają wpływ na występowanie przerzutów w węzle wartowniczym u chorych na czerniaka skóry.

*Materiał i metody.* Od 1 grudnia 1999 r. do 30 czerwca 2000 r. do badania zakwalifikowano prospektywnie 74 chorych na czerniaka skóry. Kryteria włączenia obejmowały: przebyty zabieg usunięcia guza pierwotnego, brak objawów klinicznych przerzutów do węzłów chłonnych i/lub przerzutów odległych. U wszystkich badanych chorych wykonano biopsję węzła wartowniczego z zastosowaniem limfoscyntygrafii przedoperacyjnej, śródoperacyjnej detekcji promieniowania gamma oraz śródoperacyjnego wybarwiania dróg chłonnych. Oceniano związek między poszczególnymi cechami kliniczno-patologicznymi a występowaniem przerzutów w węzle wartowniczym.

*Wyniki.* Stwierdzono wprost proporcjonalną zależność pomiędzy grubością guza pierwotnego ( $p = 0,003$ ,  $p_{\text{trend}} = 0,035$ ) oraz głębokością nacieku skóry ( $p = 0,018$ ,  $p_{\text{trend}} = 0,024$ ), a występowaniem przerzutów w węzle wartowniczym. Przerzuty do węzła wartowniczego stwierdzono trzykrotnie częściej w grupie chorych, u których guz pierwotny był owrzodziały, niż u chorych bez obecności owrzodzenia ( $p = 0,03$ ). Przerzuty czerniaka do węzła wartowniczego stwierdzono najczęściej (46,1%) w grupie chorych, u których ognisko pierwotne znajdowało się na skórze tułowia, w okolicy linii pośrodkowej ciała ( $p = 0,018$ ). Nie zaobserwowano istotnej statystycznie zależności pomiędzy wiekiem, płcią, typem urody badanych, średnicą, typem wzrostu guza pierwotnego, a występowaniem przerzutów w węzle wartowniczym ( $p > 0,05$ ).

*Wniosek. Czynniki związane z występowaniem przerzutów w węzle wartowniczym są: grubość guza, głębokość naciekania skóry, owrzodzenie guza pierwotnego oraz umiejscowienie guza pierwotnego w pobliżu przedniej lub tylnej linii środkowej ciała.*

**Key words:** sentinel node biopsy, skin melanoma

**Słowa kluczowe:** biopsja węzła wartowniczego, czerniak skóry

## Introduction

Prognosis of patients with skin melanoma depends on the stage of the disease, as well as on many other clinical and pathological factors, such as: type of tumor growth and presence of ulceration in primary tumor, location of primary tumor and sex of patient [1-3]. The presence of metastases in regional lymph nodes is a major prognostic factor [4, 5]. Fortunately, in 80% – 90% of skin melanoma patients, regional lymph nodes are not palpable at the time of primary diagnosis [6, 7]. Classic diagnostic tools such as physical examination, ultrasound, fine needle biopsy or guided fine needle biopsy allow for the detection of metastases in regional lymph nodes in their symptomatic phase. Introduction of sentinel node biopsy into clinical practice has enabled the detection of metastases in regional lymph nodes in their subclinical phase [8-10].

It is interesting to discern which clinical and pathological factors are connected with the presence of clinically silent melanoma metastases in regional lymph nodes. The results of many authors indicate that the main predictors are: tumor thickness, depth of skin infiltration, presence of ulceration of primary tumor and location of primary tumor close to the anterior or posterior median line [10-19]. As the problem has never been tested in our setting, we have decided to investigate which factors predict the presence of clinically silent metastases of skin melanoma in regional lymph nodes in our patients.

## Objective

Determination of clinical and pathologic features which predict the presence of metastases in sentinel node of skin melanoma patients.

## Material and methods

### Patients

Between December 1st 1999 and June 30<sup>th</sup> 2000, 74 patients of the Clinical Department of Surgical Oncology, Medical University of Łódź who presented with skin melanoma were prospectively enrolled into the study. Eligibility criteria were: removed primary tumor, no signs and symptoms of regional and/or distant metastases. All patients underwent sentinel node biopsy: preoperative lymphoscintigraphy, intraoperative detection of gamma radiation and intraoperative staining. The lymph node showing the highest radioactivity and/or most intensive violet staining was considered to be the sentinel node. Such node was removed and the operative wound was closed. The removed sentinel node, or nodes, were examined histopathologically for the presence of metastases. Routine hematoxylin and eosin staining, as well as immunohistochemical staining with HMB-45, were performed in each case.

## Methods

The results of physical examination and case history, as well as pathological examination of tumor and sentinel node, were recorded for each patient. The relationship between the presence of metastases in the sentinel node and the recorded pathoclinical features was assessed. The analysis involved age, sex, skin complexion, tumor diameter, presence of ulceration in tumor, location of tumor, type of tumor growth, depth of infiltration and tumor thickness.

## Statistical analysis

The statistical relationship between the presence of metastases in the sentinel nodes and the recorded pathoclinical features was calculated using Fisher's exact test and linear regression model. The correlation was considered significant at  $p < 0.05$ . All analyses were performed with STATA 6.0 software.

## Results

### Clinical features of patients

The median age of patients was 56.5 years (range: 25-87 years; mean – 56.7 years). There were 38 women (51.4%) and 36 men (48.6%) in the studied group. The majority of patients were of pale skin complexion with blond hair ( $n=37$ ; 50%) or red hair ( $n=11$ ; 14.9%). Dark skin complexion and dark hair patients constituted 35.1% ( $n=26$ ).

### Clinical features of primary tumor

The median diameter of primary tumor was 1.5 cm (range: 0.5-4.2 cm; mean – 1.5 cm). Ulceration of primary tumor was present in 23 cases (31.1%).

In the majority of patients ( $n=42$ ; 56.8%) the tumor was located on the skin of trunk. In 15 cases the tumor was located close to the anterior (between midclavicular lines) or posterior (between scapular lines) median line. The remaining tumors were located on the lower extremities in 19 patients (25.7%), on the upper extremities in 10 patients (13.5%) and on the head and neck in 3 patients (4%).

Nodular type of primary tumor was diagnosed in 49 patients (66.2%). Superficial spreading melanoma was diagnosed in 19 patients (25.7%), lentigo maligna melanoma in 4 patients (5.4%) and acral lentiginous melanoma in 2 patients (2.7%).

### Pathologic features of primary tumor

The median tumor thickness was 2 mm (range, 0.5-20 mm; mean, 3.6 mm). The stage of primary tumor according to the Clark and Breslow scales is presented in Table I.

**Table I. Stage of primary tumor according to Clark and Breslow scale**

Stage of primary tumor	Clark		Breslow	
	N	%	N	%
I	0	0	4	5.4
II	10	13.5	25	33.8
III	36	48.6	25	33.8
IV	21	28.4	20	27
V	7	9.5	Not applicable	
Total	74	100	74	100

### Metastases in sentinel node

The sentinel node was identified in 71 patients. Metastases in sentinel nodes were found in 12 of these patients (12/71; 16.9%).

### Relationship between pathoclinical features and presence of metastases in sentinel node

There was no statistically significant relationship between the age, sex, skin complexion, diameter of primary tumor and presence of metastases in the sentinel node ( $p > 0.05$ ).

Metastases in the sentinel node occurred three times more often in patients with ulcerated primary tumor, than in those without ulceration. The difference was statistically significant ( $p < 0.05$ ) [Table II].

**Table II. Relationship between the presence of metastases in sentinel node and ulceration of primary tumor in 71 patients in whom sentinel node was identified**

Ulceration of primary tumor	N	Metastases in primary tumor	
		n	%
no	50	5	10.0
yes	21	7	33.3
P		0.033	

Metastases in the sentinel node were found most often (46.1%) in patients in whom the primary tumor was located close to the median line of trunk. In patients with the primary tumor located on the head and neck metastases in the sentinel node were found in 33.3% of cases. Significantly less often metastases were present in

the sentinel node in patients with primary tumor located on extremities ( $p < 0.05$ ) [Table III].

**Table III. Relationship between the presence of metastases in sentinel node and location of primary tumor in 71 patients in whom sentinel node was identified**

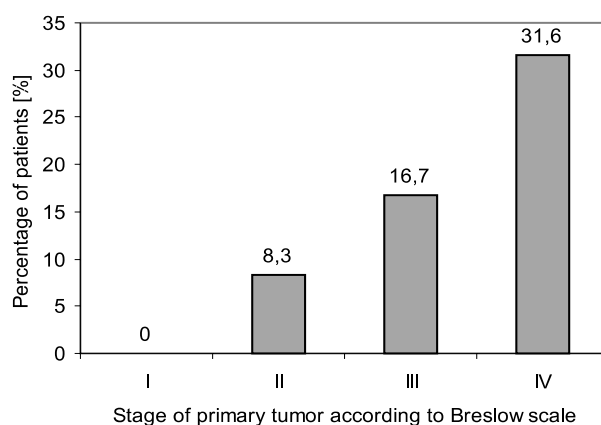
Location of primary tumor	N	Metastases in sentinel node	
		n	%
Head and neck	3	1	33.3
Lower extremity	19	3	15.8
Upper extremity	9	0	0.0
Trunk	27	2	7.4
Trunk – close to median line of body	13	6	46.1
P		0.018	

There was no statistically significant correlation between the type of growth of primary tumor and presence of metastases in the sentinel node ( $p > 0.05$ ).

The presence of metastases in the sentinel node was directly related to primary tumor thickness ( $p < 0.05$ ;  $p_{\text{trend}} < 0.05$ ) [Table IV, Figure 1].

**Table IV. Relationship between the presence of metastases in sentinel node and thickness of primary tumor in 71 patients in whom sentinel node was identified**

Breslow [°]	Thickness [mm]	N	Metastases in sentinel node	
			n	%
I	<0.75	4	0	0.0
II	0.75-1.5	24	2	8.3
III	1.51-4.0	24	4	16.7
IV	>4.0	19	6	31.6
P			0.003	

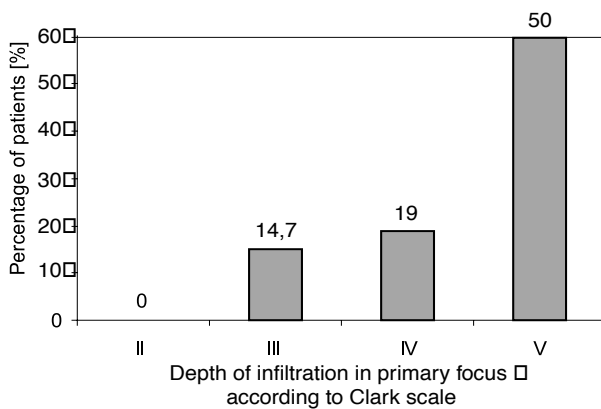


**Figure 1. Relationship between the presence of metastases in sentinel node and tumor thickness classified according to Breslow scale in 71 patients in whom sentinel node was identified**

The presence of metastases in the sentinel node was also directly related to the depth of skin infiltration in primary tumor ( $p < 0.05$ ;  $p_{\text{trend}} < 0.05$ ) [Table V, Figure 2].

**Table V. Relationship between the presence of metastases in sentinel node and depth of primary tumor classified according to Clark scale in 71 patients in whom sentinel node was identified**

Clark [°]	N	Metastases in sentinel node	
		n	%
II	10	0	0.0
III	34	5	14.7
IV	21	4	19.0
V	6	3	50.0
P		0.018	



**Figure 2.** Relationship between the presence of metastases in sentinel node and depth of infiltration in primary tumor according to Clark scale in 71 patients in whom sentinel node was identified

## Discussion

Tumor thickness, depth of skin infiltration in primary tumor, ulceration of primary tumor and location of primary tumor close to the anterior or posterior median line of the trunk were related to the presence of metastases in the sentinel node. The strongest relationship was found for tumor thickness classified according to the Breslow scale ( $p=0.003$ ). The relationship for the depth of skin infiltration classified according to the Clark scale ( $p=0.018$ ) and for tumor location ( $p=0.018$ ) was weaker. The weakest, but still significant, relationship was found for the presence of ulceration of the primary tumor ( $p<0.033$ ). No statistically significant relationship was found for the remaining clinical and pathological features ( $p>0.05$ ).

Similar results were presented by other authors, who found strong relationship between the stage of primary tumor and presence of metastases in sentinel node [11-19]. Literature reports also indicate that tumor thickness, depth of skin infiltration in primary tumor, ulceration of primary tumor and location of primary tumor close to the anterior or posterior median line of the trunk are related to the presence of metastases in sentinel node [10, 13, 14, 18, 19].

## Conclusions

Tumor thickness, depth of skin infiltration in primary tumor, ulceration of primary tumor and location of primary

tumor close to the anterior or posterior median line of the trunk are related to the presence of metastases in the sentinel node in their asymptomatic phase.

### Dariusz Nejc MD, PhD

Department of Surgical Oncology  
Medical University of Łódź  
ul. Paderewskiego 4  
93-509 Łódź

## References

- Chmielowska E. Zależność klinicznego przebiegu czerniaka złośliwego skóry od jego cech populacyjnych, lokalizacji, stopnia zaawansowania oraz cech histopatologicznych. *Pat Pol* 1988; 39: 83-93.
- Skowronek J, Mackiewicz A, Żygulska-Mach H. Czerniak złośliwy. *Termedia Wyd Med* Poznań 1998.
- Garbe C, Buttner P, Bertz J et al. Primary Cutaneous Melanoma; Identification of Prognostic Groups and Estimation of Individual Prognosis for 5093 Patients. *Cancer* 1995; 75: 2484-91.
- Thompson JF, McCarthy WH, Bosch CMJ et al. The lymph node status as an indicator of presence of metastatic melanoma in regional lymph nodes. *Melanoma Res* 1995; 5: 255-60.
- Kulakowski A, Madej G, Pieńkowski T. Distribution of lymph node metastases in the malignant melanoma of the trunk. *Oncology* 1984; 41: 242-4.
- Balch CM, Soong SJ, Shaw H et al. Changing trends in clinical and pathological features of melanoma. *Cutaneous melanoma*, 2<sup>nd</sup> ed. Philadelphia: Lippincott; 1992, p. 40-45.
- Kanzler MH, Mraz-Gernhard S. Treatment of primary cutaneous melanoma. *JAMA* 2001; 285: 1819-21.
- Morton DL, Wen DR, Wong JH. Technical details of intraoperative lymphatic mapping for early stage melanoma. *Arch Surg* 1992; 127: 392-9.
- Jastrzębski T, Kopacz A, Świerblewski M et al. Metoda znakowania węzła "wartownika": wskazanie do selektywnego wycięcia węzłów chłonnych w I° zaawansowania klinicznego czerniaka złośliwego skóry. *Pol Przegl Chir* 1996; 63: 267-73.
- Berner A, Nejc D, Berkan M. Czy biopsja węzła wartowniczego rokuje postęp w leczeniu chorych na czerniaka skóry? *Onkol Pol* 2000; 3: 1-5.
- Wagner JD, Corbett L, Park HM et al. Sentinel lymph node biopsy for melanoma: experience with 234 consecutive procedures. *Plast Reconstr Surg* 2000; 105: 1956-66.
- Bostick P, Essner R, Glass E et al. Comparison of blue dye and probe - assisted intraoperative lymphatic mapping in melanoma to identify sentinel nodes in 100 lymphatic basins. *Arch Surg* 1999; 134: 43-9.
- Joseph E, Brobeil A, Glass F et al. Results of complete lymph node dissection in 83 melanoma patients with positive SLN. *Ann Surg Oncol* 1998; 5: 119-25.
- Ross MI, Reintgen DS. Role of lymphatic mapping and sentinel node biopsy in the detection of melanoma nodal metastases. *Eur J Cancer* 1998; 34, Suppl. 3: 7-11.
- Gershenwald JE, Tseng C, Thompson W et al. Improved sentinel lymph node localization in patients with primary melanoma with the use of radio-labeled colloid. *Surgery* 1998; 8: 203-10.
- Ruka W, Nowecki Z, Żurawski Z et al. Limfocentygrafia śródoperacyjna w biopsji węzła chłonnego wartowniczego u chorych na czerniaka skóry. *I Zjazd i XV Konferencja Naukowo-Szkoleniowa Polskiego Towarzystwa Chirurgii Onkologicznej*, Poznań 1998, abstract 30.
- Gershenwald JE, Thompson W, Mansfield PF et al. Multi institutional melanoma lymphatic mapping experience: the prognostic value of sentinel lymph node status in 612 stage I or II melanoma patients. *J Clin Oncol* 1999; 17: 976-83.
- Ruka W, Nowecki Z, Tomkiewicz E. Postępowanie z węzłami chłonnymi. *I Zjazd i XV Konferencja Naukowo-Szkoleniowa Polskiego Towarzystwa Chirurgii Onkologicznej*, Poznań 1998, abstract 29-30.
- Lens MB, Dawes M, Newton-Bishop JA et al. Tumour thickness as a predictor of occult lymph node metastases in patients with stage I and II melanoma undergoing sentinel lymph node biopsy. *Br J Surg* 2002; 89: 1223-7.

Paper received: 11 October 2002

Accepted: 3 December 2002