

Original contributions

Magnetic resonance imaging-based radiation therapy treatment planning

Jürgen R. J. Schultze, Frank A. Siebert, Bernhard N. Kimmig

Introduction. The aim of this paper is to demonstrate the advantages of MRI over CT in the field of radiotherapy treatment planning: particularly for tumour delineation in coronal, lateral and sagittal planes.

Methods and material. Technical requirements necessary are a (1) conventional therapy simulator capable of producing digital image data, and (2) an MRI system where the digital image data can be used within a data network system. Image data from the simulator fluoroscopy mode and the MRI data are transferred to a Macintosh PC system. Data is transferred via Ethernet to the treatment planning system. Image enhancement is performed. 240 patients have been planned using the technique.

Results. Results in terms of spatial deviations are described for target volumes in liver, spleen, and pelvic regions and also for brain tumours. Results are shown for two patients (1) with Hodgkin's disease, and (2) with a pinealis gland tumour.

Conclusions. The technique is an important supplement to existing technologies. It is inexpensive and cost-effective and is an advance on conventional simulation techniques.

Planowanie radioterapii z zastosowaniem techniki rezonansu magnetycznego

Wstęp. Celem pracy jest wykazanie zalet rezonansu magnetycznego w stosunku do tomografii komputerowej w planowaniu leczenia radioterapią, w szczególności w zakresie oznaczenia granic guza w poszczególnych płaszczyznach.

Materiał i metody. Niezbędny sprzęt obejmuje konwencjonalny sumulator zdolny do przedstawienia danych w postaci cyfrowej oraz aparat do magnetycznego rezonansu jądrowego, która umożliwi przetwarzanie danych cyfrowych w obrębie sieci. Dane fluoroskopowe uzyskane z symulatora i dane z magnetycznego rezonansu jądrowego są opracowywane za pomocą systemów Macintosh, a następnie przekazywane za pomocą Ethernet do układu planującego leczenie, gdzie opracowuje się obraz. Jak dotychczas metodę tę zastosowano w leczeniu 240 chorych.

Wyniki. Wyniki zostały opisane jako dawki na obszary referencyjne w obrębie wątroby, śledziony i miednicy, jak również na obszar mózgu. Zostały one przedstawione dla dwóch pacjentów – jednego z chorobą Hodgkina i jednego z guzem szyszynki.

Wnioski. Technika ta stanowi istotne uzupełnienie stosowanych obecnie metod. Jest to metoda mało kosztowna i efektywna, stanowiąca postęp w stosunku do konwencjonalnych technik symulacji.

Key words: magnetic resonance imaging, radiation therapy, computer treatment planning

Słowa kluczowe: rezonans magnetyczny, radioterapia, komputerowe planowanie leczenia

Introduction

Computed tomography (CT) imaging has been well established within the radiotherapy treatment planning process for several years. Magnetic resonance imaging (MRI) is not currently used as extensively as CT but is continuously gaining in importance [1-6]. This advance in the use of MRI is due to the advantage over CT imaging of better tumour delineation in the different planes of interest required for treatment planning: coronal, lateral and sagittal.

Early proposals for MRI clinical applications in radiation therapy planning have been published by several groups during the period 1985-2002 [6-23]. However, the applications concentrated mainly on imaging of the brain and CNS, with a recent application for infra-diaphragmatic lymph nodes [21]. Extension to regions other than the brain is not very common and this is possibly due to the absence of computer software and application technique for integrating MRI into the overall computer treatment planning process.

This paper describes the Kiel University method of integrating MRI with simulator fluoroscopic images using modern computer technology, in order to provide improved definition of the target volume.

Methods and material

Our main imaging tool for tumour staging and for tumour volume definition in treatment planning is CT with secondary input using fluoroscopy and radiography. For example, in the case of infra-diaphragmatic lymph nodes for patients with Hodgkin's lymphoma, we perform urography with radiographs to assist in defining the field margins required to cover the target volume. The topographic orientation of the fields and target volume are defined using CT and ultrasound imaging as well as the results of the urogram. These images enable construction of individual shielding within a treatment field for each patient. Then, the MRI is performed.

The *primary* technical requirement for MRI based treatment planning is a conventional therapy simulator capable of producing digital image data. Such image data can be obtained using radiographic film when can then be digitised using a film scanner and the data transferred to the treatment planning system *via* a personal computer [PC].

The *secondary* technical requirement is the availability of an MRI system whose digital image data can be used within a data network system. An alternative to this requirement is to store the data on a removable hard disc, for example a SyQuest 44 MB cartridge.

At Kiel, the image data from the simulator fluoroscopy mode and the MRI data are transferred on a network to an Apple Macintosh Performa PC system with a 5260 MB hard disc and 120 MB RAM. The treatment planning procedures involving the images can then take place.

After defining the target volume, conventional simulation is performed and the treatment fields are documented on film. MRI is then performed in the required plane(s) as defined in the pre-planning process and T1 weighted (415/25) spin echo (SE) sequences are obtained with the optional use of Gadolinium-DTPA. Digitised simulator fluoroscopic and MRI data are transferred on line *via* Ethernet to the computer treatment planning system.

The images are enhanced using our Kiel developed Gyroplan software [22,24] and for example the fluoroscopic image is edge-traced. In the MRI the tumour, critical organs or a pre-planned target volume are marked with a cursor. Then the fluoroscopic and MR images are merged and superimposed, being first oriented using anatomical landmarks. These landmarks are usually bony structures such as the skull for brain tumours, spine and ribs for thoracic tumours and spine and hips for pelvic tumours. Usually an MRI plane we select contains the maximum extension of the tumour. At this stage we correct the MRI data set by an appropriate scaling factor: otherwise merging with the fluoroscopic image would not be correctly achieved.

The result is an integrated display of bony structures from fluoroscopy and of soft tissue structures from MRI. This enables an improved assessment of field margins and also permits, if necessary, reconsideration of the radiation therapy technique. These results are documented *via* a video link which has connected a laser printer and a multi-format camera in order to obtain hardcopy outputs: see Figure 1.

Technically introduced image distortions have been studied [25-27]. Phantom measurements revealed that the MR image distortion due to magnetic field lines and a possible divergence fault are negligible in clinical practice. We use a six minute standard MRI sequence which is optimal considering a breathing sequence. We have also used phantom measurements to compare the positional accuracy of the fluoroscopic and MR images and found a maximum deviation of only 2 mm at distances greater than 20 cm from the isocentre.

We have planned 240 consecutive patients using the above described technique for the following treatment sites for primary or metastatic disease: 56 abdomen and spleen, 54 pelvis, 37 thoracic, 37 brain, 36 head and neck and 20 liver.

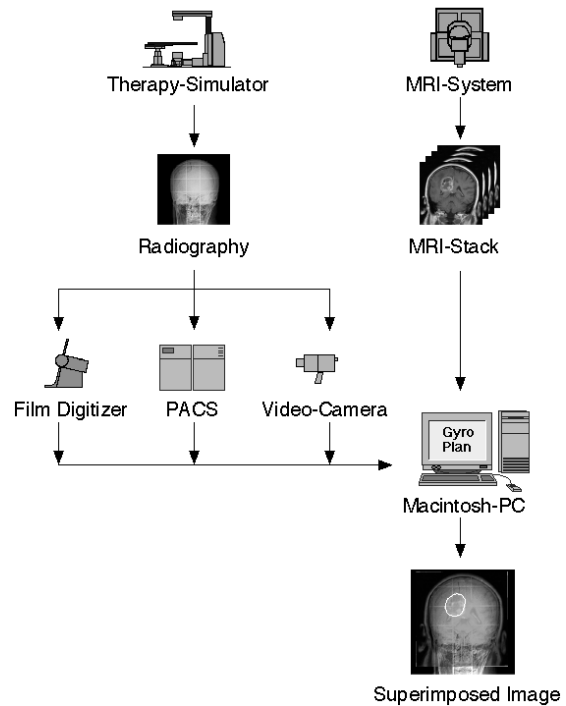


Figure 1. Flow chart for the primary digital framework of the method

Results

Our study showed that major deviations occurred in the target volumes for *liver and spleen* tumours. Previously for a liver target volume ultrasound imaging was performed and this for example was found to be inadequate. In 13/20 patients the caudal liver margin was inaccurate by 3-6 cm. Due to this inaccuracy, without MRI, significant portions of the small bowel would have been irradiated due to its proximity to the caudal and medial liver margins.

For the spleen similar problems were observed and an accurate target volume was obtained using ultrasound in only 21/56 patients. In 35/56 patients errors of 1.0-4.5 cm were noted. In particular, the size of the splenic medial upper volume was rarely defined correctly and the caudal volume was often defined using ultrasound imaging as too large and therefore caused unnecessary overlap with the left kidney: see Figure 2.

In the *pelvic region* for 22/54 patients the deviations were 2-4 cm between CT and MR imaging methods but

Table I. Patients requiring target volume modifications after assessment using MRI

| Tumour site | No. patients | No. requiring a modification |
|------------------|--------------|------------------------------|
| Brain | 37 | 7 |
| Head & neck | 36 | 5 |
| Thorax | 37 | 4 |
| Liver | 20 | 13 |
| Abdomen & spleen | 56 | 35 |
| Pelvis | 54 | 22 |
| All sites | 240 | 86 |

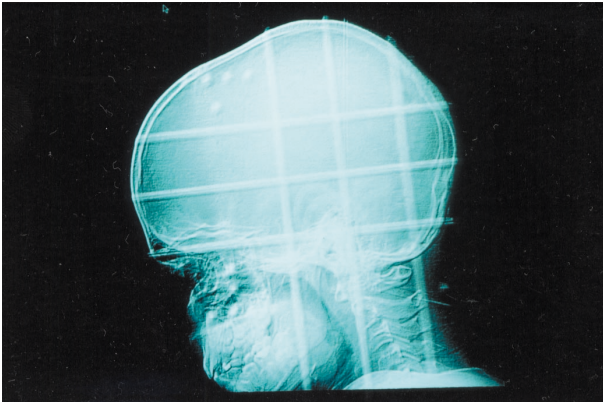


Figure 2a

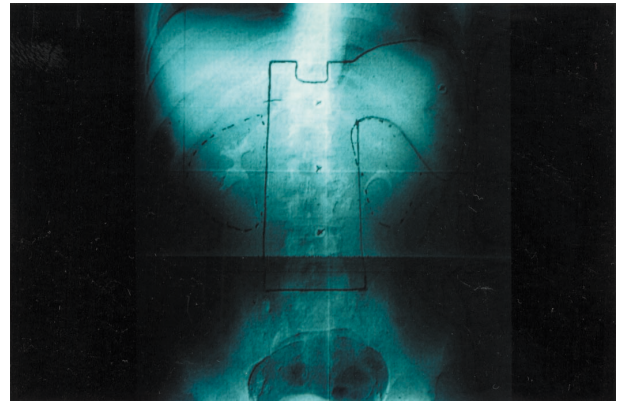


Figure 3a

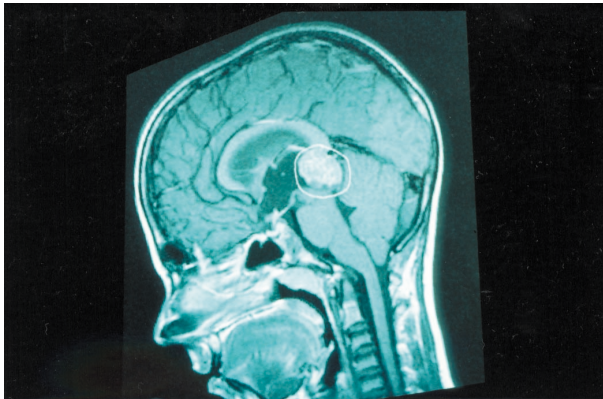


Figure 2b

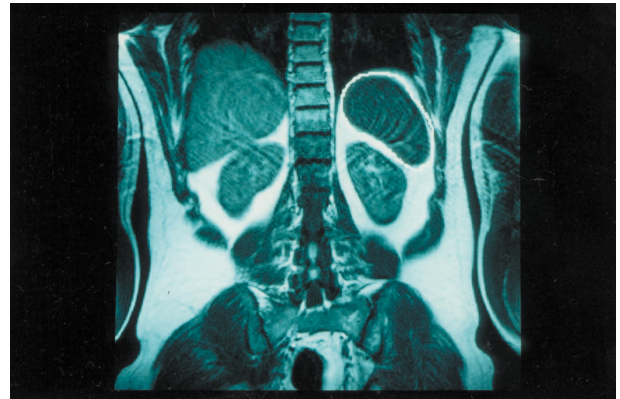


Figure 3b

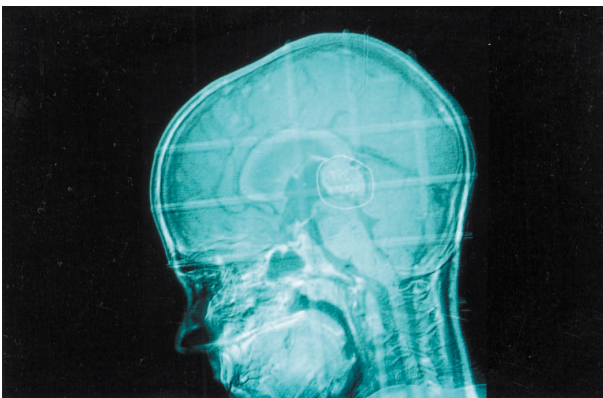


Figure 2c

Figure 2. 35-year old male with Hodgkin's disease. [a] Simulation of AP/PA opposing fields and with the use of contrast media. [b] Coronal spin echo T1-weighted MR image with the spleen delineated [by a white jagged outline]. [c] Superimposition of both images showing the soft tissue and the spleen fully covered by the radiation fields. The left kidney is also shown to be shielded.

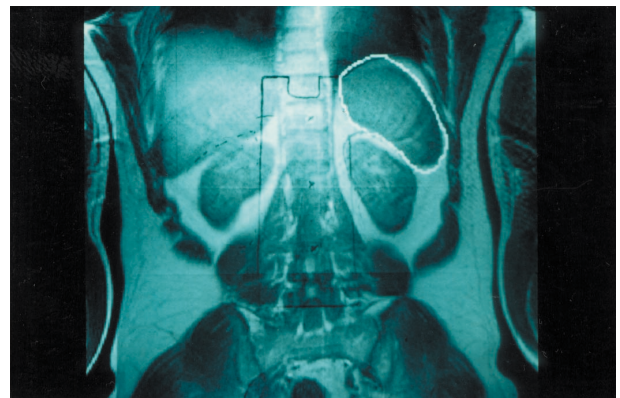


Figure 3c

Figure 3. Imaging of pineal gland tumour in an 11-year old boy. [a] Simulator image with lateral opposing fields. [b] Sagittal spin echo T1-weighted MR image with the tumour volume delineated. [c] Superimposition of both images adapted in terms of image size and position. Note that the preplanned radiation beam fully covers the tumour volume.

this was in part due to organ motion in this area. However, when compared to urogram results those with MRI differed by only 1 cm although the quality of the image was improved when using MRI.

Our new planning technique involving the use of MRI was also an advantage for treating *brain* tumours following resection of the primary lesion. The sagittal MR images acquired prior to neurosurgery were superim-

posed on the lateral brain simulator fluoroscopic images in order to optimally view the primary tumour site. Differences between conventionally simulated teletherapy beams compared to those defined using MRI could be as large as 2.5 cm. Thus although the target volumes were never underdosed, it led to larger than necessary boost doses being applied. With MRI the target volume could be reduced: see Figure 3.

Table I gives the frequency of target volume modifications required for our series of 240 patients and it is seen that overall, there is a significantly large figure of 36% [86/240] who required modifications.

Discussion

Using MR imaging-based radiotherapy treatment planning by digital image superimposition a significant improvement can be made in the accuracy of definition of target volumes: particularly for liver and spleen volumes. Individual shielding of critical volumes in the liver and pelvic regions can also be improved using this technique.

Our study has also shown that target volumes can be reduced, sometimes remarkably so, and this obviously relates to the possibility of short-term and long-term side effects to organs such as the small bowel and kidneys.

Since only a PC and digitised data are necessary this is cost-effective treatment planning technology. However, special software such as Gyroplan [24] is desirable to maximise image manipulation possibilities.

Conclusions

The technique using MRI which has been developed at Kiel University is an important supplement to existing methodologies [28] and permits the radiation oncologist to use MRI to its best advantage [29]. Since the technology only requires a data network between simulator, MR scanner and PC for quick and easy application of the method, it can be performed in many existing centres. It is hoped that this advance in treatment planning will lead to improved tumour control and increased survival.

Dr Jürgen R. J. Schultze

Department of Radiation Therapy [Radiooncology]
Christian-Albrechts-University
Arnold Heller Strasse 9
Kiel 24105
Germany
e-mail: schultze@onco.uni-kiel.de

References

- Breit A. *Magnetic resonance in oncology*. Berlin: Springer; 1990.
- Hosten N, Wust P, Beier J et al. MRI assisted specification and localisation of target volumes. *Strahlenther Onkol* 1998; 174: Suppl II: 13-18.
- Khoo VS, Dearnley DP, Finnegan DJ et al. Magnetic resonance imaging considerations and application in radiotherapy treatment planning. *Radiation Oncol* 1997; 42: 1-15.
- Kovacs G, Pötter R. Magnetic resonance imaging in radiotherapy. *Curr Oncol* 1994; 1: 163-168.
- Sailer SL, Rosenman JG, Soltys M et al. Improving treatment planning accuracy through multimodality imaging. *Int J Radiat Oncol Biol Phys* 1996; 35: 117-124.
- van den Berge DL, Ridder MD, Storme GA. Imaging in radiotherapy. *Eur J Radiol* 2000; 36: 41-48.
- Breit A. *Tumour response monitoring and treatment planning*. Berlin: Springer; 1992.
- Flentje M, Zierhut D, Schraub P et al. Integration of coronal magnetic resonance imaging into radiation treatment planning of mediastinal tumours. *Strahlenther Onkol* 1993; 169: 351-357.
- Glatstein E, Lichter AS, Fraass BA et al. The imaging revolution and radiation oncology: use of CT, ultrasound and NMR for localization, treatment planning and treatment delivery. *Int J Radiat Oncol Biol Phys* 1985; 11: 299-314.
- Gremmel H. NMR diagnosis in radiotherapy. *Strahlenther Onkol* 1985; 161: 506-510.
- Shuman WP, Griffin BR, Haynour DR et al. MR imaging in radiation therapy planning. *Radiology* 1985; 156: 143-147.
- Yanke BR, Ten Haken RK, Aisen A et al. Design of MRI scan protocols for use in 3D CT-based treatment planning. *Med Dosim* 1991; 16: 205-211.
- Houdek PV, Howard JL, Quencer RM et al. MR characterization of brain and brain tumor response to radiotherapy. *Int J Radiat Oncol Biol Phys* 1988; 15: 213-218.
- Judnick JW, Kessler ML, Fleming T et al. Radiotherapy technique integrates MRI into CT. *Radiol Technol* 1992; 64: 82-89.
- Kessler ML, Pitluck S, Petti P et al. Integration of multimodality imaging data for radiotherapy treatment planning. *Int J Radiat Oncol Biol Phys* 1991; 21: 1653-1667.
- Köster A, Kimmig B, Müller-Schimpfle M et al. MR tomography and MR angiography for treatment planning in subdiaphragmatic radiation therapy. *Strahlenther Onkol* 1992; 168: 230-236.
- Müller-Schimpfle M, Layer G, Köster A et al. MRI and MRA in treatment planning of subdiaphragmatic radiation therapy. *J Comput Assist Tomog* 1992; 16: 110-119.
- Pötter R, Heil B, Schneider L et al. Sagittal and coronal planes from MRI for treatment planning in tumours of brain and head & neck: MRI assisted simulation. *Radiation Oncol* 1992; 23: 127-130.
- Thornton AF, Sandler HM, Ten Haken R et al. The clinical utility of magnetic resonance imaging in 3D treatment planning of brain neoplasms. *Int J Radiat Oncol Biol Phys* 1992; 24: 767-775.
- Beavis AW, Gibbs P, Dealey RA et al. Radiotherapy treatment planning of brain tumours using MRI alone. *Br J Radiol* 1998; 71: 544-548.
- Nevinny-Stickel M, Ennemoser S, Bangerl I et al. Comparison of standard and individually planned infradiaphragmatic field in irradiation of retroperitoneal and pelvic lymph nodes. *Strahlenther Onkol* 1998; 174: 341-344.
- Schultze J, Siebert FA, Kimmig B. Impact of computer assistance and MR imaging in radiation therapy treatment planning of cerebral malignancies. In: Lemke HU, Vannier MW, Inamura K, eds. *Computer assisted radiology and surgery*. Amsterdam: Elsevier, 1997, 394-399.
- Suit H. The Gray lecture 2001: coming technical advances in radiation oncology. *Int J Radiat Oncol Biol Phys* 2002; 53: 798-809.
- Siebert FA, Schultze J, Kohr P et al. GYROPLAN-Bildüberlagerung als Basis gezielter Tumortherapie. *Z Med Phys* 1997; 7: 255-261.
- Fraass BA, McShan DL, Diaz RF et al. Integration of magnetic resonance imaging into radiation therapy treatment planning. I. Technical considerations. *Int J Radiat Oncol Biol Phys* 1987; 13: 1897-1908.
- Schad L, Lotts S, Schmitt F et al. Correction of spatial distortion in MR imaging: a prerequisite for accurate stereotaxy. *J Comput Assist Tomog* 1987; 11: 499-505.
- Schmitt F. Correction of geometrical distortions in MR images. In: Lemke HU, Rhodes ML, Jaffee CC et al, eds. *Computer assisted radiology*. Berlin: Springer, 1985, 15-24.
- Dempsey MS, Bosch WR, Low DA et al. Multimodality image registration quality assurance for conformal 3D treatment planning. *Int J Radiat Oncol Biol Phys* 2001; 51: 255-260.
- Krempien RC, Schubert K, Zierhut D et al. Open low-field magnetic resonance imaging in radiation therapy planning. *Int J Radiat Oncol Biol Phys* 2002; 53: 1350-1360.

Paper received: 7 November 2002

Accepted: 20 November 2002