

The use of anti-CD20 monoclonal antibody labeled with a radioisotope (Zevalin) in the treatment of recurrent follicular lymphoma – a case report

Tomasz Wróbel¹, Grzegorz Mazur¹, Diana Jędrzejuk², Monika Biedroń¹,
Roman Badowski³, Kazimierz Kulickowski¹

Indolent lymphomas are lymphoproliferative disorders with a relatively good prognosis and long-term natural history. The patients are treated with chemo-, radio- and immunotherapy. But it is impossible to achieve curability, except for the cases in early clinical stages. Radioimmunotherapy is composed of two different methods of treatment: immuno- and radiotherapy. It provides a new therapeutic approach in which monoclonal antibodies directed against tumor-specific antigens are used to target therapeutic radioisotopes to sites of disseminated disease. ⁹⁰Y-Ibritumomab tiuxetan is approved for the treatment of relapsed and refractory, follicular, low-grade NHL. The energy is deposited within 5 mm of the radiation source, which kills not only antibody-bound cells, but also neighbouring malignant cells. The aim of this paper was to describe a 50-year old woman with relapsed follicular lymphoma who was successfully treated with ⁹⁰Y-ibritumomab tiuxetan.

Zastosowanie przeciwciała monoklonalnego antyCD20 sprzężonego z radioizotopem w leczeniu nawrotowego chłoniaka grudkowego – opis przypadku

Chłoniaki o przebiegu powolnym należą do schorzeń limfoproliferacyjnych o stosunkowo dobrym rokowaniu i wieloletnim przebiegu naturalnym. Mimo znacznej podatności tych chłoniaków na chemio- i radioterapię, względnie długiego czasu przeżycia, dostępne obecnie metody nie pozwalają na trwałe wyleczenie z wyjątkiem przypadków we wczesnych stadiach zaawansowania klinicznego. Radioimmunoterapia jest nową metodą leczenia nowotworów układu chłonnego – przeciwciała monoklonalne sprzężone z radioaktywnym izotopem stanowią syntezę dwóch metod leczenia chłoniaków: immunoterapii i radioterapii.

Ibritumomab tiuxetan znakowany radioizotopem [⁹⁰Y] (Zevalin) jest stosowany w leczeniu dorosłych pacjentów z oporą na leczenie CD20⁺ postacią grudkowego B-komórkowego chłoniaka nieziarniczego lub pacjentów z nawrotem choroby po leczeniu rituximabem. Związek ten stanowi połączenie przeciwciała monoklonalnego z izotopem promieniotwórczym Itr 90. Emitowane promieniowanie β ma zasięg 5 mm, co pozwala na zniszczenie komórek CD20⁺ i sąsiednich, bez uszkodzenia otaczających guz tkanek prawidłowych. Praca jest opisem przypadku 50-letniej pacjentki z nawrotową postacią chłoniaka grudkowego, leczoną skutecznie ibritumomabem.

Key words: follicular lymphoma, radioimmunotherapy, ibritumomab tiuxetan

Słowa kluczowe: chłoniak grudkowy, radioimmunoterapia, ibritumomab tiuxetan

Introduction

Indolent non-Hodgkin's lymphomas (NHLs) are lymphoproliferative disorders associated with a relatively good prognosis and a natural course prolonged to many years. They usually affect elderly people and the diagnosis in 90% of cases is made in advanced clinical stage of the disease (III and IV according to Ann Arbor). Despite

the high susceptibility of this kind of lymphomas to chemotherapy and radiotherapy, as well as a relatively long survival time, with the exception for early stages of clinical progress, currently available methods do not result in permanent cure. A majority of patients develop successive, sometimes late relapses, progression of histological malignancy and increasing resistance to treatment. Follicular lymphoma (FL) is one of most commonly diagnosed indolent lymphoma and constitutes 22% of all NHLs occurring in the world [1]. Recent achievements in molecular biology contributed significantly to understanding the pathology of NHLs. Over the past few years monoclonal antibodies against antigens present on the surface of lymphoma cells, e.g. anti-CD20,

¹ Department of Haematology, Blood Neoplasms and Bone Marrow Transplantation

² Department of Endocrinology and Diabetology

³ Department of Radiology
Wrocław Medical University
Wrocław, Poland

(rituximab) have been widely used in the treatment of NHLs. Monoclonal antibodies have been used in the treatment of follicular lymphoma since late 1990's. Recently a number of trials have been undertaken to increase the effectiveness of monoclonal antibodies by combining them with radioisotopes.

^{90}Y -Ibritumomab tiuxetan (Zevalin) is used in the management of patients with a refractory or recurrent (following prior rituximab treatment) form of follicular lymphoma [2]. The product is a murine anti-CD20 monoclonal antibody (ibritumomab) linked via the linker-chelator tiuxetan to Yttrium 90 [3]. Yttrium 90 emits β radiation with the energy of 2.3 MeV, 5 mm path length and half-life of 2.7 days [4]. We present a case of relapsed FL in advanced clinical stage treated successfully with ibritumomab.

Case report

A 50-year-old female patient was diagnosed in March 2002 with CD20(+) B-cell follicular lymphoma in IV B clinical stage with generalized enlargement of peripheral and retroperitoneal lymph nodes, hepatomegaly (17.2 cm) and splenomegaly (23.3x10.5 cm), as well as bone marrow involvement (lymphoma cells constituted 46.2%). The patient received two courses of FC therapy (fludarabine with cyclophosphamide) and 6 courses of CHOP (cyclophosphamide, doxorubicin, vincristine, prednisone) combined with rituximab, which resulted in partial remission of the disease. In May 2004 she developed progression with splenomegaly (9x18x20 cm), enlargement of supra- and infraclavicular lymph nodes (the largest, 3x5 cm was observed on the right side, the node on the left side was 3x4 cm), cervical lymph node on the left side (1.2x2 cm), retroperitoneal periaortal lymph nodes (the largest, in the left renal hilus, was 1.5x2.5 cm), lymph nodes around the celiac trunk (the largest was

1x1.8 cm), iliac (the largest was on the left side, 2x4.5 cm) and inguinal lymph nodes (bilaterally, 2x3.5 cm) and associated B symptoms: fever and sweating. Laboratory results disclosed an active disease: ESR (50/-), CRP (15.0 mg/l). In May 2004, following rituximab pre-treatment, the patient was administered ^{90}Y ibritumab tiuxetan (Zevalin) in a reduced dose of 0.3 mCi/kg due to thrombocytopenia (the product was obtained by the courtesy of Schering AG). No early side effects were observed. On the 40th day after administration of the drug thrombocytopenia (4th degree according to WHO), as well as leukopenia and anaemia (3rd degree according to WHO), were observed. The patient required transfusion of 10 units of platelets and 8 units of red cells. Control MRI in September 2004 revealed a significant regression of involved lymph nodes: the cervical lymph node on the left side decreased to the diameter of 1 cm, the subclavicular lymph node on the right side decreased to 1.5x2.5 cm, the remaining lymph nodes in the chest returned to normal size or decreased to the diameter of less than 1 cm, the spleen decreased to the size of 7x3.5x4.5 cm, there were no enlarged lymph nodes in the abdomen and pelvis, the iliac and inguinal lymph nodes were not enlarged. ESR (37/-) and CRP (9.54 mg/l) decreased. The remaining biological parameters, as well as the blood count, were normal. Control ultrasound examination of the abdomen performed in November 2004 revealed splenomegaly of 17.8 cm and hepatomegaly of 14.7 cm. The remaining abdominal organs were normal. No enlarged lymph nodes were observed. The patient has been in partial remission for the past 8 months.

Discussion

Until this day the results of treatment of NHLs have not been satisfactory. Relapse or progression of the disease is observed after initial therapy in about 50% of cases of high-grade lymphomas and in about 80% of indolent lymphomas. Thus it seems that the effectiveness of both conventional, as well as high dose chemotherapy, has reached its limits. Further improvement in the treatment of lymphomas is possible only with the use of drugs with different mechanism of action than the typical cytotoxic drugs. Monoclonal antibodies are such a group of medicines. NHLs are a heterogenous group of lymphoid malignancies, however in the Northern hemisphere over 80% of lymphomas originate from B-cell lymphocytes. The CD20 antigen occurs in 95% of cases of B-cell lymphomas. This antigen is expressed on pre-B-cell lymphocytes and on mature B-cell lymphocytes. It is not found on haemopoietic system stem cells, B-cell system progenitor cells, plasma cells and cells of other, normal tissues. The CD20 antigen does not internalize after binding with an antibody, nor is it released from the cell surface and it does not circulate in plasma in a soluble form. This provides a rationale for the therapeutic use of anti-CD20 epitope antibodies. Anti-CD20 particle triggers the mechanisms of cellular lysis through antibody-

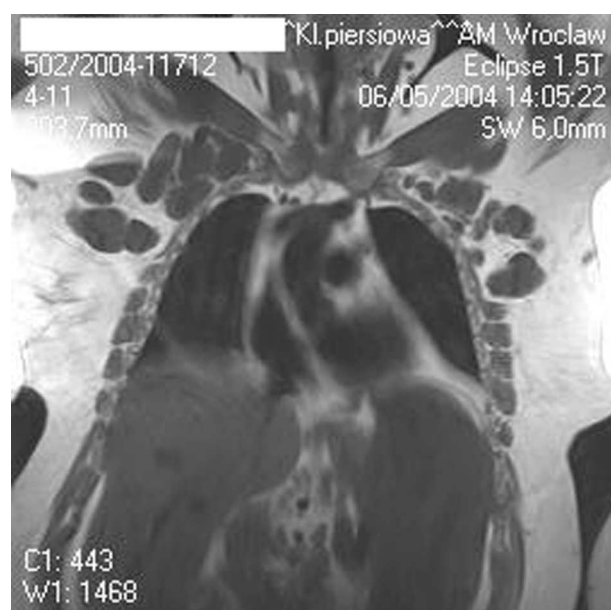


Figure 1. Enlarged lymph nodes in the CT scan of the chest before treatment

dependent cell cytotoxicity (ADCC) and complement dependent cytotoxicity (CDC). It also exerts a direct antiproliferative effect on malignant cells. Multicentered trials demonstrated from 40% to 60% of clinical responses to rituximab monotherapy in the treatment of recurrent and refractory lymphomas [5, 6]. The reasons of inadequate effectiveness of rituximab are believed to be: too low serum antibody levels, insufficient binding of the antibody to the target cells resulting from the lack or loss of antigen expression on the surface of lymphoma cells, poor access of the antibody to the tumour cells (especially in patients with bulky disease) or failure of the host's immune mechanisms to eliminate malignant cells bound with the antibody [4]. A majority of the above mentioned limitations affecting the efficacy of monoclonal antibodies may be overcome using the methods of radioimmunotherapy (RIT). Lymphoma cells are inherently radio-sensitive [7]. However, radiotherapy using an external source of energy is not possible in the majority of lymphomas, since the dose of irradiation necessary for complete removal of malignant cells would be too harmful to other tissues. For this reason radiotherapy is applied only in the treatment of lymphomas in early clinical stages, with a localized tumour mass, commonly in combination with cytotoxic agents or as palliative treatment [8]. Radioimmunotherapy combines the benefits of radiotherapy and immunotherapy – monoclonal antibodies directed against tumor-specific antigens are used to target radioisotopes to sites of disseminated disease. Monoclonal antibody selectively kills lymphoma cells which possess a specific antigen (eg. CD20 or CD22) on their surface, while radiation emitted by the antibody-bound isotope kills the neighbouring cells, including cells inaccessible to the antibody or with insufficient antigen expression (the cross-fire effect). Ibritumomab tiuxetan is a murine anti-CD20 antibody linked via the linker-chelator tiuxetan to Yttrium 90. Numerous clinical trials have confirmed the effectiveness of ^{90}Y ibritumomab tiuxetan in the treatment of recurrent or refractory NHLs. After ^{90}Y -ibritumomab tiuxetan administration patients suffering from follicular lymphomas revealed an overall response rate (ORR) of 82%, including 26% CR (complete response). The results were slightly less promising in the group with more aggressive lymphomas – OR was observed in 43% of patients, including 29% CR [9]. The use of ^{90}Y -ibritumomab tiuxetan in patients with follicular lymphoma resistant to rituximab resulted ORR of 74%, including 15% CR [10]. In recurrent or refractory indolent lymphomas ibritumomab results in statistically higher ORR than rituximab (80% versus 56%), including complete/incomplete remission rate (34% versus 20%) [11]. In the years 1996-1999 four clinical trials involving 211 patients with B-cell NHL (including 153 with FL – 73%) were performed. Responding patients with time to progression (TTP) of 12 months were identified as long-term responding (LTR). Long-term responses were achieved in 37% of all patients and 39% of patients with FL [12].

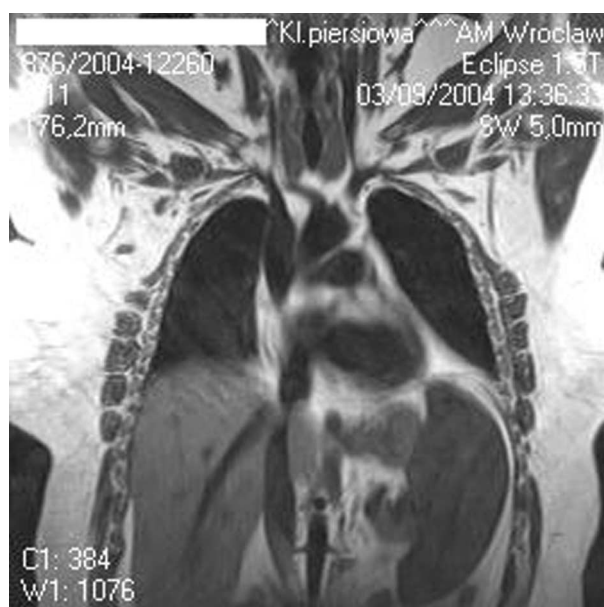

Figure 2. Regression of the involved lymph nodes in the CT scan of the chest 4 months after treatment

Side effects of ^{90}Y -ibritumomab tiuxetan include myelosuppression, which is proportional to the degree of bone marrow infiltration by lymphoma cells. For this reason the drug should not be administered to patients in whom bone marrow infiltration exceeds 25%. The toxic effect of ibritumomab on the haematopoietic system is reversible. Its main manifestation is thrombocytopenia, therefore patients with mild thrombocytopenia (100-150 G/l) receive reduced doses of the drug (0.3 mCi/kg). The effectiveness and safety of the reduced dose was evidenced in trials (ORR of 83%, including 47% CR and CRu, mean TTP was 9,4 months and in patients with CR/CRu – 24.5 months) [13]. About 2% of patients develop human antimouse antibody (HAMA) in response to RIT. Studies show that the percentage of secondary malignancies in patients with RIT is lower than after conventional chemotherapy.

Optimum application of radioimmunotherapy still remains the subject of clinical trials. Ongoing studies investigate the use of ibritumomab in the initial treatment of the disease: in a group of 10 patients with FL in III or IV clinical stage who required treatment, 8 responses were obtained including 5 CR (62%) and 3 PR (partial response) (38%) [14]. Other trials are aimed at increasing the effectiveness of therapy by several administrations of the drug, increasing the dose, combining radioimmunotherapy with chemo and/or megachemotherapy. If the disease relapses after administration of ^{90}Y -ibritumomab tiuxetan, conventional therapy can be used safely and effectively. This has been confirmed in retrospective studies of patients after ^{90}Y -ibritumomab tiuxetan therapy [15].

β -radiation emitted by ^{90}Y has a path length of 5 mm, and therefore it causes no significant damage to healthy tissues surrounding the tumour. Moreover, a low range of radiation and a short half-life allow for the drug to be administered on an out-patient basis.

The experience of administration of the ^{90}Y -ibritumomab tiuxetan to our patient seems to confirm high effectiveness of radioimmunotherapy. Eight months after therapy the patient is in partial remission. The patient still has splenomegaly, though it is lesser than before treatment, but the systemic symptoms of the disease have disappeared and complete regression of the enlarged lymph nodes was observed. The side effects include pancytopenia requiring red blood cell and platelet transfusion, peripheral oedema and pain in the hand joints.

We conclude that radioimmunotherapy is a new, promising modality of treatment of non-Hodgkin's lymphomas, which combines the advantages of immunotherapy and radiotherapy with low toxicity for healthy tissues and organs. Combination of monoclonal antibodies with a radioisotope offers simultaneous irradiation of disseminated lymphomas, which is of a special importance in patients in advanced stages of the disease. Introduction of new therapies, as well as attempts to individualize the therapy in relation to the type of lymphoma and risk factors, bring hopes for improving the results of treatment of these malignancies.

Tomasz Wróbel MD, PhD

Department of Haematology, Blood Neoplasms and Bone Marrow Transplantation
4 Pasteur St.
50-367 Wrocław, Poland
e-mail: wrobel@hemat.am.wroc.pl

grade, follicular, or transformed B-cell non-Hodgkin's lymphoma. *J Clin Oncol* 2002; 20: 2453-2463.

11. Witzig TE, Flinn IW, Gordon LI et al. Treatment with ibritumomab tiuxetan radioimmunotherapy in patients with rituximab-refractory follicular non-Hodgkin's lymphoma. *J Clin Oncol* 2002; 20: 3262-3268.
12. Witzig TE, Molina A, Gordon LI et al. Yttrium 90 ibritumomab tiuxetan radioimmunotherapy induces durable remission in patients with relapsed or refractory B-cell non-Hodgkin's lymphoma: analysis of long-term responders. *Blood* 2003; 102 (suppl) 407a (Abstract 1480).
13. Wiseman GA, Gordon LI, Multani PS et al. Ibritumab tiuxetan radioimmunotherapy for patients with relapsed or refractory non-Hodgkin lymphoma and mild thrombocytopenia: a phase II multicenter Trial. *Blood* 2002; 20: 2453-2463.
14. Sweetenham JW, Cicke K, Arcaroli J et al. Efficacy and Safety of Yttrium 90 Ibritumomab Tiuxetan (Zevalin) Therapy with Rituximab Maintenance in Patients with Untreated Low-Grade Follicular Lymphoma. *Blood* 2004; 104: issue 11 (Abstract 2633).
15. Ansell SM, Schilder RJ, Pieslor PC et al. Anti-lymphoma treatments given subsequent to yttrium 90 ibritumomab tiuxetan (Zevalin) are feasible in patients with progressive non-Hodgkin's lymphoma: a review of the literature. *Clin Lymphoma* 2004; 5: 202-204.

Paper received: 19 January 2005

Accepted: 7 March 2005

References

1. The Non-Hodgkin's Lymphoma Classification Project. A clinical evaluation of the International Lymphoma Study Group classification of non-Hodgkin's lymphoma. *Blood* 1997; 89: 3909-3918.
2. McLaughlin P, Grillo-Lopez AJ, Link BK et al. Rituximab chimeric anti-CD 20 monoclonal antibody therapy of relapsed indolent lymphoma: half of patients respond to a four-dose treatment program. *J Clin Oncol* 1998; 16: 2825-2833.
3. Chinn PC, Leonard JE, Rosenberg J et al. IDEC-Y2B8: a ^{90}Y -labeled anti-CD20 monoclonal antibody conjugated to MX-DTPA, a high-affinity chelator for yttrium [abstract]. *Proc Am Assoc Clin Res* 1999; 40: 574.
4. Cheson BD. Radioimmunotherapy of non-Hodgkin lymphomas. *Blood* 2003; 101: 391-398.
5. McLaughlin P, Grillo-Lopez AJ, Link BK et al. Rituximab chimeric anti-CD20 monoclonal antibody therapy for relapsed indolent lymphoma: half of patients respond to a four-dose treatment program. *J Clin Oncol* 1998; 16: 2825-2833.
6. Wróbel T, Mazur G, Kulickowski K. Zastosowanie przeciwciała monoklonalnego anty CD20 (rituximab) w leczeniu chłoniaków nieziarniczych B komórkowych – doświadczenia własne. *Adv Clin Exp Med* 2003; 12: 589-594.
7. Safwat A. The role of low-dose total body irradiation in treatment of non-Hodgkin's lymphoma: a new look at an old method. *Radiother Oncol* 2000; 56: 1-8.
8. Horning SJ. Natural history of and therapy for the indolent non-Hodgkin's lymphomas. *Semin Oncol* 1993; 20: 75-88.
9. Witzig TE, White CA, Wiseman GA et al. Phase I/II trial of IDEC-Y2B8 radioimmunotherapy for treatment of relapsed or refractory CD20(+) B-cell non-Hodgkin's lymphoma. *J Clin Oncol* 1999; 17: 3793-3803.
10. Witzig TE, Gordon LI, Canabillas F et al. Randomized controlled trial of yttrium-90-labeled ibritumomab tiuxetan radioimmunotherapy versus rituximab immunotherapy for patients with relapsed or refractory low-