

Treatment results of low risk rectal cancer using TEM (transanal endoscopic microsurgery)

Piotr Richter, Tomasz Gach, Rafał Solecki, Tadeusz Popiela, Jan Kulig

Transanal Endoscopic Microsurgery (TEM) is a standard method used to treat rectal adenomas, although its use for the treatment of rectal cancer is still debated. The study analyzes the results of treatment in a group of patients with rectal cancer treated with TEM at the 1st Department of General and GI Surgery Jagiellonian University in Cracow.

Material and method. The study group consisted of patients with low risk rectal cancer (Tis/T1/T2, N0, M0, G1/G2) treated with TEM between April 1996 and December 2003. The inclusion criteria were: tumour of 3 cm in diameter or less localized on the anterior wall 2-12 cm from the anal verge, and on the posterior and lateral walls, 2-14 cm from the anal verge. Preoperative diagnostics included chest X-ray, colonoscopy, rectoscopy, abdominal ultrasonography, transrectal ultrasonography or spiral CT of pelvis, histopathological examination of tumor specimens and anorectal motility studies. Seven patients with T1/T2 tumors 3 cm or less in diameter were treated with neoadjuvant radiotherapy or chemoradiation. Surgery was performed under general or epidural anaesthesia using the Wolf surgical rectoscope.

Results. The study group consisted of 49 patients. There were 22 women (44.9%) and 27 men (55.1%) between 33 and 85 years of age; (mean: 61.3 years). Postoperative pathological examination revealed carcinoma in situ in 28 cases (57.1%) and invasive carcinoma (T1/T2) in 21 (42.9%) cases. Seven (33.3%) patients with T1/T2 tumors received neoadjuvant therapy, which consisted of 5-day radiotherapy in 3 cases (14.3%) and radiochemotherapy in 4 (19%). In 7/49 (14.3%) patients, oncological radicality was not confirmed by histopathological examination, and 6 of these patients underwent radical resection. One patient refused consent to reoperation. Nine (18.7%) of the TEM patients developed complications which did not require surgical intervention. There was no case of perioperative mortality. Local recurrence of the disease occurred in 1 (2.3%) patient, and distal metastases were found in 2 (4.6%) others. Two patients died due to disease progression.

Conclusions. The TEM technique is useful in the treatment of low grade rectal cancers not exceeding 3 cm in diameter. To obtain oncological radicality more accurate system of patient qualification is necessary.

Key words: transanal endoscopic microsurgery, local excision, rectal cancer, radiotherapy

Introduction

The standard in the treatment of rectal cancer is combined therapy that consists of rectal resection (anterior resection of the rectum, abdomino-perineal or abdomino-sacral amputation of the rectum or Hartmann's procedure) together with the excision of regional lymph nodes, preoperative radiotherapy or chemoradiation and, in case of advanced tumours, adjuvant chemotherapy [1-3]. This approach is highly effective, but at the same time associated with a relatively high rate of complications, side-effects and, in the case of patients with a stoma, a significant decrease in the quality of life.

Increased sensitivity as to the patients' quality of life, a trend towards minimizing surgical trauma and an

increase in the number of elderly patients suffering from severe circulatory or respiratory disorders has brought on the development of less invasive or minimally invasive surgical methods. Among these the most promising appears to be Transanal Endoscopic Microsurgery (TEM) introduced into clinical practice in 1983 by Gerhard Buess [4, 5]. This method allows to perform endoluminal excision of rectal tumours together with the entire depth of the rectal wall. Excision is possible practically within the entire rectum and, at present, it is considered standard treatment in case of rectal adenomas. It is also effectively applied in the treatment of inflammatory lesions, hyperplastic polyps and strictures [6-10]. The application of TEM in the treatment of rectal cancer still remains an open issue. It minimizes surgical trauma and the number of postoperative complications, decreases patient discomfort and reduces hospital stay. However, TEM does not allow to achieve free resection margins (proximal, distal and radial) as defined for standard radical resections and to excise the regional lymph nodes. For these reasons it is impossible to consider TEM as an equivalent to a resection procedure. It appears that TEM

1st Department of General and Gastrointestinal Surgery
Jagiellonian University
Kraków, Poland

may be applied in carefully selected group of patients with low risk rectal cancer (G1/G2, T1/T2, N0, M0) [3, 7, 11-14].

The aim of our study was to analyze the results of TEM in the treatment of rectal cancer at the Ist Department of General and GI Surgery Jagiellonian University in Cracow.

Material and method

The analyzed group consisted of patients with low risk rectal cancer (Tis/T1/T2, N0, M0, G1/G2) treated with TEM between April 1996 and December 2003. The inclusion criteria were: tumour size of 3 cm or less, the distance from the anal verge between 2 and 12 cm for tumors localized on the anterior wall, and between 2 and 14 cm on the posterior and lateral walls.

Preoperative diagnostics included chest X-ray, colonoscopy of the entire colon, rectoscopy, abdominal ultrasound, histopathologic examination of biopsy specimens obtained from the tumour and anorectal motility studies. In order to evaluate tumor infiltration depth and local lymph nodes metastases we used transrectal ultrasonography and, in selected cases, spiral CT of the pelvis.

Seven patients with T1/T2 tumours, 3 cm or less in diameter, located on the posterior or lateral wall of the rectum underwent either neoadjuvant radiotherapy (25 Gy with a 4-5 week interval between radiotherapy and surgery) or chemoradiation (irradiation to a total dose of 50.4-55 Gy over 5 weeks with 5-FU infusions in the first and the last week of radiotherapy; 5 weeks interval before operation).

Surgery was performed under general or epidural anaesthesia depending on general condition of the patients and concomitant diseases.

Tumour excision with the surrounding tissues was performed using operative rectoscope (Wolf), 40 mm in diameter and 10-20 cm long, under the control of stereoscopic optics. The instrument is equipped with 4 ports – 1 for optics and 3 for scissors, forceps, a multifunctional instrument, argon and ultrasound coagulation and a suction/lavage pump. The rectoscope was attached to the table with a stabilizing gantry and the rectum was insufflated with carbon dioxide. The procedures were recorded via the optics. In each case full thickness rectal wall (TEM-FT) excision was performed with 1 cm margin of macroscopically normal rectal wall. Additionally, 5 mm margin of the rectal wall was excised. The rectum was reconstructed with a PDS 3/0 continuous stitches.

Final pathological examination of the paraffin-embedded specimens was performed by the same pathologist (K.N.). If

healthy tissue margin was below 10 mm and/or the entire depth of the muscular layer was infiltrated the excision was considered oncologically non-radical.

Oral feeding was recommended 12-36 hrs after surgery while respiratory physiotherapy started 6-12 hrs after surgery with complete patient mobilization after 24 hrs. The patients were discharged home 48-72 hrs after surgery.

All the patients were followed-up prospectively every 3 months in the first year, every 6 months until 5th postoperative year, and then every 18-month until 10 years after surgery. Follow-up regimen covers case history, physical examination, ultrasound, rectoscopy, TRUS colonoscopy, manometric examination, chest X-ray, and neoplastic markers (CEA and CA-19.9).

In all patients undergoing TEM procedures manometric examination is performed pre- and postoperatively and the patients undergoing neoadjuvant radiotherapy are subjected to sphincter manometry before irradiation and before surgery. During the follow-up period manometry is performed 3, 6 and 12 months after surgery to evaluate resting anal pressure (RAP), squeeze anal pressure (SAP), high-pressure zone length (HPZL) and radial asymmetry (RA) [15].

Endorectal ultrasonography was the basic method used to evaluate tumour size, regional lymph nodes, sphincters, and scars after surgery. Due to the high sensitivity and specificity of TRUS, comparable with MRI, wider availability of the examination and lower cost, spiral CT of the pelvis was performed only in doubtful cases or suspicion of recurrence [16-19].

Results

Between April 1996 and December 2003, 141 TEM procedures were performed. The indications included: adenoma in 69 cases, carcinoma in 52, carcinoid in 4, and GIST in 2 cases (Figure 1).

Fifty-two patients with rectal carcinoma were operated. Of these, 2 patients with advanced cancer and 1 patient with T3 tumour were excluded from further analysis.

Treatment results were analyzed for 49 patients with rectal cancer. A group consisted of 22 women (44.9%) and 27 men (55.1%), aged between 33 and 85 years (mean age: 61.3 years). Tumor diameter (Tis and T1/T2 combined) was between 1 and 8 cm (mean: 3.2 cm), the distance from the transitional zone was between 1 and 18 cm (mean: 7.6 cm) (Table I). Postoperative pat-

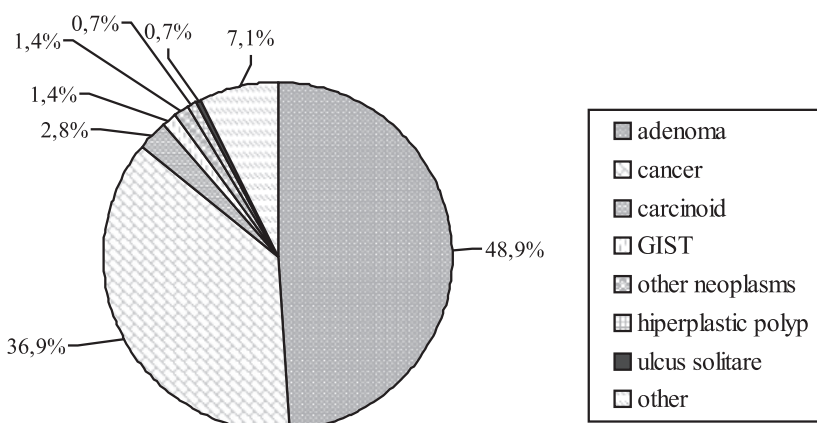


Figure 1. Indications for TEM procedure

Table I. Characteristics of the patient group

Gender	
male	23
female	30
Average age (years)	61.3 ± 12
Staging	
Tis	28
T1/T2	21
Tumour size (cm)	
average	3.2 ± 1.7
min	1
max	8
Distance from transitional zone (cm)	
average	7.6 ± 3.9
min	1
max	18

hologic examination revealed carcinoma *in situ* in 28 cases (57.1%) and invasive cancer (T1/T2) in 21 cases (42.9%). Seven patients (33.3%) with T1/T2 tumours received neoadjuvant therapy: 5-day radiotherapy in 3 cases (14.3%) and chemotherapy in 4 cases (19%). The results are shown in Tables II and III.

Table II. Results of transanal endoscopic microsurgery

	Tis	T1/T2	Łącznie
Operated patients	28	21	49
Incomplete excision	3 (10.7%)	4 (19%)	7 (14.3%)
Local recurrence	1 (4%)	–	1 (2.4%)
Distal metastases	–	2 (11.8%)	2 (4.8%)
Complications	5 (17.8%)	4 (20%)	9 (18.7%)
Mortality	–	2 (9.5%)	2 (4.1%)

Table III. Complications after TEM

Complications	Tis	T1/T2	Overall
Intraperitoneal perforation	1	1	2
Dehiscence of the suture line	–	1	1
Pneumonia	1	1	2
Meningeal reaction after anaesthesia	1	–	1
Anorectal dysfunction	2	1	3
Overall	5	4	9

In 7 (14.3%) of 49 patients the operation was oncologically nonradical (healthy tissue margin of less than 10 mm and infiltration of the entire width of the rectal wall). Six of these underwent radical surgery and one refused consent to reoperation. Complications occurred in 9 (18.75%) patients treated with TEM and included dehiscence of the suture line in 1, transient anorectal dysfunction in 3, meningeal reaction after epidural anaesthesia in 1, pneumonia in 1, and intraoperative peritoneal injury in 1 case. None of the patients demanded reoperation due to the complications and there was no case of death in the immediate postoperative period. Local recurrence was observed in 1 case (2.3%), and 2 (4.6%) patients developed distal metastases. Two patients died due to disease progression.

Carcinoma *in situ*

In the entire group of 49 patients carcinoma *in situ* was diagnosed in 28 cases. Three patients (10.7%) were reoperated due to the lack of oncological radicality in the primary excised specimen; 1 patient underwent abdomino-perineal resection of the rectum, another 1 anterior resection of the rectum, and 1 was reoperated with TEM. Local recurrence was observed in 1/25 cases (4%). Five (17.8%) patients developed the following complications: anorectal dysfunction in 2 cases, meningeal reaction after a epidural anaesthesia in 1, peritoneal injury in 1, and pneumonia in 1 case. There were no cancer-related deaths in this subgroup.

Invasive carcinoma (T1/T2)

In the entire group of 49 patients T1 and/or T2 carcinoma was diagnosed in 21 cases, 7 of whom (33.3%) underwent neoadjuvant radio- or radiochemotherapy. In 14 cases (66.7%) the treatment was limited to local excision without neoadjuvant therapy. Three patients underwent abdomino-perineal rectum resection due to the lack of oncological radicality. One of them was operated immediately after TEM procedure based on the intraoperative pathologic findings, and another one refused consent to abdomino-perineal resection. Complications were observed in 4/20 cases: 1 case of dehiscence of suture line, 1 case of peritoneal injury in the course of the procedure, 1 case of stool incontinency, and 1 case of pneumonia in the postoperative period. Two patients (11.8%) underwent surgery for recurrence.

In the subgroup of patients receiving radiotherapy complete response was obtained in 3 cases – there were no cancer cells in the analyzed specimen; in 2 cases we observed downstaging while in another 2 cases radiotherapy had no effect on the stage of the tumour (Table IV). One patient (14.3%) was reoperated due to the lack of oncological radicality. One patient (14.3%) developed distal metastases and this patient eventually died due to cancer progression.

Table IV. Results of treatment of rectal cancer with and without radiotherapy – a comparison

	Radiotherapy	Without radiotherapy
Number of patients	7	14
Incomplete excision	1 (14.3%)	3 (21.4%)
Recurrence	1 (16.6%)	1 (9.1%)

In the subgroup of patients without neoadjuvant therapy, 2 patients (14.3%) were reoperated due to the lack of oncological radicality, while 1 patient refused consent to reoperation. During the follow-up 1 patient (8.3%) developed distal metastases and died eventually due to disease progression.

Discussion

Radical operation (anterior resection of the rectum and abdomino-sacral or abdomino-perineal amputation of the rectum) is the standard in the treatment of rectal tumours. Although the need for radical treatment of advanced rectal tumours has not been questioned, yet in the case of adenomas and non-advanced tumours there is a demand for a therapeutic methods that bring about comparable low recurrence rates and long-term survivals with distinctly lower number of complications.

TEM procedures have a relatively low recurrence rate (thus comparing favourably with conventional local excision using Parks dilators) and a significantly lower complication rate when compared to conventional resections. This is associated with the used equipment and

surgical technique [7]. In 3 cases of low tumour localization adjacent to the transitional zone, TEM excision was extended by the resection of the lower part of the tumour using Parks dilators.

In the entire patient group complications were observed in 18.75% of cases (17.8% of patients with carcinoma *in situ* and 20% of patients with infiltrating cancer – NS). The number of complications is similar to the reported in literature, where it ranges between 3.4% [2] and 38.2% [20] with neither quantitative nor qualitative differences [2, 14, 20-22]. Transient anorectal dysfunction was the most common complication, observed in 3 cases. In another 2 cases we observed pneumonia, 1 patient developed wound dehiscence, and in 1 case the peritoneum was injured intraoperatively. None of our patients required reoperation due to the complications as opposed to the observations of other authors [7, 22]. There are reports from the literature describing single death cases as a result of TEM procedures mostly due to cardio-pulmonary insufficiency [22] or surgical wound sepsis [23]. There were no death cases in the analyzed group of patients due to the postoperative complications [7, 22, 23].

The benefit of radical surgery, especially in the case of advanced rectal tumours, is the possibility to perform lymphadenectomy and achieving oncological radicality due to the precise rectal cancer staging in the entire specimen, including the entire rectal wall and mesorectum. This is reflected in a relatively low rate of recurrences and an increased 5-year survival. With TEM excision it is not possible to perform lymphadenectomy, however, as reported in the literature, regional lymph node metastases were found in 0 – 12% of T1 tumors and in 12 – 28% of T2 tumors (24-26). This may account for the poor results of the TEM in more advanced tumours [11, 14]. In selected group of patients, who meet the criteria

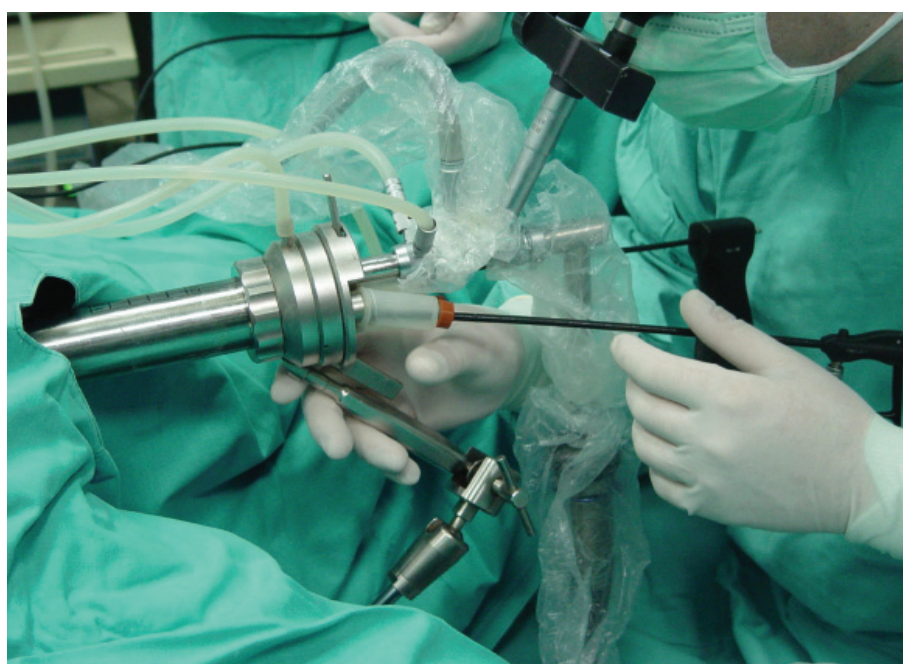


Figure 2. The instrumentation for transanal endoscopic microsurgery

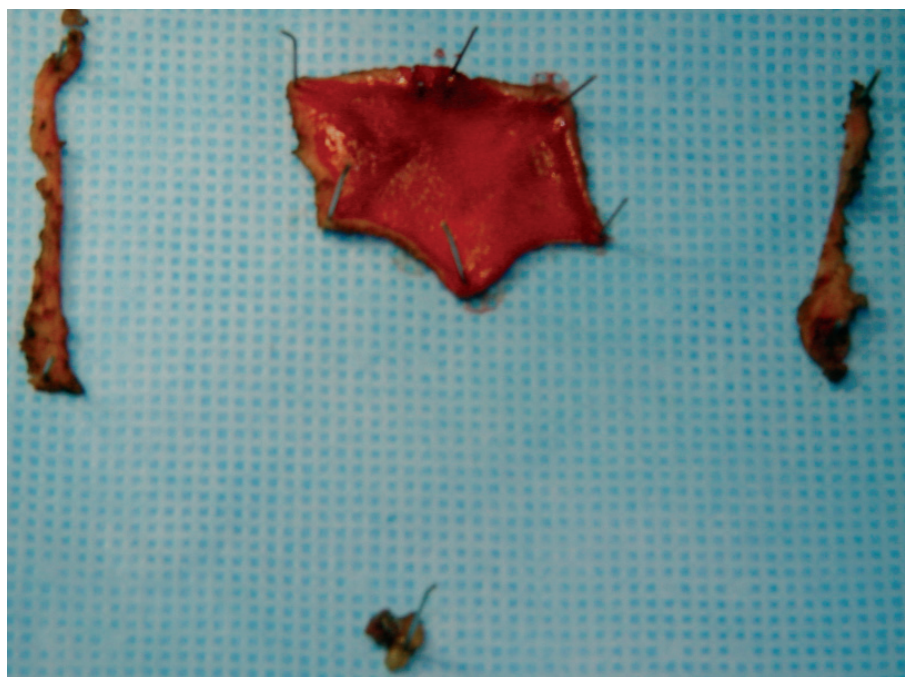

Figure 3. The surgical specimen after Transanal Endoscopic Microsurgery

of Hermanek and Gall introduced in 1986, the results of local excision are comparable with those achieved by radical surgery [2, 14, 24]. In the follow-up local recurrence and/or distal metastases were found in 3/42 cases (7.1%). In the Tis subgroup there was 1 case of local recurrence (4%). In the T1/T2 subgroup there were 2 (11.8%) recurrences (liver metastases) and 2 patients died due to disease progression. The results obtained in our patients are similar to reported by other authors [2, 11, 14] and indicate the necessity of careful patients qualification to TEM procedures. Two cases of distal metastases (11.8%) make the use of TEM in patients with T2 or more advanced rectal cancer questionable. The neoadjuvant radiotherapy was applied with the intent of sterilising the structures of the mesorectum. Due to small number of patients who underwent preoperative radiotherapy the effect of this treatment is not clear. However, some benefits – such as downstaging or even a total response, i.e. disappearance of cancer cells were observed. Though some authors reported significantly improved long-term results after neoadjuvant radiotherapy [3, 21], comparable with the results of radical surgery, in the prevalent number of studies the results are comparable with ours [3, 21, 22, 27, 28]. The results obtained in our study are promising and should be analyzed in further clinical trials.

Conclusions

TEM excisions are useful for the treatment of non-advanced rectal tumours less than 3 cm in diameter.

Due to the necessity of providing oncological radicality and to the technical limitations of the technique, TEM calls for very careful patient selection.

The use of TEM in the more advanced tumours remains an open issue.

Professor Jan Kulig MD, PhD

1st Department of General and Gastrointestinal Surgery
Jagiellonian University
Kopernika 40, 31-501 Kraków, Poland
mskulig@cyf-kr.edu.pl

References

1. Wu J, Fazio V. Management of rectal Cancer. *J Gastrointestinal Surg* 2004; 8: 139-49.
2. Heintz A, Morschel M, Junginger T. Comparison of results after transanal endoscopic microsurgery and radical resection for T1 carcinoma of the rectum. *Surg Endosc* 1998; 12: 1145-8.
3. Lezoche E, Guerrieri M, Paganini AM et al. Long-term Results of Patients with pT2 Rectal Cancer Treated with Radiotherapy and Transanal Endoscopic Microsurgical Excision. *World J Surg* 2002; 26: 1170-4.
4. Buess G et al. Technique and results of transanal endoscopic microsurgery in early rectal cancer. *Am J Surg* 1992; 163: 63-70.
5. Buess G et al. Das System für die transanale endoskopische Rektumoperation. *Chirurg* 1984; 55: 677-80.
6. Mörschel M, Heintz A, Bußmann M et al. Follow-up after transanal endoscopic microsurgery or transanal excision of large benign rectal polyps. *Langenbeck's Arch Surg* 1998; 383: 320-4.
7. Langer C, Liersch T, Süß M et al. Surgical cure for early rectal carcinoma and large adenoma: transanal endoscopic microsurgery (using ultrasound or electrosurgery) compared to conventional local and radical resection. *Int J Colorectal Dis* 2003; 18: 222-9.
8. Kato K, Saito T, Matsuda M et al. Successful treatment of rectal anastomotic stenosis by transanal endoscopic microsurgery (TEM) using the contact Nd: YAG laser. *Surg Endosc* 1997; 11: 485-7.
9. Winde G, Reers B, Berns T, Bunte H. Transanal endoscopic microsurgical resection of anastomotic stricture following anterior resection of the rectum. *Aktuelle Chirurgie* 1995; 30: 136-9.
10. Pigot F, Bouchard D, Mortaji M et al. Local excision of rectal villous adenomas. *Dis Colon Rectum* 2003; 46: 1345-50.

11. Bentrem D et al. T1 Adenocarcinoma of the Rectum. Transanal excision or radical surgery. *Ann Surg* 2005; 242: 472-9.
12. Demartines N, von Flue MO, Harder FH. Transanal Endoscopic Microsurgical Excision of Rectal Tumors: Indications and Results. *World J Surg* 2001; 25: 870-5.
13. Heintz A, Morschel M, Junginger T. Comparison of results after transanal endoscopic microsurgery and radical resection for T1 carcinoma of the rectum. *Surg Endosc* 1998; 12: 1145-8.
14. Lee W, Lee D, Choi S et al. Transanal endoscopic microsurgery and radical surgery for T1 and T2 rectal cancer. *Surg Endosc* 2003; 17: 1283-7.
15. Herman RM, Richter P, Wałęga P, Popiela T. Anorectal sphincter function and rectal barostat study in patients following transanal endoscopic microsurgery. *Int J Colorectal Dis* 2001; 16: 370-6.
16. Kwok H, Bissett IP, Hill GL. Preoperative staging of rectal cancer. *Int J Colorectal Dis* 2000; 15: 9-20.
17. Garcia-Aguilar J, Pollack J, Lee SH et al. Accuracy of endorectal ultrasonography in preoperative staging of rectal tumors. *Dis Colon Rectum* 2002; 45: 10-15.
18. Sailer M, Leppert R, Kraemer M et al. The value of endorectal ultrasound in the assessment of adenomas T1- and T2-carcinomas. *Int J Colorectal Dis* 1997; 12: 214-9.
19. Hernandez de Anda E, Lee SH, Finne CO et al. Endorectal ultrasound in the follow-up of rectal cancer patients treated by local excision or radical surgery. *Dis Colon Rectum* 2004; 47: 818-24.
20. Gavagan J, Whiteford M, Swanstrom L. Full-thickness intraperitoneal excision by transanal endoscopic microsurgery does not increase short-term complications. *Am J Surg* 2004; 187: 630-4.
21. Guerrieri M, Feliciotti F, Baldarelli M et al. Sphincter-saving surgery in patients with rectal cancer treated by radiotherapy and transanal endoscopic microsurgery: 10 years' experience. *Dig Liver Dis* 2003; 35: 876-80.
22. de Graaf EJ, Doornebosch PG, Stassen LP et al. Transanal endoscopic microsurgery for rectal cancer. *Eur J Cancer* 2002; 38: 904-10.
23. Klaue HJ, Bauer E. Retroperitoneale Phlegmone nach transanal endoskopischmikrochirurgischer Excision eines Rectumadenoms. *Chirurg* 1997; 68: 84-6.
24. Hermanek P, Gall FP. Early (microinvasive) colorectal carcinoma. Pathology, diagnosis, surgical treatment. *Int J Colorectal Dis* 1986; 1: 79-84.
25. Mellgren A, Sirivongs P, Rothenberger DA et al. Is local excision adequate therapy for early rectal cancer? *Dis Colon Rectum* 2000; 43: 1064-429.
26. Minsky BD, Rich T, Recht A et al. Selection criteria for local excision with or without adjuvant radiation therapy for rectal cancer. *Cancer* 1989; 63: 1421-9.
27. Ruo L, Guillem J, Minsky B et al. Preoperative radiation with or without chemotherapy and full-thickness transanal excision for selected T2 and T3 distal rectal cancers. *Int J Colorectal Dis* 2002; 17: 54-8.
28. Nakagoe T, Ishikawa H, Sawai T et al. Long-term outcomes of radical surgery after gasless video endoscopic transanal excision of T1/T2 rectal cancers. *Eur J Surg Oncol* 2004; 30: 638-42.

Paper received: 19 April 2006

Accepted: 31 May 2006