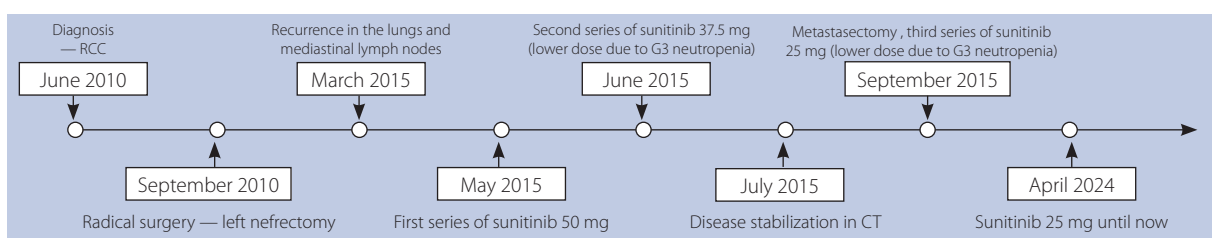


## Advanced renal cancer as a chronic disease — long-term disease control with a tyrosine kinase inhibitor (TKI) inhibitor

Aleksandra Grela-Wojewoda<sup>1</sup>, Urszula Myśliwiec<sup>2</sup>, Mirosława Puskulluoglu<sup>1</sup>, Marek Ziobro<sup>1</sup>

<sup>1</sup>Department of Clinical Oncology, Maria Skłodowska-Curie National Research Institute of Oncology, Krakow Branch, Poland

<sup>2</sup>5<sup>th</sup> Military Hospital with Polyclinic in Cracow, Poland



**Figure 1.** Treatment history — timeline; RCC — renal cell carcinoma; CT — computed tomography

A 68-year-old female patient diagnosed with clear cell renal cell carcinoma in June 2010 underwent radical left nephrectomy in September 2010. Computed tomography (CT) performed in March 2015, revealed metastases to the right lung and mediastinal lymph nodes, which confirmed disease recurrence. Treatment with sunitinib commenced in May 2015, initially at a dosage of 50 mg. One month after initiating therapy, the patient required the commencement of antihypertensive medications due to the onset of hypertension. During the treatment the dose was de-escalated twice due to the occurrence of Grade 3 adverse effects (neutropenia) as per the Common Terminology Criteria for Adverse Events (CTCEA) (Fig 1). A CT performed in July 2015 indicated disease stability according to the Response Evaluation Criteria in Solid Tumors (RECIST).

In September 2015, an R1 metastasectomy was performed, and CT has shown stabilization (according to RECIST 1.1 — stable disease) up to now.

Currently the patient is taking the 25 mg of sunitinib every other day. Disease stabilization is maintained.

In conclusion: 1) long-term administration of sunitinib at reduced doses is safe and leads to sustained responses; 2) hypertension is a common cardiological complication associated with sunitinib use and, at the same time, a favorable prognostic factor for treatment response. Therefore, support from an internist is essential [1, 2].

Contemporary oncological treatments frequently enable individuals with advanced cancer to achieve prolonged survival, effectively transforming cancer into a chronic ailment.

### References

1. Grela-Wojewoda A, Pacholczak-Madej R, Adamczyk A, et al. Cardiotoxicity Induced by Protein Kinase Inhibitors in Patients with Cancer. *Int J Mol Sci.* 2022; 23(5), doi: 10.3390/ijms23052815, indexed in PubMed: 35269958.
2. Lyon AR, López-Fernández T, Couch LS, et al. ESC Scientific Document Group. 2022 ESC Guidelines on cardio-oncology developed in collaboration with the European Hematology Association (EHA), the European Society for Therapeutic Radiology and Oncology (ESTRO) and the International Cardio-Oncology Society (IC-OS). *Eur Heart J.* 2022; 43(41): 4229–4361, doi: 10.1093/eurheartj/ehac244, indexed in PubMed: 36017568.

### How to cite:

Grela-Wojewoda A, Myśliwiec U, Puskulluoglu M, Ziobro M, *Advanced renal cancer as a chronic disease — long-term disease control with a tyrosine kinase inhibitor (TKI) inhibitor.* *NOWOTWORY J Oncol* 2024; 74: 337.

This article is available in open access under Creative Commons Attribution-Non-Commercial-No Derivatives 4.0 International (CC BY-NC-ND 4.0) license, allowing to download articles and share them with others as long as they credit the authors and the publisher, but without permission to change them in any way or use them commercially.