

Available online at www.sciencedirect.com

ScienceDirect

journal homepage: <http://www.elsevier.com/locate/pjnns>

Review article

Ultra high field TOF-MRA: A method to visualize small cerebral vessels. 7 T TOF-MRA sequence parameters on different MRI scanners – Literature review

Cezary Grochowski^{b,*}, Grzegorz Staśkiewicz^a^a Department of Anatomy in Lublin ul. Jaczewskiego 4 (Collegium Anatomicum), Lublin 20-090, Poland^b Neurosurgery and Pediatric Neurosurgery Department in Lublin, Medical University of Lublin, Poland

ARTICLE INFO

Article history:

Received 22 February 2017

Accepted 30 June 2017

Available online 8 July 2017

Keywords:

7 T MRI

Ultra high field magnetic resonance MRA

Magnetic resonance angiography

Cerebral small vessels

ABSTRACT

Introduction: Time-of-flight (TOF) angiography is a technique allowing to visualize the blood flow in vessels. 7 T ToF-MRA is able to visualize the whole Circle of Willis including small perforating branches without any known side effects as opposed to usually used DSA and CTA with high exposition to the radiation and high doses of contrast as far as CTA is concerned.

Aim: The aim of this review is to describe ultra-high field ToF-MRA and present different protocol data depending on the scanner used in the study.

Materials and methods: PubMed, Embase, Ovid, Google Scholar databases were searched. Selection of studies for this systematic review included 7 T magnetic resonance angiography studies. We searched for type of head coil used in various studies, flip angle, echo time, repetition time, field-of-view (FOV), number of slices per slab, matrix, voxel size and acquisition time.

Discussion: Visualization for the small perforating vessels of the Circle of Willis, that are not fully visualized using low-field-strength MRA is improving with increasing magnetic field strength, which has been proved by several studies.

Conclusion: Ultra-high field ToF-MRA has found to be a superior method in depicting cerebral microvasculature. 7 T ToF-MRA seems to be a reliable method for visualization of arteries up to the second order cerebral arteries and has a potential to replace DSA.

© 2017 Published by Elsevier Sp. z o.o. on behalf of Polish Neurological Society.

1. Introduction

Time-of-flight (TOF) angiography is a technique allowing to visualize the blood flow in vessels. The main advantage of the

technique is the fact that there is no need to administer contrast, which makes it safer and more convenient for the patient. The first to describe the TOF method was Suryan [1] and for the first time was used by Hinshaw et al. [2] to visualize the blood vessels. The aim of this technique is to receive large

* Corresponding author at: Szeligowskiego 8/3, 20-883 Lublin, Poland.

E-mail address: cezary.grochowski@o2.pl (C. Grochowski).<http://dx.doi.org/10.1016/j.pjnns.2017.06.011>

0028-3843/© 2017 Published by Elsevier Sp. z o.o. on behalf of Polish Neurological Society.

magnitude of magnetization from the moving spins and small magnitude of the magnetization of the stationary spins. This phenomenon is possible due to the change of the amplitude of the signal from moving blood as it flows into the imaged volume and the fact that movement of the blood during applied gradients is changing a phase because of the motion, which is called phase effect. Exposition to increasing number of excitation pulses results in decreasing spin signal until the saturation value. The main aim is to expose the flowing spins to small number of excitation pulses and surrounding stationary spins to large number of those pulses. The unsaturated blood spins entering into an image slice are being enhanced because of the motion of the blood and giving stronger signal than the surrounding tissue spins. This results with signal contrast between blood and surrounding tissues allowing to distinguish them in the MRI scan.

This sequence has become very useful in diagnosing intracranial aneurysms [3,4], non-traumatic subarachnoid hemorrhage [5] and other vascular diseases such as Moyamoya disease [6,7]. Several studies claim that 7 T MRI scanners are far more superior compared to the 1.5 T and 3 T MRI in visualizing small perforating vessels because of high SNR provided by the ultra high field and ability to visualize in high spatial resolution [8–10]. According to the literature SNR in 3 T MRI is 100% bigger in comparison to 1.5 T MRI [11]. Moreover, SNR in 7 T MRI 88% bigger than in 3 T MRI [12]. Contrast-enhanced digital subtraction angiography was by far the only way to visualize small arterial cerebral branches, however, because of its high risk of side effects [13,14] and a considerable radiation dose up to 3.8 Gy applied to the patient [15], it is not used for scientific purposes. Conventional noninvasive MRA and even contrast-enhanced MRA does not provide enough spatial resolution to visualize small vessels [16,17], which is helpful while diagnosing vascular changes in migraine, depression or small vessel disease. 7 T ToF-MRA allows to visualize the whole Circle of Willis including small perforating branches without any known side effects [18,19] as opposed to usually used DSA and CTA with high exposition to the radiation and high doses of contrast as far as CTA is concerned. There are also no evidence suggesting increased heating in patients with post-surgical implants and only minor artifacts from the implants were observed, not likely to affect the image quality [20–22].

2. Materials and methods

2.1. Literature search strategy

PubMed, Embase, Ovid, Google Scholar databases were searched by author (CG). The key words: “7 T MRA”; “time of flight MRA”; “ultra high field MRA” were used. A systematic review of the studies published between 2007 and January 2017 was performed and the reference list of every reviewed article was analyzed for potentially useful studies.

2.2. Selection criteria

Selection of studies for this systematic review included 7 T magnetic resonance angiography studies. We reviewed

studies written in English only. Abstracts, conference presentations, case reports were excluded. We searched for studies that contained the ultra high field MRA sequence parameter.

2.3. Interpretation of studies

Extracted data is presented in tables and sorted according to the year of published paper. MRA sequence parameters are presented for various types of MRI scanners. We searched for type of head coil used in various studies, flip angle, echo time, repetition time, field-of-view (FOV), number of slices per slab, matrix, voxel size and acquisition time.

3. Results

Twenty studies were qualified to this systematic review. The qualification process is presented on the flow diagram provided in the article (Fig. 1). One paper was excluded from the review because of the insufficient data provided in the study. Different ToF-MRA protocol data based on the used scanner was extracted including type of the head coil, flip angle, echo time, repetition time, field-of-view (FOV), number of slices per slab, matrix, voxel size and acquisition time. All gathered data is presented in Table 1 and listed according to the year of publish.

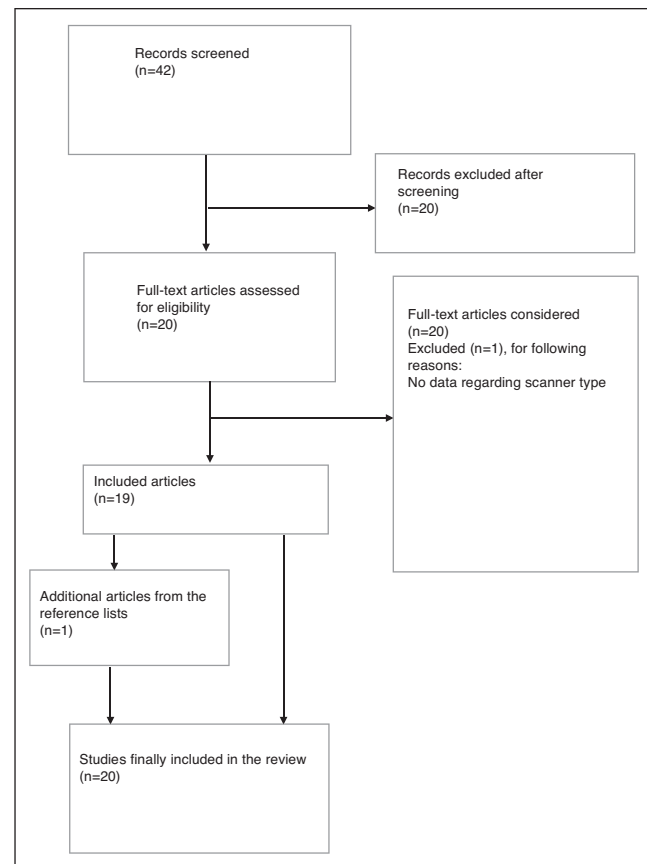


Fig. 1 – Flow diagram review.

Table 1 – Presentation of different ultra-high field ToF-MRA depending on the scanner.

Author	Mri co.	Coil	Flip angle (°)	TE (ms)	TR (ms)	FOV	Slices per slab	Matrix	Voxel size (mm ³)	Acquisition time
von Morze et al. [12]	GE Healthcare, Waukesha, WI, USA	Eight-channel phased array receiver coils	25	2.5 ms	0.030 s	240 mm × 180 mm × 120 mm	38 mm × 0.5 mm thick	384 × 224 × 120	0.63 × 0.8 × 1	13 min 1 s
Maderwald et al. [33]	Magnetom 7 T, Siemens Medical Solutions, Erlangen, Germany	Eight-channel head coil	30	3.46 ms	0.062 s	200 mm × 133 mm	N/A	512 × 247	0.55 × 0.39 × 0.7	17 min 50 s
Heverhagen et al. [31]	Achieva; Philips, Cleveland, OH	Transmit/receive head coil	20	3.5 ms	0.015 s	220 mm × 165 mm	N/A	512 × 384	0.43 × 0.43 × 1.2	aprox. 10 min
Zwanenburg et al. [10]	Philips Medical Systems, Cleveland, OH	Volume transmit and 16 channel receive head coil	16–24	2.4 ms	0.023 s	199 mm × 179 mm × 70 mm	N/A	332 × 294 × 30	0.6 × 0.6 × 0.6	9 min 55 s
von Morze et al. [46]	GE Healthcare, Waukesha, WI, USA	Eight-channel phased array receiver coils	25	2.6 ms	0.030 s	220 mm	N/A	512 × 384	N/A	12 min 45 s
Kang et al. [8]	Magnetom, Siemens AG, Berlin, Germany	Hybrid 16-rung quadrature transmit/receive (Tx/Rx)-type BC coil	25	3.8 ms	0.015 s	220 mm × 165 mm	128	640 × 480	0.23 × 0.23 × 0.36	11 min 5 s
Conijn et al. [30]	Philips Healthcare, Cleveland, OH, USA	16-Channel receive-only head coil	16–24	2.3–2.6 ms	0.023 s	200 mm × 181 mm × 68 mm	150	332 × 294 500 × 354	0.6 × 0.6 × 0.6 0.4 × 0.5 × 1.0	9 min 30 s
Kang et al. [28]	Magnetom, Siemens, Erlangen, Germany	Single-channel volume coil	25	4.84 ms	0.015 s	135 mm × 180 mm	104	576 × 768	N/A	8 min 31 s
Liem et al. [39]	Philips Healthcare, Best, The Netherlands	16-Channel receive array head coil	30	4.3 ms	0.016 s	180 mm × 170 mm	161	784 × 737	0.23 × 0.23 × 0.23	10 min 41 s
Johst et al. [43]	Magnetom 7 T, Siemens Healthcare, Erlangen, Germany	32-Channel Tx/Rx head coil	20	4.34 ms	0.020 s		112	896 × 756	0.22 × 0.22 × 0.41	6 min 22 s
Laurig et al. [29]	Philips Healthcare, Cleveland, OH	Quadrature transmit head coil together with a 16-channel receive array	20	3.4 ms	0.020 s	200 mm × 190 mm	300	N/A	0.25 × 0.25 × 0.3	11 min 43 s
Stamm et al. [23]	Achieva Philips Medical Systems, Cleveland, OH, USA	Quadrature transmit/receive head coil	10	3.5 ms	0.015 s	220 mm × 165 mm	100	512 × 384	0.43 × 0.43 × 1.2	9 min 44 s
Wrede et al. [32]	Magnetom 7 T, Siemens Healthcare, Erlangen, Germany	32-Channel Rx/Tx head coil	18	4.34 ms	0.020 s	200 mm × 169 mm × 46 mm	112	896 × 756 (non-interpolated)	0.22 × 0.22 × 0.41	6 min 22 s
Matsushige et al. [49]	MAGNETOM 7 T, Siemens Healthcare GmbH	1-Channel transmit/32-channel	$\alpha = 18^\circ$	4.34 ms	0.020 s	200 mm × 169 mm × 46 mm	112	896 × 756 (non-interpolated)	0.22 × 0.22 × 0.41	6 min 22 s

Table 1 (Continued)

Author	Mri co.	Coil	Flip angle (°)	TE (ms)	TR (ms)	FOV	Slices per slab	Matrix	Voxel size (mm ³)	Acquisition time
Harteveld et al. [47]	Philips Healthcare, Cleveland, OH, USA	32-Channel receive head coil and volume transmit/receive coil for transmission	25	3.4 ms	15.3 ms	200 mm × 190 mm × 50 mm	250	N/A	0.25 × 0.3 × 0.4	aprox. 9 min
Zhang et al. [40]	Magnetom 7 T, Siemens Healthcare AG, Erlangen, German	Homemade 8-channel phased-array head coil	18	N/A	0.020 s	210 mm × 164 mm × 115 mm	48	N/A	0.32 × 0.32 × 0.4	N/A
Wermer et al. [25]	Philips Healthcare, Best, The Netherlands	Quadrature volume transmit and 32 channel receive headcoil	30	4.2 ms	0.016 s	N/A	161	N/A	0.23 × 0.23 × 0.23	11 min
Neumann et al. [48]	Magnetom 7 T, Siemens Healthcare AG, Erlangen, Germany	24 channel head coil	17	4.76 ms	0.015 s	N/A	52	N/A	0.34 × 0.33 × 0.5	15 min 17 s
Deng et al. [34]	Magnetom Siemens, Beijing, China	24-Channel phased-array head coil	22	5.58 ms	0.037 s	200 mm × 200 mm	N/A	768 × 432	0.26 × 0.46 × 0.4	N/A
Oh et al. [26]	Philips Healthcare, Cleveland, OH, USA	Volume transmit and 16-channel receiving head coil	30	1.36 ms	0.065 s	220 mm × 199 mm × 144 mm	N/A	552 × 332	0.4 × 0.6 × 0.8	10 min 32 s

3.1. Protocol presentation

4. Discussion

Visualization for the small perforating vessels of the Circle of Willis, that are not fully visualized using low-field-strength MRA is improving with increasing magnetic field strength, which has been proved by several studies [23–30]. Nowinski et al. [24] compared the visualization of small cerebral vessels (their length and volume) and proved that both values increased with field strength, missing 6% of the vasculature volume using 3 T MRA and only 1% using 7 T MRA. Heverhagen et al. [31] presented the results of his study where only 60% of the first-order branches and none of the second-order branches were visualized in their entire length using 1.5 T MRA, 90% of first-order branches and 88% of second-order branches using 3 T MRA and all of the first and second order branches were visualized using 7 T MRA. Moreover 7 T MRA has even allowed to visualize additional higher order branches, not visible at 1.5 T and 3 T MRA. Because of increased spatial resolution compared to 1.5 T and 3 T MRA, better contrast between vessels and background tissue can be achieved, which allows better visualization of small vessels. This was confirmed by using the same protocol on 3 T and 7 T TOF-MRA [25]. High diagnostic ability and vessel-tissue contrast of 7 T TOF-MRA and MPRAGE compared to DSA and 1.5 T MRA was shown by Wrede et al. No difference between the image quality between 7 T TOF-MRA and 7 T MPRAGE was detected [32], however, Maderwald claimed that the MIPs of TOF sequences turned out to be significantly better than VIBE and MPRAGE for small vessels because of the good depiction of vessels in the MIP images [33]. Hartevelde et al. found ToF-MRA to be superior to SWAN method in the depiction of small arteries. Cho claimed that none of the small perforators or vessels can be seen using 1.5 T MRI [9]. According to Heverhagen, even contrast-enhanced MRA, providing much higher spatial resolution than the traditional MRA [16,17] could not reach the results in achieving vascular information compared to 7 T MRA [31]. Oh et al. came to the same conclusion that 7.0 T TOF-MRA provided better visualization of the first and second small branch arteries and that 7 T MRA provided higher detection rate of signal void than 3 T MRA and it turned out to be more sensitive to the slow-flowing blood within smaller peripheral vessels [26]. Kang et al. proved in his study that 7 T MRA allows better blood-to-tissue contrast because of the increased T_1 recovery time of tissues and better suppression of the background signal to noise compared with that of the blood vessels, which assures better non-invasive visualization of the microvasculature in vivo [8]. In that study Kang was able to obtain a high quality, more clear and distinct scans of lenticulostriate arteries (LSA), that were not well visualized with lower field MRA as well as DSA images. Cho et al. came to a conclusion that high field MRA shows clearer picture of all LSAs and the branches of LSAs in comparison to poor in contrast DSA imaging. Moreover they claim that high field MRA could serve as a tool for noninvasive microvasculature imaging in vivo [9]. Dang et al. also confirm that 7 T MRA

provides better SNR and increased T_1 relaxation time and greater number of high-signal-intensity areas compared to 3 T MRA and provides much better MR images especially of the small arteries, which is useful to evaluate the progression of Moyamoya disease (MMD). By far, DSA was considered as a primary diagnostic test in MMD, but according to many authors it can be replaced by 7 T MRA, which can be extremely beneficial in pediatric population. DSA may cause various complications among younger patients because of the narrow arteries, the need for sedation and contrast allergy [34]. 7 T MRA allows to avoid those side effects and can be used as a non-invasive diagnostic tool among patients with small progression of the MMD and as a follow-up test for patients, who did not undergo the surgical therapy. This technique can also provide morphometric information on the superficial temporal artery, which could be useful while planning the surgery.

Wermer observed the supremacy of the 7 T ToF-MRA, while differentiating true intracranial aneurysms from infundibula. Using this technique the presence of an intracranial aneurysm could be excluded and the patients could be reassured that further follow-up is not necessary, because infundibula are considered non-pathological lesions. Another advantage of the technique is the fact that it can be considered superior to DSA, which would allow to decrease the use of invasive techniques with high exposure to radiation [25]. Cho et al. came to a conclusion that ultra-high field MRA shows clearer picture of all LSAs and the branches of LSAs in comparison to poor in contrast DSA imaging. Moreover they claim that high field MRA could serve as a tool for noninvasive microvasculature imaging in vivo. Heverhagen et al. claim that SNR of the major arteries were higher at 7 T MRI than at 1.5 T or 3 T and having quality of the image comparable to the DSA images [35–37]. Furthermore, ultra high field MRA is a noninvasive technique, requiring less time to perform than DSA, eliminating the exposure to ionizing radiation, requiring no intravenous contrast agents, allowing quantitative flow measurement and assessment of the flow direction [23]. The lack of contrast agent is very beneficial to patients with poor renal function and allow to reduce the probability of side effects. According to Heverhagen 7 T MRA quality of the image will allow to replace DSA as a diagnostic tool to diagnose microvasculature condition such as vasculitis and vasospasm [31] for instance 7 T MRA study performed by Liem et al. revealed that luminal diameters (length, number, cross-sectional area) of LSA are similar in patients with CADASIL and control subjects. No focal stenotic segments were found in patients with CADASIL, which was non-expected but consistent with small cadaveric study [38]. The study suggested that thickening of the wall does not necessarily lead to the luminal narrowing, what was confirmed by the Liem et al. [39]. The technique has been used to evaluate the condition of small subcortical vessels, particularly vulnerable in the aging process [29].

Many different protocols were used by different authors to perform 7 T ToF-MRA (Table 1). Protocol modifications are still introduced in order to overcome acquisition time and specific absorption rate (SAR) limitations. Despite the report that longer repetition time (TR) and larger flip angle (FA) had better visualization for small vessels with slow-flowing blood [12],

Zhang et al. chose TR = 20 ms and FA = 18° in order to limit the total acquisition time to 10 min and avoid motion artifacts in clinical scans [40].

To achieve the SAR limits and acquisition time Maderwald et al. reduced the echo time to the minimum, the flip angle was chosen as large as possible. According to the authors a shorter TR improves background suppression but could not be achieved without sacrificing coverage or exceeding the SAR. A scan time of less than 15 min per sequence is tolerable, however, one need to aim for shorter acquisition time in order to decrease the motion artifacts and achieve better image quality [33]. von Morze et al. reports that extending TR by 50% increases the acquisition time by 50% and doubling the resolution results with 100% longer acquisition time. Protocol presented by the authors seem to be more efficient allowing high quality imaging of smaller peripheral vessels and significant improvement in contrast-to-noise ratio (CNR) in small perforating cerebral vessels. Increased TR and FA resulted in reduced saturation of slow-flowing blood which was highly beneficial for the vessel-tissue contrast, however authors noted that increasing the resolution does not necessarily reduce contrast in subvoxel dimensions [12].

Ultra-high field MRA because of the longer T1-relaxation time requires longer TR, providing better contrast between the inflow blood and rest of the tissue, however one can enhance the blood-tissue contrast by applying a magnetization transfer contrast pulse (MTC), which selectively suppress tissues with significant water-macromolecule interactions or saturation radio frequency (RF) pulses. Saturation pulses involve the application of RF energy to suppress the MR signal from moving tissues outside the imaged volume in order to reduce or eliminate motion artifacts. Spatial Saturation Pulses are based around a spatially selective 90°-pulse that flips magnetization into the transverse plane, which surpasses venous flow. Wrede et al. presented the modified technique of saturation RF pulses. They reduced the flip angle of the saturation RF pulse to 35° instead of 90°, which is normally used. That helped to reduce the SAR of individual saturation pulse instead of reducing the number of saturation pulses [32]. Applying the VERSE algorithm [41,42] allowed to reduce the acquisition time almost 3 times but TR had to be increased from 20 ms to 56 ms because of the SAR limitations [32]. Johst et al. on the other hand showed that despite the reduction of saturation pulse flip angle, the pulse can be applied every TR using a TR as short as 20 ms concluding that only half or less of the flip angle is necessary. This technique helped to stay within the SAR limitations and reach acceptable imaging time [43]. Schmitter et al. claim that specially adapted variable-rate selective pulses also allow for suppression of venous signal [42].

Another important factor in visualizing small vessels in ultra-high resolution is proper RF coil selection. The 8-channel coil with a sensitivity-encoding (SENSE) seems to be proper for ToF-MRA purposes [44,45], however, Kang et al. were not satisfied with the image quality and empirically chose volume coil [8] and von More et al. used the unique phased array coil, which consisted of smaller elements, giving higher peripheral sensitivity [12]. Maderwald et al. came to a conclusion that a 24-channel head coil has shown promising results, ensuring increased small vessel visualization in the periphery of the

brain. They also claim that new multi-channel coils might offer a solution for overcoming the SAR limitations, thus improving imaging quality by increasing the signal in the brain periphery [31,33].

Neumann et al. presented a modification in high-resolution TOF sequences, reconstructing the cerebral vasculature by vessel segmentation and converting it into a topological and spatial model, through injecting a simulated dye by iteratively applying the laws of diffusion to the data set.

This technique can be helpful while planning surgeries such as tumor or epilepsy procedures as well as finding a potential vessel occlusion in a hypo-refused area.

There are several challenges in ultra-high MRA that one need overcome in order to achieve good quality images. Several studies report that there is no advantage in visualizing main cerebral vessels between 3 T and 7 T MRA [31]. Because of the RF inhomogeneity properties at ultra-high field there are regions that suffer from a signal loss like the carotid siphon and basilar artery. Additionally higher spatial resolution results with decreasing in signal intensity. In the study performed by Maderwald et al. turbulence artifacts and intraluminal signal loss were found in the greater vessels (mostly in carotid arteries), when using ToF-MRA and VIBE protocol but nearly absent, when using MPRAGE, however in ToF-MRA this can be partially compensated by MIPs [33]. They also report that ToF-MRA requires greater flip angles than VIBE and MPRAGE, which makes it more vulnerable to SAR restriction, moreover ToF requires longer acquisition time which can lead to subject motion artifacts. MPRAGE protocol additionally allows good visualization and differentiation of gray and white brain parenchyma, which is not possible using ToF-MRA.

5. Conclusions

Ultra-high field ToF-MRA has found to be a superior method in depicting cerebral microvasculature. The method showed additional higher order branches and smaller perforating branches, that were not visualized in low-field MRI. 7 T ToF-MRA seems to be a reliable method for visualization of arteries up to the second order cerebral arteries and has a potential to soon replace DSA. This method still needs further research in order to improve imaging speed and develop techniques allowing to enhance blood-tissue contrast and reaching the SAR limitation at the same time. Parallel imaging with multi receiver coil arrays could enable a more homogenous signal over the entire head. High-field ToF-MRA may be helpful in increasing understanding of the patterns in anatomy in vivo, ischemic processes, diagnosing cerebral vessel malformations and planning neurosurgical procedures.

Ethics

The work described in this article has been carried out in accordance with The Code of Ethics of the World Medical Association (Declaration of Helsinki) for experiments involving humans; Uniform Requirements for manuscripts submitted to Biomedical Journals.

Conflict of interest

None declared.

Acknowledgement and financial support

None declared.

REFERENCES

- [1] Suryan G. A time-of-flight method. *Proc Indian Acad Sci Sect 1959*;A33:107.
- [2] Hinshaw WS, Bottomley PA, Holland GN. Radiographic thin section image of the human wrist by nuclear magnetic resonance. *Nature* 1977;270:272-3.
- [3] Gibbs GF, Huston 3rd J, Bernstein MA, Riederer SJ, Brown Jr RD. 3.0-Tesla MR angiography of intracranial aneurysms: comparison of time-of-flight and contrast-enhanced techniques. *J Magn Reson Imaging* 2005;21:97-102.
- [4] Gibbs GF, Huston 3rd J, Bernstein MA, Riederer SJ, Brown Jr RD. Improved image quality of intracranial aneurysms: 3.0-T versus 1.5-T time-of-flight MR angiography. *AJNR Am J Neuroradiol* 2004;25:84-7.
- [5] Suarez JJ, Tarr RW, Selman WR. Aneurysmal subarachnoid hemorrhage. *N Engl J Med* 2006;354:387-96.
- [6] Yamada I, Matsushima Y, Suzuki S. Moyamoya disease: diagnosis with three-dimensional time-of-flight MR angiography. *Radiology* 1992;184:773-8.
- [7] Fushimi Y, Miki Y, Kikuta K, Okada T, Kanagaki M, Yamamoto A, et al. Comparison of 3.0- and 1.5-T three-dimensional time-of-flight MR angiography in moyamoya disease: preliminary experience. *Radiology* 2006;239:232-7.
- [8] Kang CK, Park CW, Han JY, Kim SH, Park CA, Kim KN, et al. Imaging and analysis of lenticulostriate arteries using 7.0-Tesla magnetic resonance angiography. *Magn Reson Med* 2009;61(1):136-44.
- [9] Cho ZH, Kang CK, Han JY, Kim SH, Kim KN, Hong SM, et al. Observation of the lenticulostriate arteries in the human brain in vivo using 7.0 T MR angiography. *Stroke* 2008;39(5):1604-6.
- [10] Zwanenburg JJ, Hendrikse J, Takahara T, Visser F, Luijten PR. MR angiography of the cerebral perforating arteries with magnetization prepared anatomical reference at 7 T: comparison with time-of-flight. *J Magn Reson Imaging* 2008;28(6):1519-26.
- [11] Willinek WA, Born M, Simon B, Tschampa HJ, Krautmacher C, Gieseke J, et al. Time-of-flight MR angiography: comparison of 3.0-T imaging and 1.5-T imaging - initial experience. *Radiology* 2003;229(3):913-20.
- [12] von Morze C, Xu D, Purcell DD, Hess CP, Mukherjee P, Saloner D, et al. Intracranial time-of-flight MR angiography at 7 T with comparison to 3 T. *J Magn Reson Imaging* 2007;26:900-4.
- [13] Balduf LM, Langsfeld M, Marek JM, Tullis MJ, Kasirajan K, Matteson B. Complication rates of diagnostic angiography performed by vascular surgeons. *Vasc Endovasc Surg* 2002;36:439-45.
- [14] Young N, Chi KK, Ajaka J, McKay L, O'Neill D, Wong KP. Complications with outpatient angiography and interventional procedures. *Cardiovasc Interv Radiol* 2002;25:123-6.
- [15] Miller DL, Balter S, Cole PE, Lu HT, Schueler BA, Geisinger M, et al. Radiation doses in interventional radiology procedures: the RAD-IR study: part I: overall measures of dose. *J Vasc Interv Radiol* 2003;14:711-27.
- [16] Anzalone N, Scotti R, Iadanza A. MR angiography of the carotid arteries and intracranial circulation: advantage of a high relaxivity contrast agent. *Neuroradiology* 2006;48 (Suppl. 1):9-17.
- [17] Meckel S, Mekle R, Taschner C, Haller S, Scheffler K, Raude EW, et al. Time-resolved 3D contrast-enhanced MRA with GRAPPA on a 1, 5-T system for imaging of craniocervical vascular disease: initial experience. *Neuroradiology* 2006;48:291-9.
- [18] Chakeres DW, Kangarlu A, Boudoulas H, Young DC. Effect of static magnetic field exposure of up to 8 Tesla on sequential human vital sign measurements. *J Magn Reson Imaging* 2003;18:346-52.
- [19] Chakeres DW, Bornstein R, Kangarlu A. Randomized comparison of cognitive function in humans at 0 and 8 Tesla. *J Magn Reson Imaging* 2003;18:342-5.
- [20] Kraff O, Wrede KH, Schoemberg T, Dammann P, Nouredine Y, Orzada S, et al. MR safety assessment of potential RF heating from cranial fixation plates at 7 T. *Med Phys* 2013;40:042302.
- [21] Nouredine Y, Kraff O, Ladd ME, Schaeffers G, Wrede KH, Bitz AK. RF safety of aneurysm clips at 7 Tesla: effect of field polarization. *Proc Int Soc Mag Reson Med (ISMRM)* 2012;20:2767.
- [22] Nouredine Y, Kraff O, Ladd ME, Schaeffers G, Wrede KH, Bitz AK. In silico and in vitro investigation of temperature elevation close to an aneurysm clip at 7 T. *ISMRM 21st Annual Meeting & Exhibition*; 2013. p. 4416.
- [23] Stamm AC, Wright CL, Knopp MV, Schmalbrock P, Heverhagen JT. Phase contrast and time-of-flight magnetic resonance angiography of the intracerebral arteries at 1.5, 3 and 7 T. *Magn Reson Imaging* 2013;31:545-9.
- [24] Nowinski WL, Puspitasari F, Volkau I, Marchenko Y, Knopp MV. Comparison of magnetic resonance angiography scans on 1.5, 3, and 7 Tesla units: a quantitative study of 3-dimensional cerebrovasculature. *J Neuroimaging* 2011. <http://dx.doi.org/10.1111/j.1552-6569.2011.00597.x>
- [25] Wermer MJH, van Walderveen MAA, Garpebring A, van Osch MJP. 7 Tesla MRA for the differentiation between intracranial aneurysms and infundibula. *Magn Reson Imaging* 2016;37:16-20. <http://dx.doi.org/10.1016/j.mri.2016.11.006>
- [26] Oh BH, Moon HC, Baek HM, Lee YJ, Kim SW, Jeon YJ, et al. Comparison of 7 T and 3 T MRI in patients with moyamoya disease. *Magn Reson Imaging* 2017;37:134-8. <http://dx.doi.org/10.1016/j.mri.2016.11.006>
- [27] Kang CK, Park CW, Han JY, Kim SH, Park CA, Kim KN, et al. Imaging and analysis of lenticulostriate arteries using 7.0-Tesla magnetic resonance angiography. *Magn Reson Med* 2009;61:136-44.
- [28] Kang CK, Park CA, Park CW, Lee YB, Cho ZH, Kim YB. Lenticulostriate arteries in chronic stroke patients visualised by 7 T magnetic resonance angiography. *J Stroke* 2010;5(October):374-80. <http://dx.doi.org/10.1111/j.1747-4949.2010.00464.x>
- [29] Laurig M, Liu X, Wyss M, Gietl A, Jellestad L, Nitsch RM, et al. Quantification of subcortical gray-matter vascularization using 7 Tesla time-of-flight angiography. *Brain Behav* 2013;3(5):515-8. <http://dx.doi.org/10.1002/brb3.154>
- [30] Conijn MM, Hendrikse J, Zwanenburg JJ, Takahara T, Geerlings MI, Mali WP, et al. Perforating arteries originating from the posterior communicating artery: a 7.0-Tesla MRI study. *Eur Radiol* 2009;19:2986-92.
- [31] Heverhagen JT, Bourekas E, Sammet S, Knopp MV, Schmalbrock P. Time-of-flight magnetic resonance angiography at 7 Tesla. *Investig Radiol* 2008;43:568-73.
- [32] Wrede KH, Dammann P, Mönninghoff C, Johst S, Maderwald S, Sandalcioğlu IE, et al. Non-enhanced MR

- imaging of cerebral aneurysms: 7 Tesla versus 1.5 Tesla. *PLOS ONE* 2014;9:e84562.
- [33] Maderwald S, Ladd SC, Gizewski ER, Kraff O, Theysohn JM, Wicklow K, et al. To TOF or not to TOF: strategies for non-contrast-enhanced intracranial MRA at 7 T. *MAGMA* 2008;21:159-67.
- [34] Deng X, Zhang Z, Zhang Y, Zhang D, Wang R, Ye X, et al. Comparison of 7.0- and 3.0-T MRI and MRA in ischemic-type moyamoya disease: preliminary experience. *J Neurosurg* 2016;124:1716-25.
- [35] Mizushima H, Kobayashi N, Yoshiharu S, Kazuo H, Dohi K, Sasaki K, et al. Aneurysm of the distal anterior inferior cerebellar artery at the medial branch: a case report and review of the literature. *Surg Neurol* 1999;52:137-42.
- [36] Vieco PT, Shuman WP, Alsofrom GF, Gross CE. Detection of Circle of Willis aneurysms in patients with acute subarachnoid hemorrhage: a comparison of CT angiography and digital subtraction angiography. *AJR Am J Roentgenol* 1995;165:425-30.
- [37] Anzalone N, Triulzi F, Scotti G. Acute subarachnoid haemorrhage: 3D time-of-flight MR angiography versus intra-arterial digital angiography. *Neuroradiology* 1995;37:257-61.
- [38] Miao Q, Paloneva T, Tuisku S, Roine S, Poyhonen M, Viitanen M, et al. Arterioles of the lenticular nucleus in CADASIL. *Stroke* 2006;37:2242-7.
- [39] Liem MK, Grond J, Versluis M, Haan J, Webb AG, Ferri MD, et al. Lenticulostriate arterial lumina are normal in cerebral autosomal-dominant arteriopathy with subcortical infarcts and leukoencephalopathy a high-field in vivo MRI. *Study Stroke* 2010;41(October):2812-6. <http://dx.doi.org/10.1161/STROKEAHA.110.586883>
- [40] Zhang Z, Deng X, Weng D, Ann J, Zuo Z, Wang B, et al. Segmented TOF at 7 T MRI: technique and clinical applications. *Magn Reson Imaging* 2015;33:1043-50.
- [41] Conolly S, Nishimura D, Macovski A, Glover G. Variable-rate selective excitation. *J Magn Reson Imaging* 1988;78:440-58.
- [42] Schmitter S, Bock M, Johst S, Auerbach EJ, Uğurbil K, Van de Moortele PF. Contrast enhancement in TOF cerebral angiography at 7 T using saturation and MT pulses under SAR constraints: impact of VERSE and sparse pulses. *Magn Reson Med* 2012;68:188-97.
- [43] Johst S, Wrede KH, Ladd ME, Maderwald S. Time-of-flight magnetic resonance angiography at 7 T using venous saturation pulses with reduced flip angles. *Investig Radiol* 2012;47:445-50.
- [44] Ladd ME. High-field-strength magnetic resonance: potential and limits. *Top Magn Reson Imaging* 2007;18:139-52.
- [45] Zwanenburg JJ, Visser F, Takahara T, Hendrikse J, Luijten P. Imaging of lenticulostriate arteries at 7 Tesla. *Proceedings of the 16th Annual Meeting of ISMRM*; 2008. p. 472.
- [46] von Morze C, Purcell DD, Banerjee S, Xu D, Mukherjee P, Kelley DA, et al. High-resolution intracranial MRA at 7T using autocalibrating parallel imaging: initial experience in vascular disease patients. *Magn Reson Imaging* 2008;26(10):1329-33. <http://dx.doi.org/10.1016/j.mri.2008.04.002>
- [47] Hartevelde AA, De Cocker LJJ, Dieleman N, van der Kolk AG, Zwanenburg JJM, Robe PA, et al. High-resolution postcontrast time-of-flight MR angiography of intracranial perforators at 7.0 Tesla. *PLoS ONE* 2015;10(3):e0121051. <http://dx.doi.org/10.1371/journal.pone.0121051>
- [48] Neumann JO, Giese H, Nagel AM, Biller A, Unterberg A, Meinzer HP. MR angiography at 7T to visualize cerebrovascular territories. *J Neuroimaging* 2016;26(5):519-24. <http://dx.doi.org/10.1111/jon.12348>
- [49] Matsushige T, Kraemer M, Schlamann M, Berlit P, Forsting M, Ladd ME. Ventricular microaneurysms in moyamoya angiopathy visualized with 7T MR angiography. *AJNR Am J Neuroradiol* 2016;37(9):1669-72. <http://dx.doi.org/10.3174/ajnr.A4786>