



Delayed onset of Takotsubo syndrome after epileptic seizure

Claudia Stöllberger, Josef Finsterer

Krankenanstalt Rudolfstiftung, Juchgasse 25, A-1030 Vienna, Austria

Key words: midventricular ballooning, neurogenic stunned myocardium
(*Neurol Neurochir Pol* 2019; 53 (1): 95–97)

Introduction

Takotsubo syndrome (TTS) is characterised by transient systolic left ventricular dysfunction. Its clinical presentation, electrocardiography (ECG) findings, and biomarker profiles are often similar to those of an acute coronary syndrome [1]. TTS predominantly affects elderly women and is often preceded by emotional or physical stress [1]. Epileptic seizures as triggering events of TTS have to date been described in nearly 100 cases [2, 3]. The temporal association between epileptic seizure and onset of TTS is frequently unknown due to postictal somnolence or lack of cardiologic surveillance after a seizure. Here we describe a patient who developed TTS only 48 hours after a witnessed epileptic seizure. This case report required no ethical approval because the data was collected retrospectively. The patient was informed that her case was being observed in terms of a scientific observation and she accepted the fact that her case would be described.

Case report

A 67 year-old Caucasian female, height 165 cm, weight 70 kg, was admitted because of three generalised, tonic-clonic seizures having occurred on the day of admission. She had a history of childhood onset epilepsy of generalised type starting at the age of 12 years which had not been well controlled due to poor adherence. Furthermore, she had a ten year history of arterial hypertension, pneumonia at age 26 and again at age 57, a fall-induced fracture of the humerus at age 62, and a bilateral ovariectomy because of benign cysts at age 66. In the four weeks prior to admission she had felt increasingly weak and had suffered several falls. She was on medication of lamotrigine 500 mg/d (for epilepsy), clonazepam 2 mg/d (for

epilepsy), primidone 375 mg/d (for tremor), folic acid 5 mg/d, acetylsalicylic acid 100 mg/d and nebivolol 1.25 mg/d. She admitted that she had failed to take the medications according to the prescription on the days before admission.

On admission, she did not complain of cardiac or respiratory symptoms. Blood pressure was 104/70 mm Hg and heart rate 104/min. Clinical cardiologic investigation did not disclose any abnormalities. The electrocardiogram (ECG) was normal except for sinus tachycardia (Fig. 1).

Blood tests showed hyponatremia, creatine kinase levels within the normal range, and an elevated troponin T level (Tab. 1). Clinical neurological exam on admission revealed deviation nystagmus, dysarthria, dyspraxia, hearing impairment, and postural tremor.

Electroencephalography revealed spikes in the frontal projections bilaterally. Magnetic resonance of the brain revealed a patchy T2-hyperintensity in the right parietal projection and multiple spot-like T2-hyperintensities, which were hypointense on T2-weighted images. Neuropsychological investigations revealed mild cognitive impairment (MMSE 25).

Over the following 24 hours, troponin levels decreased, CK levels increased slightly, and NT-pro-BNP levels were elevated (Tab. 1). 48 hours after admission, the patient complained for the first time of anginal chest pain. ECG, which had been normal on admission, now showed negative T waves and a prolonged QT interval (Fig. 1). Since a non-ST-elevation myocardial infarction was suspected, the patient received a loading dose of 600 mg clopidogrel, followed by clopidogrel 75 mg/d. Coronary angiography, carried out four days after the seizure and two days after the onset of chest pain, showed normal coronary arteries and midventricular ballooning, suggesting the diagnosis of TTS. Echocardiography after seven days showed normalisation of regional wall motion, a normal

Address for correspondence: Claudia Stöllberger, Krankenanstalt Rudolfstiftung, Juchgasse 25, A-1030 Wien, Austria, e-mail: claudia.stoellberger@chello.at

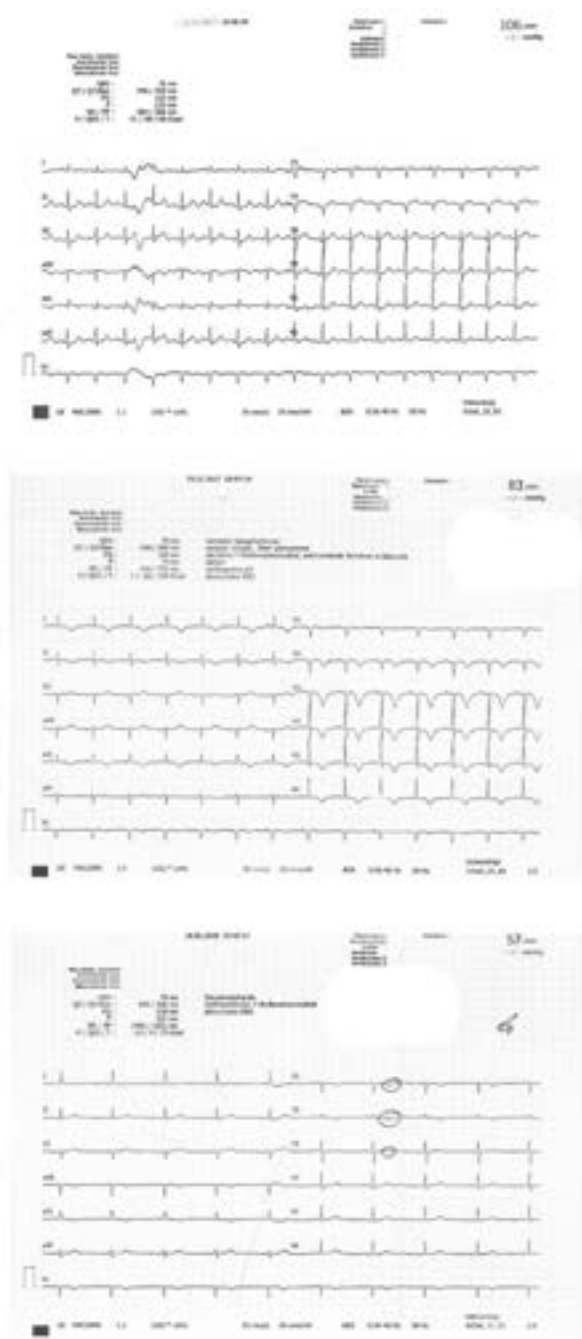


Figure 1. Electrocardiographic recordings immediately after the seizure (A), after 48 hours (B), and after 26 days (C). Whereas the initial ECG was normal, T-wave inversion was pronounced after 48 hours, and slightly visible after 26 days

systolic function, moderate (grade II) aortic regurgitation, and minimal mitral regurgitation. Since the patient showed symptoms of depression, antidepressive therapy was started. The patient was discharged with lamotrigine 400 mg/d, primidone 125 mg/d, clonazepam 3 mg/d, nebulolol 2.5 mg/d, acetylsalicylic acid 100 mg/d, valproic acid 1,500 mg/d, atorvastatin

40 mg/d, escitalopram 10 mg/d and mirtazapine 15 mg/d. One day after discharge, blood was taken to measure antiepileptic drug levels. Serum valproic level was 723 $\mu\text{mol/L}$ (therapeutic range 350–700 $\mu\text{mol/L}$) and serum lamotrigine level was > 17.5 $\mu\text{mol/L}$ (therapeutic range 2–10 $\mu\text{mol/L}$). Consequently, the antiepileptic therapy was modified by the treating neurologist. After 26 days, the ECG showed only slight negative T waves in leads V1–V3 and normalisation of the QT interval. At follow-up after 11 months, the patient did not report any cardiac symptoms. No epileptic seizures had occurred in the mean time. She is at present on antiepileptic medication with levetiracetam 3,000 mg/d.

Discussion

The most probable trigger for TTS in the presented patient was the epileptic seizure, since no other physical or emotional triggering events were detected. Why chest pain occurred only two days after the seizures remains unknown. The mechanism of the delay between seizure and TTS may be related to autonomic instability or more prolonged catecholamine release despite seizure control. Alternatively, it is possible that clinically silent seizures continued despite apparent resolution.

To date, the pathogenesis of TTS has not been completely clarified [1]. Elevated catecholamine levels seem to play an important role. In patients with an epileptic seizure, a significant increase in both plasma norepinephrine and epinephrine levels has been observed due to abnormal cerebral discharges [4]. Elevated serum catecholamine levels have been only described in two epilepsy-associated TTS cases to date [5, 6].

The negative T-waves in the ECG, together with chest pain and elevated troponin levels, led to the decision to perform coronary angiography and thus to the diagnosis of midventricular TTS. Negative T-waves in TTS are assumed to be due to myocardial oedema. This assumption is based on clinical observations such as the parallel time course of development and resolution of ventricular repolarisation abnormalities and myocardial oedema on initial and follow-up cardiac magnetic resonance images [7].

Interestingly, troponin was elevated on admission, although the patient showed no signs of myocardial ischaemia, neither clinically nor in the ECG at that time. Troponin elevations have been reported to occur in 6–12% of cases after epileptic seizures [8–10]. It is assumed that seizures lead to simultaneous increases in pulmonary and systemic resistance, hypoxemia, and catecholamine release, thus inducing myocardial damage [8]. Unfortunately, the ECG findings of patients from two of these series are not completely reported, thus it cannot be assessed how many of them eventually developed TTS [8, 9]. In the third study, however, the patients were investigated cardiologically more extensively and TTS was diagnosed in 27% of the troponin-positive patients [10].

Unfortunately, no serum levels of lamotrigine were assessed when the patient was admitted, but only after discharge.

Table 1. Results of blood tests of patient with seizure-associated Takotsubo syndrome

Parameter (normal range)	Admission	Day 1	Day 2	Day 3	Day 5
Leucocytes (4.0–9.0 g/L)	9.8	8.2	NM	NM	5.6
Erythrocytes (4.00–5.20 T/L)	4.37	3.08	NM	NM	12.3
Sodium (136–145 mmol/L)	133	128	NM	NM	125
Potassium (3.4–4.5 mmol/L)	4.4	4.2	NM	NM	4.2
Creatinine (0.50–0.90 mg/dL)	0.79	0.69	NM	NM	0.60
Creatinine kinase (< 170 U/L)	164	177	131	97	91
Troponin T (< 14 ng/L)	278	NM	109	82	28
NT-pro-BNP (< 285)	NM	2,608	NM	NM	NM
Cholesterol (< 200 mg/dL)	NM	160	NM	NM	NM
HDL-cholesterol (> 65 mg/dL)	NM	80	NM	NM	NM
LDL-cholesterol (< 130 mg/dL)	NM	68	NM	NM	NM
Haemoglobin A1C (4–6%)	NM	5.6	NM	NM	NM

NM — not measured

Thus, it cannot be assessed if TTS was encouraged by lamotrigine overdose, which is known to affect the cardiac conduction system [11]. TTS in epileptic patients, however, occurs also in patients without antiepileptic therapy, thus it cannot be explained exclusively as a side effect of antiepileptic drugs [2, 3].

From these findings and our case we conclude that TTS should be considered as a complication of epileptic seizures. Due to the fact that after epileptic seizures patients do not typically experience symptoms of angina pectoris or dyspnoea, TTS can easily be overlooked. After an epileptic seizure, an ECG and an assessment of troponin levels should be carried out. Where troponin is elevated, cardiological surveillance is recommended including a follow-up ECG, an assessment of brain natriuretic peptides, and echocardiography. Cases with wall motion abnormalities or ECG abnormalities should undergo coronary angiography.

References

- Lyon AR, Bossone E, Schneider B, et al. Current state of knowledge on Takotsubo syndrome: a Position Statement from the Taskforce on Takotsubo Syndrome of the Heart Failure Association of the European Society of Cardiology. *Eur J Heart Fail.* 2016; 18(1): 8–27, doi: [10.1002/ejhf.424](https://doi.org/10.1002/ejhf.424), indexed in Pubmed: [26548803](https://pubmed.ncbi.nlm.nih.gov/26548803/).
- Finsterer J, Bersano A. Seizure-triggered Takotsubo syndrome rarely causes SUDEP. *Seizure.* 2015; 31: 84–87, doi: [10.1016/j.seizure.2015.07.015](https://doi.org/10.1016/j.seizure.2015.07.015), indexed in Pubmed: [26362382](https://pubmed.ncbi.nlm.nih.gov/26362382/).
- Belcour D, Jabot J, Grard B, et al. Prevalence and Risk Factors of Stress Cardiomyopathy After Convulsive Status Epilepticus in ICU Patients. *Crit Care Med.* 2015; 43(10): 2164–2170, doi: [10.1097/CCM.0000000000001191](https://doi.org/10.1097/CCM.0000000000001191), indexed in Pubmed: [26237133](https://pubmed.ncbi.nlm.nih.gov/26237133/).
- Simon RP, Aminoff MJ, Benowitz NL. Changes in plasma catecholamines after tonic-clonic seizures. *Neurology.* 1984; 34(2): 255–257, indexed in Pubmed: [6538024](https://pubmed.ncbi.nlm.nih.gov/6538024/).
- Sakuragi S, Tokunaga N, Okawa K, et al. A case of takotsubo cardiomyopathy associated with epileptic seizure: reversible left ventricular wall motion abnormality and ST-segment elevation. *Heart Vessels.* 2007; 22(1): 59–63, doi: [10.1007/s00380-006-0931-3](https://doi.org/10.1007/s00380-006-0931-3), indexed in Pubmed: [17285449](https://pubmed.ncbi.nlm.nih.gov/17285449/).
- Shimizu M, Kagawa A, Takano T, et al. Neurogenic stunned myocardium associated with status epilepticus and postictal catecholamine surge. *Intern Med.* 2008; 47(4): 269–273, indexed in Pubmed: [18277028](https://pubmed.ncbi.nlm.nih.gov/18277028/).
- Migliore F, Zorzi A, Perazzolo Marra M, et al. Myocardial edema as a substrate of electrocardiographic abnormalities and life-threatening arrhythmias in reversible ventricular dysfunction of takotsubo cardiomyopathy: Imaging evidence, presumed mechanisms, and implications for therapy. *Heart Rhythm.* 2015; 12(8): 1867–1877, doi: [10.1016/j.hrthm.2015.04.041](https://doi.org/10.1016/j.hrthm.2015.04.041), indexed in Pubmed: [25937439](https://pubmed.ncbi.nlm.nih.gov/25937439/).
- Nass RD, Meiling S, Andrié RP, et al. Laboratory markers of cardiac and metabolic complications after generalized tonic-clonic seizures. *BMC Neurol.* 2017; 17(1): 187, doi: [10.1186/s12883-017-0965-4](https://doi.org/10.1186/s12883-017-0965-4), indexed in Pubmed: [28927394](https://pubmed.ncbi.nlm.nih.gov/28927394/).
- Chatzikonstantinou A, Ebert AD, Hennerici MG. Temporal seizure focus and status epilepticus are associated with high-sensitive troponin I elevation after epileptic seizures. *Epilepsy Res.* 2015; 115: 77–80, doi: [10.1016/j.eplepsyres.2015.05.013](https://doi.org/10.1016/j.eplepsyres.2015.05.013), indexed in Pubmed: [26220381](https://pubmed.ncbi.nlm.nih.gov/26220381/).
- Schneider F, Kadel C, Pagitz M, et al. Takotsubo cardiomyopathy and elevated troponin levels following cerebral seizure. *Int J Cardiol.* 2010; 145(3): 586–587, doi: [10.1016/j.ijcard.2010.05.072](https://doi.org/10.1016/j.ijcard.2010.05.072), indexed in Pubmed: [20580097](https://pubmed.ncbi.nlm.nih.gov/20580097/).
- Chavez P, Casso Dominguez A, Herzog E. Evolving Electrocardiographic Changes in Lamotrigine Overdose: A Case Report and Literature Review. *Cardiovasc Toxicol.* 2015; 15(4): 394–398, doi: [10.1007/s12012-014-9300-0](https://doi.org/10.1007/s12012-014-9300-0), indexed in Pubmed: [25448877](https://pubmed.ncbi.nlm.nih.gov/25448877/).