




Small vessel disease in primary familial brain calcification with novel truncating PDGFB variants

Maha Yektay Farahmand^{1,2}, Johan Wasselius³, Elisabet Englund⁴, Irwin Braverman⁵,
Andreas Puschmann^{1,2,6}, Andreea Ilinca^{1,2} 

¹Division of Neurology, Department for Clinical Sciences, Lund University, Lund, Sweden

²Department of Neurology, Skåne University Hospital, Malmö, Sweden

³Section of Neuroradiology, Skåne University Hospital, Lund, Sweden

⁴Division of Pathology, Department of Clinical Sciences, Lund University, Lund, Sweden

⁵Department of Dermatology, Yale University Medical School, New Haven, Connecticut, USA

⁶SciLifeLab National Research Infrastructure, Sweden

ABSTRACT

Introduction. Primary familial brain calcification (PFBC) is a neurodegenerative disease characterised by bilateral calcification in the brain, especially in the basal ganglia, leading to neurological and neuropsychiatric manifestations. White matter hyperintensities (WMH) have been described in patients with PFBC and pathogenic variants in the gene for platelet-derived growth factor beta polypeptide (PDGFB), suggesting a manifest cerebrovascular process. We present below the cases of two PFBC families with *PDGFB* variants and stroke or transient ischaemic attack (TIA) episodes. We examine the possible correlation between PFBC and vascular events as stroke/TIA, and evaluate whether signs for vascular disease in this condition are systemic or limited to the cerebral vessels.

Material and methods. Two Swedish families with novel truncating *PDGFB* variants, p.Gln140* and p.Arg191*, are described clinically and radiologically. Subcutaneous capillary vessels in affected and unaffected family members were examined by light and electron microscopy.

Results. All mutation carriers showed WMH and bilateral brain calcifications. The clinical presentations differed, with movement disorder symptoms dominating in family A, and psychiatric symptoms in family B. However, affected members of both families had stroke, TIA, and/or asymptomatic intracerebral ischaemic lesions. Only one of the patients had classical vascular risk factors. Skin microvasculature was normal.

Conclusions. Patients with these *PDGFB* variants develop microvascular changes in the brain, but not the skin. *PDGFB*-related small vessel disease can manifest radiologically as cerebral haemorrhage or ischaemia, and may explain TIA or stroke in patients without other vascular risk factors.

Keywords: stroke, TIA, idiopathic basal ganglia calcification-5, Mendelian inheritance in man number 615483, cerebral small vessel disease, microbleeds, genetic diseases

(*Neurol Neurochir Pol* 2024; 58 (1): 94–105)

Introduction

Pathogenic variants in the *PDGFB* gene, encoding for platelet-derived growth factor B, are one of several known

causes of primary familial brain calcification (PFBC), also known as Fahr's disease/syndrome or idiopathic basal ganglia calcification. PFBC is characterised by abnormal peri-microvascular calcium deposition in the brain [1–4]. The typical

Address for correspondence: Andreea Ilinca, MD, PhD, Department of Neurology, Skåne University Hospital, Jan Waldenströms gata 15, 20502, Malmö, Sweden; e-mail: andreea.ilinca@med.lu.se

Received: 06.10.2023 Accepted: 08.12.2023 Early publication date: 29.12.2023

This article is available in open access under Creative Common Attribution-Non-Commercial-No Derivatives 4.0 International (CC BY-NC-ND 4.0) license, allowing to download articles and share them with others as long as they credit the authors and the publisher, but without permission to change them in any way or use them commercially.

radiological findings are bilateral calcifications in the basal ganglia, and sometimes also in the thalamus, cerebellum, subcortical white matter, or other brain regions, in computed tomography (CT) images [4]. Currently, pathogenic variants in *SLC20A2*, *PDGFRB*, *PDGFB*, *XPRI*, *MYORG*, *JAM2*, and *CMPK2* are known to be genetic causes of PFBC [5]. White matter hyperintensities, presumably of vascular origin, have previously been described in PFBC patients with *SLC20A2* [6], *PDGFRB* [7] and *PDGFB* [8–10] variants, and have been explained by the impairment of pericyte recruitment during angiogenesis leading to vascular dysfunction [8, 11]. One previous study has reported alterations in the architecture of extracerebral blood vessels of one patient with PFBC and a pathogenic *PDGFB* variant [8].

A limited number of patients with PFBC have been reported to have ischaemic or haemorrhagic stroke, transient ischaemic attacks (TIA), and/or intracerebral aneurysms [12–18]. However, these are not considered typical or common clinical events in PFBC. The typical manifestations of PFBC are usually progressive symptoms such as parkinsonism, cerebellar symptoms, cognitive impairment, seizures, migraine, and psychiatric disorders [19].

Clinical rationale for the study

Our study aimed to investigate the clinical significance of white matter changes seen in patients with PFBC caused by *PDGFB* variants and to describe two families with novel truncating *PDGFB* variants.

Material and methods

Patient group and clinical data

Two unrelated index patients (one from family A and one from family B) with clinically manifest PFBC caused by probably pathogenic variants in the *PDGFB* gene, were identified at the Department of Neurology, Skane University Hospital in Lund, Sweden. Additional aetiologies for secondary intracranial calcification, including conditions such as hypercalcaemia and hyperparathyroidism, were excluded. The patients, as well as their symptomatic and asymptomatic family members, were invited to participate in this study. Five affected and two unaffected family members were examined using CT and brain magnetic resonance imaging (MRI), laboratory tests, skin biopsies and genetic analysis (Fig. 1). Clinical records and radiological examinations from two deceased family members were reviewed. We followed family A for eight years and family B for four years. We documented: a) known disease manifestations of PFBC; b) the presence or absence of classical vascular risk factors (i.e. diabetes mellitus, hypertension, heart disease, smoking, hyperlipidemia); c) TIA/stroke episodes; d) other radiological signs of cerebrovascular disease i.e. ischaemic lesions or intracerebral bleeding; and e) any relevant comorbidities or treatments. The occurrence of stereotypies in the index patient (individual III:1) of family A has previously been described [20].

Genetic analyses

Blood samples of the index patients and their available family members were collected and sent to commercial diagnostic laboratories (BGI in Denmark, Centogene in Germany, and BluePrint Genetics in Finland) for genetic testing. Whole exome (WES) or whole genome sequencing (WGS, Illumina) was performed for the index patients, followed by targeted investigation of all known genes related to PFBC.

This revealed two novel variants in the *PDGFB* gene (NM_002608.4): c.418C>T, p.(Gln140*) in family A and c.571C>T p.(Arg191*) in family B. These variants are predicted to introduce a translation termination (stop) codon at amino acid residues 140 respectively 191 and are absent in gnomAD v2.1 (<https://gnomad.broadinstitute.org/>). Other truncating *PDGFB* variants had previously been described as causes of PFBC [9, 21–25], and for this reason both novel variants have been classified as likely to be pathogenic according to the American College of Medical Genetics [26]. The sequenced data was also filtered by using a stroke gene panel for all genes reported to potentially cause monogenic stroke, including stroke related to cerebral small vessel disease [27, 28]. Sanger sequencing was used to examine affected and unaffected relatives.

Pathology

In order to detect possible extracerebral involvement, skin biopsies of 3 mm diameter were obtained from the upper arm of three variant carriers and of one non-carrier from family A. The vascular and microvascular structure of the skin was investigated. From each person, 7–8 sections of skin containing subcutaneous capillary vessels were stained by haematoxylin and eosin and examined using light microscopy and electron microscopy by a pathologist (E.E). The images were reviewed by a dermatologist with specific expertise in interpreting electron microscopy images of the skin (I.B.).

Neuroradiology

Available brain CT scans and MRI data of affected and unaffected family members were analysed in order to assess the presence of basal ganglia calcifications, white matter hyperintensities, and other vascular alterations including ischaemic lesions, cerebral haemorrhages, and aneurysms. Mutation carriers without available brain images underwent a CT scan and a brain MRI. All radiological images were collectively reviewed in collaboration with a neuroradiologist (J.W.). The calcium deposition load on CT scans was quantified using the Total Calcification Score [29] to better compare CT scans of different subjects at different ages.

Review of published cases

We have systematically reviewed all published cases of PFBC caused by pathogenic variants in the *PDGFB* gene (idiopathic basal ganglia calcification-5, Mendelian inheritance in man number 615483). A PubMed literature search

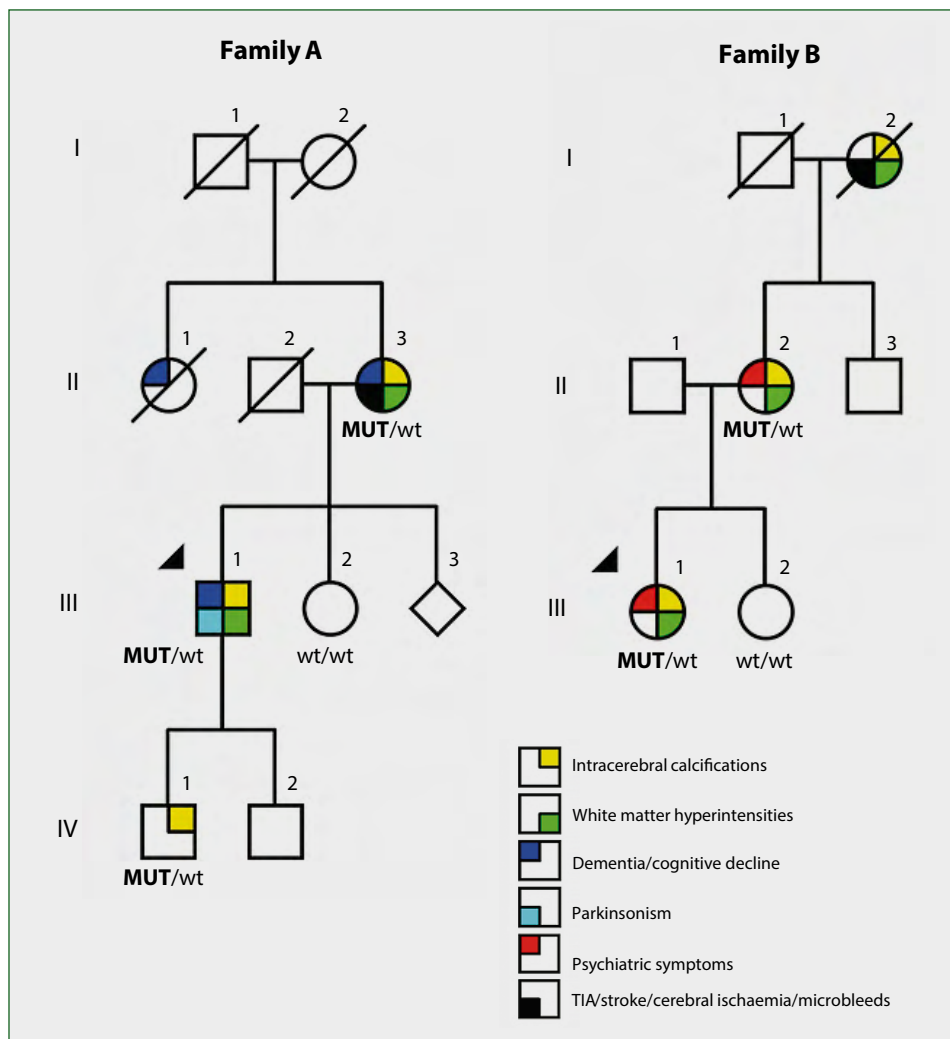


Figure 1. Family pedigrees. Standard symbols are used in pedigree drawings. Round symbols denote females and squares males. MUT – mutation carrier; WT – wild type

was performed for relevant articles, using the following search terms: idiopathic basal ganglia calcification; Fahr’s Disease; *PDGFB* mutations; and white matter hyperintensities. Information on the presence and anatomical location of the brain calcifications, the presence of white matter hyperintensities, and the reported clinical manifestations, was extracted.

Results

Clinical findings

Family A: Four family members were examined clinically, and clinical records were reviewed from a fifth (Fig. 1).

The index patient (III:1) experienced challenges in initiating gait and changing direction at the age of 64 years, which demonstrated improvement upon the administration of levodopa treatment (200 mg daily). Mild cervical dystonia was noted on neurological examination. Two years later, he developed troublesome motor and vocal stereotypies [20] which

partly improved with a small dose of clonazepam. Cognitive testing revealed memory problems and mild cognitive decline when he reached the age of 66. During the eight-year follow up he did not develop any stroke or TIA.

His son (IV:1), when examined at age 45, did not report any clinical complaints; however, a subtle postural tremor was identified during neurological clinical examination conducted as part of our study. He remained clinically unaffected eight years later, despite carrying the same variant in the *PDGFB* gene as his father.

The index patient’s mother (II:3), also carrier of the same *PDGFB* variant, had an episode of sudden weakness in the right half of her face and her right arm, and head drop, at age 57. When examined by a neurologist two hours after onset, these symptoms had improved but mild weakness was documented in her right upper extremity. Over subsequent years, she reported that she had experienced repeated episodes, each lasting for a few minutes, of sensory disturbances or

process, or of malignancies that could otherwise account for her late-onset seizures. Additionally, she had experienced a single ischaemic stroke episode characterised by expressive aphasia. Her clinical neurological examination was otherwise normal. No previous psychiatric symptoms, movement disorders or other neurological deficits were described by her relatives, or mentioned in her medical records.

Family member III: 2 does not carry the genetic variant, and has remained asymptomatic including at the most recent contact.

Neuroradiology

In both families, the *PDGFB* variants co-segregated with the presence of bilateral calcifications in the basal ganglia and with cerebellar white matter hyperintensities of vascular appearance in all the identified mutation carriers (Fig. 1, Tab. 1). The total calcification score calculated for the affected individuals in families A and B is shown in Supplementary Data 1.

Family A: The index patient (III:1) showed extensive calcifications in his basal ganglia, thalamus, and cerebellum on CT, as well as subcortical and cerebellar WMH on MRI. His mother (II:3) and son (VI:1) had similar CT findings, with bilateral calcification at the same locations; MRIs showed WMH which were more prominent in patient II:3 at age 87 and subtle in patient VI:1 at age 45 and 51 (Fig. 2). Examination of patient II:3 with conventional angiography at age 57 revealed a vessel wall irregularity. This was interpreted as an arteriosclerotic plaque in the posterior wall of the right carotid bifurcation that was described as 'minimal'. There were no signs of large vessel disease in the left carotid artery. Renewed examination with conventional angiography at age 61 again showed signs of a mild, non-stenosing plaque in the (right) brachiocephalic artery and now revealed signs of a 'discrete' plaque proximally in the left common carotid artery; there were atherosclerotic vessel wall alterations bilaterally in the carotid siphons that were graded as 'lesser' on the left side and as 'mild to moderate' on the right side.

Family B: CT scans of the index patient (III:1) at age 17 and 23 showed very discrete calcifications in the basal ganglia that became more visible at age 29. The initial MRI scans, at age 16 and 26, showed very subtle white matter hyperintensities bilaterally in the frontal lobe; these became more prominent and visible on MRI at age 27. Her three consecutive CT angiographies revealed no evidence of atherosclerosis or aneurysms. Her mother's (II:2) CTs showed extended bilateral calcifications at the age of 36, and progression of these calcifications 14 years later. Her brain MRIs at age 53 showed bilateral white matter hyperintensities mainly in the frontal lobes, as well as older ischaemic lesions.

Table 1. Summary of genetic, clinical and radiological findings

Family	ID	Age	Sex	Genotype	Symptoms and signs	Classical vascular risk factors (HTN/S/HD/DM/HC)	Calcifications	White matter hyperintensities (MRI)	Ischaemic/haemorrhagic brain lesions	Transient ischaemic attack/stroke
A	II:3	87	F	c.418C>T p.(Gln140*)	Moderate cognitive decline. Recurrent episodes of right-sided weakness and paresthesias (TIAs), Permanent right central facial palsy (stroke)*	N/Y/N/N/Y	Pallidum, putamen, cerebellum	Yes, Fazekas III	N/N	Y/Y*
A	III:1	68	M	c.418C>T p.(Gln140*)	Gait disturbance, blepharospasm, cervical dystonia, vocal tics	N/N/N/N/N	Pallidum, putamen, caudate, thalamus, cerebellum	Yes, Fazekas III	N/N	N/N
A	IV:1	46	M	c.418C>T p.(Gln140*)	None	N/N/N/N/N	Pallidum, putamen, cerebellum	Yes, Fazekas I	N/N	N/N
B	I:2	78	F	c.571C>T p.(Arg191*)	Seizures, expressive aphasia (stroke)	N/N/N/N/N	Pallidum, putamen, parietal and occipital cortex	Yes, Fazekas III	Y/Y	N/Y
B	II:2	56	F	c.571C>T p.(Arg191*)	Depression, anxiety, bipolar disorder, psychosis	N/N/N/N/N	Pallidum	Yes, Fazekas I	Y/N	N/N
B	III:1	29	F	c.571C>T p.(Arg191*)	Depression, anxiety, bipolar personality disorder, vertigo, headaches, aphasia with limb weakness, involuntary muscle jerks, vocal tics	N/N/N/N/N		Yes, Fazekas I	N/N	N/N

DM — diabetes mellitus; F — female; HD — heart disease; HC — hypercholesterolaemia; HTN — hypertension; CH — intracerebral haemorrhage; M — male; MRI — magnetic resonance imaging; N — no; S — smoking; Y — yes. *This individual had recurring episodes with unilateral weakness that included her facial musculature and sensory symptoms, but on examination had a persistent central facial palsy on same side. †truncating variant

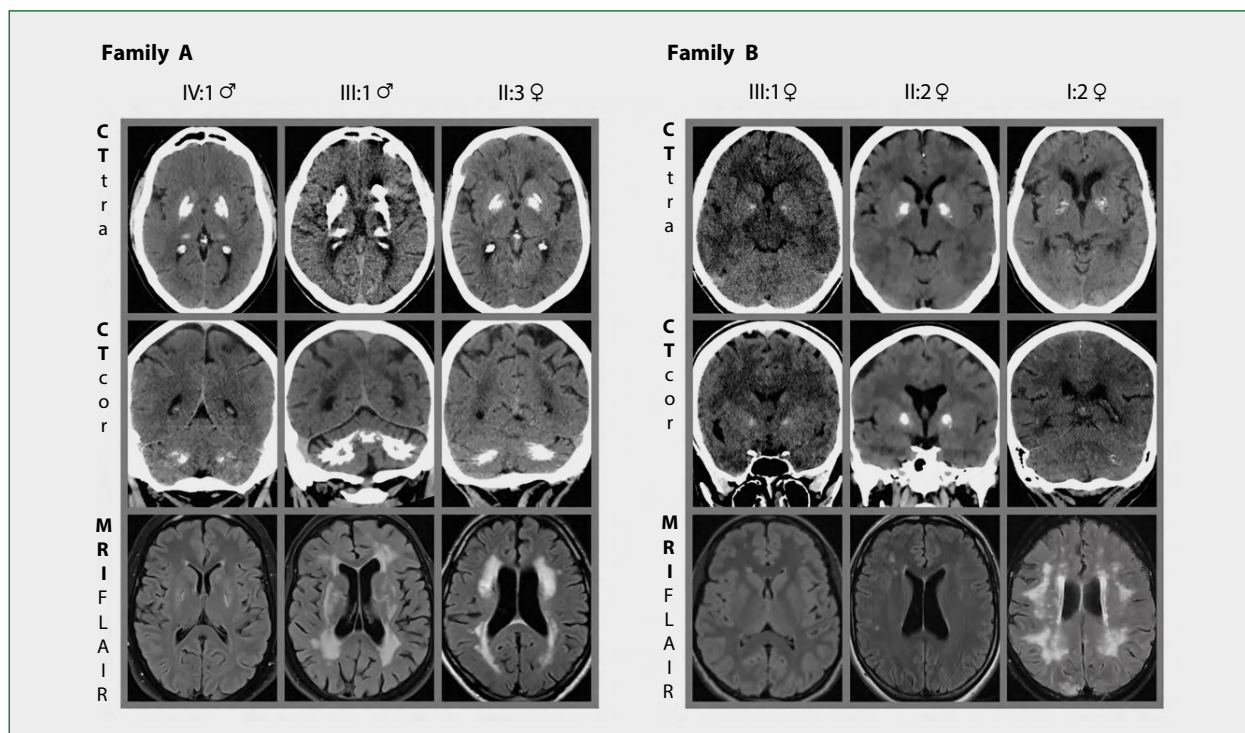


Figure 2. Radiological examinations of families A and B. Computed tomography (CT) scans from affected individuals in family A show bilateral calcifications in basal ganglia and cerebellum, while in family B they are present in basal ganglia of all three affected individuals; only discrete calcifications in the cerebellum are noted. Magnetic resonance imaging (MRI) shows white matter hyperintensities in all six mutation carriers. Both calcifications and small vessel disease are more prominent in older individuals

transient weakness in her right arm and hand. Some of these episodes were accompanied by dizziness and/or a subjective feeling of imbalance. A diagnosis of recurrent TIAs was made at the time, but when examined within our study at age 86, she had discrete right central facial palsy that had become permanent, compatible with a clinical diagnosis of stroke. Cardiac investigations including electrocardiography and trans-thoracic echocardiography, as well as assessments of the large artery with Duplex ultrasound of the cervical vessels and conventional angiography of cervical and intracranial vessels, yielded normal results except for atherosclerosis on the right subclavian and left vertebral arteries, with less than a 40% diameter reduction. She refused to participate in cognitive testing, but reports from family members suggested moderate cognitive decline.

Other than the individual II:3 who was a smoker and had hypercholesterolaemia, none of the other investigated persons in these two families had classical vascular risk factors (Tab.1).

A fourth member (III:2) was examined clinically and tested genetically, without any abnormal findings.

Family B: Three family members were examined clinically, and clinical records of a fourth were reviewed (Fig. 1).

The index patient (III:1) presented with depression, anxiety and anorexia from the age of 14. She had been diagnosed with bipolar and borderline personality disorder. Her previous medical history included asthma, inflammatory bowel

syndrome, and chronic urinary retention demanding periodic catheterisation. From the age of 24, she suffered from chronic vertigo and migraine. She had recurrent episodes of transient aphasia and limb weakness leading to emergency admissions. Investigations conducted by the treating neurologists failed to yield a definitive diagnosis either of a vascular event (TIA) or of seizures/epilepsy. Additionally, she manifested nonspecific involuntary myoclonic jerks in the shoulder and neck regions, accompanied by vocal tics. Clinical examination revealed diplopia, with mild balance disturbance as well as myoclonus in her hands when stretching them forward. Her muscle jerks demonstrated improvement upon the administration of clonazepam 0.5 mg/d. In recent years, she had had intermittent episodes of generalised myoclonus that had been repeatedly considered to be non-epileptic in nature by neurologists, and where her postictal EEGs were repeatedly normal.

Her mother (II:2) had had a history of depression and anxiety since her early 20s, and had been diagnosed with bipolar disorder at age 36. Clinical examination at 52 years revealed normal neurological findings. She had not had a TIA or a stroke, and had no classical vascular risk factors.

The grandmother of the index patient (I:2) was deceased at the time of the study. Her medical records reported focal and secondary generalised seizures at age 72. There was no documented history of trauma, or of signs of a systemic or localised cerebral inflammatory or infectious metabolic

Unfortunately, no previous MRI scans were accessible for comparative analysis. The grandmother's (I:2) CT scan at age 72 showed bilateral calcifications in the cerebellum and globus pallidus, more pronounced compared to the younger members of her family, but less intense than all affected individuals in family A. Images are provided in Figure 2 and Supplementary Data 2. Furthermore, she exhibited cortical calcifications of c.1 mm diameter in the left parietal region and bilaterally in the occipital lobes. Her MRI scan at the same age showed hundreds of supratentorial micro-bleedings compatible with probable cerebral amyloid angiopathy according to the Boston 2.0 2022 criteria [30] (Supplementary Data 2 and 3). Extensive WMH were observed in the periventricular, supra- and infratentorial regions. A CT scan performed > 3 hours after the onset of expressive aphasia showed several acute microbleeds and patchy hypodensities fronto-parietally in the left hemisphere located subcortically, and in a few areas reaching to the cortex (Supplementary Data 3). CT angiography revealed no large vessel abnormalities.

Genetics

Genetic testing of clinically and radiologically unaffected family members from both families revealed the absence of these probably pathogenic variants, while all individuals carrying these variants presented with PFBC (Fig. 1). Thus, carrier status was associated with the presence of PFBC and clinical symptoms in an autosomal dominant manner, although with incomplete penetrance concerning clinical symptoms, but manifesting full penetrance in the context of brain calcifications observed via CT scans. No rare pathogenic variants in stroke genes were identified.

Pathology

Skin biopsies from the upper arms of the three mutation carriers (II:3, III:2, IV:1) and one healthy member (III:2) of family A were obtained and analysed with both light and electron microscopy. This showed a normal number and appearance of the pericytes as well as the basement membrane material of the venular and arteriolar vessels. There was no evidence of calcium in or around the vessels, and the elastic fibres appeared normal. There was no difference between the vessels of the affected members carrying the gene variant from those of the unaffected member not carrying the variant (Supplementary Data 4).

Review of published cases

We reviewed a total of 16 articles describing previous publications on patients with *PDGFB*-related PFBC. Thirty different pathogenic *PDGFB* variants have been reported. Reports on 15 variants have included brain MRI findings, and nine of these 15 reports showed hyperintensities in the white matter. Stroke or TIA was not reported. The results are set out in Table 2. The published electron microscopy images, reported as showing disturbed microvessel architecture [8] were reviewed, but we considered them to show normal findings.

Discussion

In this research paper, we describe two families with PFBC caused by novel truncating mutations in the *PDGFB* gene. All variant carriers had intracerebral calcifications in CT scans and had signs of white matter disease in MRI examinations. White matter disease has previously been reported in the majority of patients with *PDGFB*-related PFBC [8–10, 23, 24, 31] (Tab. 2). In this study, we additionally found that two of the six affected family members (family A, II:3 at age 57, and family B, I:2 at age 78) had stroke and/or TIA, one of these also had abundant cerebral microbleeds, and a third individual (family B, II:2) had ischaemic lesions on MRI that had remained clinically silent.

In the three patients who underwent angiography, clinically relevant large vessel disease was excluded, but vascular imaging was not available for the remaining individuals. Among these three individuals, two did not have any classical vascular risk factors. One of these three individuals (family A II:3) was a smoker, and had hypercholesterolaemia along with moderate radiological evidence of atherosclerotic changes in extracranial vessels not relevant for her symptomatology, and her TIA episodes consistently manifested clinically as lacunary syndromes, suggesting small vessel disease. All the cerebrovascular events in these three individuals were probably secondary to cerebrovascular small vessel disease. The possible exception is family B I:2 who had an episode of expressive aphasia and CT showing acute microbleeds and patchy subcortical and cortical hypodensities. This might be caused by large-vessel disease, but we interpreted the clinical and radiological results as being more compatible with the effect of multiple microbleeds in the same area, also indicating small vessel disease.

Our data suggests that *PDGFB* variants may increase the risk for stroke, TIA, silent brain infarcts and cerebral microbleeds, caused by cerebral small vessel disease.

White matter hyperintensities of putatively vascular origin are a well-established marker of cerebral small vessel disease [32], and have in PFBC patients been explained by the inactivation of the *PDGFB* gene [9]. PDGFB, a growth factor for mesenchymal cells, plays a crucial role in the recruitment of pericytes during angiogenesis [11], and once inactivated can cause vascular dysfunction. Studies in mouse models carrying hypomorphic *PDGFB* alleles, and in patient-derived induced pluripotent cells, showed that loss of endothelial PDGFB correlated with the presence of fewer pericytes around cerebral small vessels, and with blood-brain barrier deficiency [23, 24].

It has previously been suggested that the neurological abnormalities in patients with PFBC are caused by a slow and progressive inflammatory process in the white matter, rather than by the calcifications, which are thought to occur later in the disease [33]. In our study, one patient (family B, III:1) was longitudinally followed-up with repeated imaging, including three MRT investigations over a span of 12 years. These scans illustrated mild progression of WMH. A second variant carrier

Table 2. Previously published cases of idiopathic basal ganglia calcification-5, with PDGFB variants

Variant	Familial/ sporadic	Number of families	Number of cases, sex	Clinical characteristics	Calcifications (CT)	White matter hyperintens- ities_ (MRI)	Extracerebral involvement	Reference
c.3G > A p.(Met11le) missense	Familial	1	3F	Cramping, headaches, neck twitches, dyslexia, short term memory problems, migraines, muscle tightening	Basal ganglia	-	-	[23]
c.3G > C p.(Met11le)	Familial	1	3F, 2M	Seizures (pat IV-2), migraine (all 5)	Pallidum, pulvinar, dentate	Yes, in all 5 patients	Pat III-5: capillary basal membrane abnormalities with microangiopathy	[8]
c.26T > G p.(Leu9Arg) missense	Familial	1	2M, 2F	Migraines with aura, postural tremor, depression, speech and concentration difficulties, hyperactivity disorder	Basal ganglia, white matter, thalamus, cerebellum	-	-	[23]
c.33_34delCT p.(Cys12Leufs*20) nonsense	Sporadic	-	1M	Dizziness, mild cognitive impairment, mild bradykinesia	Pallidum, caudate, pulvinar, dentate, subcortical and periventricular regions	No	-	[24]
c.64-3C > G intronic splicing	Familial	1	3	Not available	Yes	-	-	[34]
c.160 + 2TA intronic splicing	Familial	1	1M	Depression, anxiety, mild cognitive impairment, cerebellar ataxia	Pallidum, caudate, pulvinar, dentate	-	-	[24]
c.220G > T p.(Glu74*) nonsense	Sporadic	-	1F	Dizziness	Basal ganglia, cerebellum	-	-	[41]
c.232C > T p.(Arg78Cys) missense	Familial	3	1F, 2M	Jerky movements, stiffening of limbs, anxiety	Pallidum, caudate, thalamus, subcortical white matter	-	-	[42]
c.283G > A p.(Ala95Thr) missense	Sporadic	-	1	-	-	-	-	[34]
c.328C > G p.(Leu110Val) missense	Sporadic	-	1	-	-	-	-	[34]
c.329T > C p.Leu110Pro missense	Sporadic	-	1M	Paroxysmal dystonia, migraine with aura	'Non-specific findings'	-	-	[43]

Table 2 cont. Previously published cases of idiopathic basal ganglia calcification-5, with PDGFB variants

Variant	Familial/ /sporadic	Number of families	Number of cases, sex	Clinical characteristics	Calcifications (CT)	White matter hyperintens- ities_(MR)	Extracerebral involvement	Reference
c.342_343insG p.Asn115Glnfs*52 nonsense	Sporadic	-	1F	Dementia (diagnosis of Alzheimer's Disease), impaired postural reflexes, frontal lobe impairment,	Pallidum, pulvinar, caudate, dentate	Yes	-	[24]
c.356T > C p.(Leu119Pro) missense	Familial	1	3M	severe motor and language impairment, migraine	Basal ganglia, subcortical white matter, cerebral white matter	-	-	[23]
c.356T > C p.(Leu119Pro) missense	Sporadic	-	1	-	-	-	-	[34]
c.365C > T p.(Pro122Leu) missense	Familial	1	4F	Psychosis, depression, jerky ocular pursuit, chorea, midline ataxia, unsteady gait, complex motor tic, dystonic posturing of feet	Pallidum, dentate	Yes (one patient IV,4)	-	[31]
c.394G > C p.(Gly132Arg) missense	Sporadic	-	1	Asymptomatic	Pallidum, putamen, dentate nuclei	-	-	[25]
c.425G > A p.(Arg142His) missense	Sporadic	-	1	Cognitive, mood, movement disorder	Pallidum, putamen, dentate nuclei, caudate nuclei, thalamus	No	-	[25]
c.433C > T p.(Gln145*) nonsense	Familial	1	3M, 3F	Chorea, orobuccal dyskinesia, psychiatric symptoms, gait problems, parkinsonism, dysexecutive syndrome, tremor. 1 asymptomatic	Basal ganglia, thalamus, cerebellum, cerebral white matter, subcortical white matter	-	-	[23]
c.439C > T p.(Gln147*) nonsense	Sporadic (de novo)	1	1F	Asymptomatic	Pallidum, putamen, caudate	Yes (very discrete)	-	[9]
c.439C > T p.(Gln147*) nonsense	Sporadic	-	1	-	-	-	-	[34]
c.445C > T p.(Arg149*) nonsense	NA	2	4M	Depression, dysexecutive syndrome with memory impairment, anxiety, depression, akinetic-rigid syndrome, tremor	Basal ganglia	Yes	-	[23, 25]



Table 2 cont. Previously published cases of idiopathic basal ganglia calcification-5, with PDGFB Variants

Variant	Familial/ sporadic	Number of families	Number of cases, sex	Clinical characteristics	Calcifications (CT)	White matter hyperintens- ities_ (MRI)	Extracerebral involvement	Reference
c.446 + 1G > A intronic splicing, skipping of exon4, inducing frameshift	Familial	1	2F	Migraine, depression	Pallidum, putamen, thalamus, dentate nuclei, cortex	Yes	-	[25]
c.456 + 1G > A intronic splicing	Sporadic	-	1F	Headaches, nausea, slowness in writing	Basal ganglia, thalamus, cerebellum	No	-	[4]
c.457 - 1G > T intronic splicing	Familial	1	2F, 1M	Headache, behavioural changes (refusal to attend school)	'Spotty' lesions in pallidum, caudate, thalamus, dentate nuclei	Yes	-	[24]
c.602 - 1G > T intronic splicing	Sporadic	2	1F	Depression	Pallidum, putamen, caudate, dentate	-	Myasthenia gravis	[44]
c.610C > A p.(Pro204Thr) missense	Familial	-	1M	Asymptomatic	Yes	-	-	[41]
c.724T > C p.(Ter242GlnExt*89) stop loss	Sporadic	-	1	Seizure, migraine, depression, cognitive impairment	Pallidum, putamen, caudate, dentate	No	-	[25]
c.726G > C p.(242TyrExt*89) stop loss	Familial	2	6M, 3F	Dyskinesia, pyramidal signs, tics, alcohol abuse, aneurysm in medial cerebral artery	Basal ganglia, cerebellum, cerebral white matter	Yes	-	[23, 25]
Exon 2-5 deletion	Sporadic	-	1F	Memory impairment, bipolar disorder, gait disorder, subtle static cerebellar syndrome	Pallidum, putamen, cerebellum	Yes	-	[9]
22q13.1 deletion including entire PDGFB gene	Familial	1	1M	Blepharospasm, headache, paroxysmal dystonia	Basal ganglia and dentate nuclei	No	-	[21]

CT — computed tomography; F — female; M — male; MRI — magnetic resonance imaging

did not show radiological progression of WMH between the ages of 45 and 51. Regarding the brain calcifications, moderate progress was observed in parallel with clinical progression (Supplementary Data 2), consistent with previous observations by others [19, 34–36].

We were unable to establish a reliable correlation between the symptomatology and radiologically detected vascular changes, nor could we determine the importance of vascular process in disease progression.

Apart from the presence of WMH, postmortem neuropathological investigations of individuals with PFBC have revealed pronounced vascular changes in the brain, including calcium deposits and degeneration of brain capillaries and arterioles [2, 17, 18, 37, 38]. These findings have also confirmed the presence of a degenerative small vessel disease. Whether this vascular process is limited to the brain, or is rather part of a systemic vascular disease, remains unclear. Studies performed on mouse models with partly or completely inactivated *PDGFB* have reported the involvement of extracerebral microvessels in the retina and renal glomeruli [11]. A previous study of skin biopsies from one patient with a *PDGFB* variant causing PFBC reported thickening of the basement membrane and membrane fragmentations in the vessels, which was interpreted as signs of extracerebral microangiopathy [8].

However, skin biopsies obtained from our three symptomatic and one asymptomatic individuals showed no abnormality in the basal lamina, nor did they indicate differences in the number or appearance of pericytes per vessel (Supplementary Data 4). An expert review of the published images [8] could not confirm any abnormality. In our patients with *PDGFB* pathogenic variants, we found no evidence for extracerebral vascular involvement. We have not been able to investigate further neuropathological evidence regarding the possible presence of systemic vascular disorder from any other organ or system apart from the skin.

Our results are difficult to generalise, as we were studying the occurrence of stroke and TIA, two very common conditions in the general population, in only two unrelated families with rare *PDGFB* variants. However, previous publications have reported cases of individuals with PFBC who have presented with ischaemic or haemorrhagic stroke, TIA, and/or intracerebral aneurysms [12–18].

While there have been several previous case reports on patients with WMH acting as warning signs of underlying cerebral vascular conditions and PFBC [11–16], the occurrence of basal ganglia calcifications has to date been considered an incidental finding in patients with cerebral vascular disease and stroke.

Our study adds to the existing literature three cases presenting with TIA, stroke, cerebral ischaemia and microbleeds putatively complicating a cerebral small vascular degenerative process in patients with bilateral brain calcifications.

Clinical implications/future directions

Our study highlights that *PDGFB*-related PFBC is a cerebral small vessel disease that may manifest with stroke and TIA, microbleeds and silent brain infarcts. The patients in this study had normal skin microvasculature, which does not suggest systemic vasculopathy as found in other genetic forms of cerebral small vessel disease, including CADASIL or COL4A1/COL4A2-related disorder [39, 40].

Article information

Availability of data and materials: *Original data presented in this study is included in the article and as Supplementary Material. Further inquiries may be directed to the corresponding author.*

Ethics approval and consent to participate: *This study was approved by the Regional Ethical Review Board in Lund, Sweden, and written informed consent was obtained from all participants.*

Authors' contributions: *M.Y.F.: major role in acquisition of clinical data, interpretation of data, drafting and revising manuscript for content; J.W.: interpretation of radiological investigations, review of manuscript; E.E.: obtained and interpreted pathological examination, review of manuscript; I.B.: interpretation of pathological examination, review of manuscript; A.P.: study concept and design, major role in acquisition of clinical and genetic data, interpretation of data, revising manuscript for content; A.I.: study concept and design, major role in acquisition of clinical and genetic data, interpretation of data, drafting and revising manuscript for content, obtaining funding.*

Funding: *M.Y.F. received a research grant from Elsa Schmitz Foundation, Sweden.*

A.P. is employed by the Region Skåne, Sweden, and receives Governmental funding for clinical research within the Swedish National Health Services (ALF-YF) and has received research support from the Swedish Parkinson Foundation (Parkinsonfonden), MultiPark — a strategic research area at Lund University, Hans-Gabriel and Alice Trolle-Wachtmeister Foundation, as well as the Swedish Parkinson Academy. He receives reimbursement from Elsevier for his work as Associate Editor for Parkinsonism and Related Disorders.

A.I. received funding from the Swedish National Health Services (ALF-YF), the Crafoord Foundation, the Bundy Academy Foundation, the Anna Lisa and Sven-Eric Lundgrens Foundation for Medical Research, and Malmö's General Hospital Foundation to fight heart and vascular disease.

Acknowledgements: *We thank the patients for their participation in this study. Bioinformatician Joel Wallenius verified variant nomenclature. This project was financed by Region Skåne, Skåne University Hospital, the Swedish Parkinson Academy, and by governmental funding for clinical research within the Swedish National Health Services (ALF-YF).*

Conflicts of interest: *None.*

Supplementary material: *Yes.*

References

- Duckett S, Galle P, Escourrolle R, et al. Presence of zinc, aluminum, magnesium in striopallidodentate (SPD) calcifications (Fahr's disease): electron probe study. *Acta Neuropathol.* 1977; 38(1): 7–10, doi: [10.1007/BF00691269](https://doi.org/10.1007/BF00691269), indexed in Pubmed: [857589](https://pubmed.ncbi.nlm.nih.gov/857589/).
- Kobayashi S, Yamadori I, Miki H, et al. Idiopathic nonarteriosclerotic cerebral calcification (Fahr's disease): an electron microscopic study. *Acta Neuropathol.* 1987; 73(1): 62–66, doi: [10.1007/BF00695503](https://doi.org/10.1007/BF00695503), indexed in Pubmed: [3604574](https://pubmed.ncbi.nlm.nih.gov/3604574/).
- Manyam BV. What is and what is not 'Fahr's disease'. *Parkinsonism Relat Disord.* 2005; 11(2): 73–80, doi: [10.1016/j.parkrel-dis.2004.12.001](https://doi.org/10.1016/j.parkrel-dis.2004.12.001), indexed in Pubmed: [15734663](https://pubmed.ncbi.nlm.nih.gov/15734663/).
- Shen Y, Shu S, Ren Y, et al. Case report: two novel frameshift mutations in SLC20A2 and one novel splice donor mutation in PDGFB associated with primary familial brain calcification. *Front Genet.* 2021; 12: 643452, doi: [10.3389/fgene.2021.643452](https://doi.org/10.3389/fgene.2021.643452), indexed in Pubmed: [34025715](https://pubmed.ncbi.nlm.nih.gov/34025715/).
- Chen SY, Ho CJ, Lu YT, et al. The genetics of primary familial brain calcification: a literature review. *Int J Mol Sci.* 2023; 24(13), doi: [10.3390/ijms241310886](https://doi.org/10.3390/ijms241310886), indexed in Pubmed: [37446066](https://pubmed.ncbi.nlm.nih.gov/37446066/).
- Bu W, Hou L, Zhu M, et al. SLC20A2-related primary familial brain calcification with purely acute psychiatric symptoms: a case report. *BMC Neurol.* 2022; 22(1): 265, doi: [10.1186/s12883-022-02798-9](https://doi.org/10.1186/s12883-022-02798-9), indexed in Pubmed: [35850697](https://pubmed.ncbi.nlm.nih.gov/35850697/).
- Lenglez S, Sablon A, Fénelon G, et al. Distinct functional classes of PDGFRB pathogenic variants in primary familial brain calcification. *Hum Mol Genet.* 2022; 31(3): 399–409, doi: [10.1093/hmg/ddab258](https://doi.org/10.1093/hmg/ddab258), indexed in Pubmed: [34494111](https://pubmed.ncbi.nlm.nih.gov/34494111/).
- Biancheri R, Severino M, Robbiano A, et al. White matter involvement in a family with a novel PDGFB mutation. *Neurol Genet.* 2016; 2(3): e77, doi: [10.1212/NXG.0000000000000077](https://doi.org/10.1212/NXG.0000000000000077), indexed in Pubmed: [27227165](https://pubmed.ncbi.nlm.nih.gov/27227165/).
- Nicolas G, Rovelet-Lecrux A, Pottier C, et al. PDGFB partial deletion: a new, rare mechanism causing brain calcification with leukoencephalopathy. *J Mol Neurosci.* 2014; 53(2): 171–175, doi: [10.1007/s12031-014-0265-z](https://doi.org/10.1007/s12031-014-0265-z), indexed in Pubmed: [24604296](https://pubmed.ncbi.nlm.nih.gov/24604296/).
- Shen J, Shillington A, Espay AJ, et al. Familial brain calcifications with leukoencephalopathy: a novel PDGFB variant. *Neurol Genet.* 2022; 8(4): e200001, doi: [10.1212/NXG.0000000000200001](https://doi.org/10.1212/NXG.0000000000200001), indexed in Pubmed: [35747618](https://pubmed.ncbi.nlm.nih.gov/35747618/).
- Lindblom P, Gerhardt H, Liebner S, et al. Endothelial PDGF-B retention is required for proper investment of pericytes in the microvessel wall. *Genes Dev.* 2003; 17(15): 1835–1840, doi: [10.1101/gad.266803](https://doi.org/10.1101/gad.266803), indexed in Pubmed: [12897053](https://pubmed.ncbi.nlm.nih.gov/12897053/).
- Sgùlò FG, di Nuzzo G, de Notaris M, et al. Cerebrovascular disorders and Fahr's disease: report of two cases and literature review. *J Clin Neurosci.* 2018; 50: 163–164, doi: [10.1016/j.jocn.2018.01.002](https://doi.org/10.1016/j.jocn.2018.01.002), indexed in Pubmed: [29396057](https://pubmed.ncbi.nlm.nih.gov/29396057/).
- Eroglu U, Kahilogullari G, Demirel A, et al. Fahr's syndrome associated with multiple intracranial aneurysms: a case report. *Turk Neurosurg.* 2016; 26(4): 643–645, doi: [10.5137/1019-5149.JTN.8574-13.0](https://doi.org/10.5137/1019-5149.JTN.8574-13.0), indexed in Pubmed: [27306481](https://pubmed.ncbi.nlm.nih.gov/27306481/).
- Asensio Moreno C, Arias Jiménez JL, Aramburu Bodas O, et al. [Transient ischemic attack associated with a calcinosis cerebri syndrome]. *An Med Interna.* 2008; 25(1): 33–35, doi: [10.4321/s0212-71992008000100009](https://doi.org/10.4321/s0212-71992008000100009), indexed in Pubmed: [18377194](https://pubmed.ncbi.nlm.nih.gov/18377194/).
- Al-Jehani H, Ajan A, Sinclair D. Fahr's disease presenting with aneurysmal subarachnoid hemorrhage. *J Clin Imaging Sci.* 2012; 2: 27, doi: [10.4103/2156-7514.96542](https://doi.org/10.4103/2156-7514.96542), indexed in Pubmed: [22754741](https://pubmed.ncbi.nlm.nih.gov/22754741/).
- Bartecki BF, Kamienowski J. [Transient focal ischemia in Fahr's disease]. *Neurol Neurochir Pol.* 1979; 13(4): 443–447, indexed in Pubmed: [481695](https://pubmed.ncbi.nlm.nih.gov/481695/).
- Iwase T, Yoshida M, Hashizume Y, et al. Intracranial vascular calcification with extensive white matter changes in an autopsy case of pseudopseudohypoparathyroidism. *Neuropathology.* 2019; 39(1): 39–46, doi: [10.1111/neup.12518](https://doi.org/10.1111/neup.12518), indexed in Pubmed: [30430658](https://pubmed.ncbi.nlm.nih.gov/30430658/).
- Iwase T, Yoshida M, Iwasaki Y, et al. Selective extension of cerebral vascular calcification in an autopsy case of Fahr's syndrome associated with asymptomatic hypoparathyroidism. *Neuropathology.* 2021; 41(5): 387–395, doi: [10.1111/neup.12760](https://doi.org/10.1111/neup.12760), indexed in Pubmed: [34462978](https://pubmed.ncbi.nlm.nih.gov/34462978/).
- Batla A, Tai XY, Schottlaender L, et al. Deconstructing Fahr's disease/syndrome of brain calcification in the era of new genes. *Parkinsonism Relat Disord.* 2017; 37: 1–10, doi: [10.1016/j.parkrel-dis.2016.12.024](https://doi.org/10.1016/j.parkrel-dis.2016.12.024), indexed in Pubmed: [28162874](https://pubmed.ncbi.nlm.nih.gov/28162874/).
- Mulroy E, Ilinca A, Gonzalez-Robles C, et al. Throat-clearing vocalizations in primary brain calcification syndromes. *Mov Disord Clin Pract.* 2021; 8(4): 627–630, doi: [10.1002/mdc3.13175](https://doi.org/10.1002/mdc3.13175), indexed in Pubmed: [33981802](https://pubmed.ncbi.nlm.nih.gov/33981802/).
- Duan RN, Zhao DD, Liu YM, et al. A heterozygous deletion of PDGFB gene causes paroxysmal kinesigenic dyskinesia with primary familial brain calcification. *Parkinsonism Relat Disord.* 2021; 92: 83–87, doi: [10.1016/j.parkrel-dis.2021.10.021](https://doi.org/10.1016/j.parkrel-dis.2021.10.021), indexed in Pubmed: [34736156](https://pubmed.ncbi.nlm.nih.gov/34736156/).
- Hayashi T, Legati A, Nishikawa T, et al. First Japanese family with primary familial brain calcification due to a mutation in the PDGFB gene: an exome analysis study. *Psychiatry Clin Neurosci.* 2015; 69(2): 77–83, doi: [10.1111/pcn.12238](https://doi.org/10.1111/pcn.12238), indexed in Pubmed: [25211641](https://pubmed.ncbi.nlm.nih.gov/25211641/).
- Keller A, Westenberger A, Sobrido MJ, et al. Mutations in the gene encoding PDGF-B cause brain calcifications in humans and mice. *Nat Genet.* 2013; 45(9): 1077–1082, doi: [10.1038/ng.2723](https://doi.org/10.1038/ng.2723), indexed in Pubmed: [23913003](https://pubmed.ncbi.nlm.nih.gov/23913003/).
- Sekine SI, Kaneko M, Tanaka M, et al. Functional evaluation of PDGFB-variants in idiopathic basal ganglia calcification, using patient-derived iPSC cells. *Sci Rep.* 2019; 9(1): 5698, doi: [10.1038/s41598-019-42115-y](https://doi.org/10.1038/s41598-019-42115-y), indexed in Pubmed: [30952898](https://pubmed.ncbi.nlm.nih.gov/30952898/).
- Ramos EM, Carecchio M, Lemos R, et al. Primary brain calcification: an international study reporting novel variants and associated phenotypes. *Eur J Hum Genet.* 2018; 26(10): 1462–1477, doi: [10.1038/s41431-018-0185-4](https://doi.org/10.1038/s41431-018-0185-4), indexed in Pubmed: [29955172](https://pubmed.ncbi.nlm.nih.gov/29955172/).
- Richards S, Aziz N, Bale S, et al. Standards and guidelines for the interpretation of sequence variants: a joint consensus recommendation of the American College of Medical Genetics and Genomics and the Association for Molecular Pathology. *Genet Med.* 2015; 17(5): 405–424, doi: [10.1038/gim.2015.30](https://doi.org/10.1038/gim.2015.30), indexed in Pubmed: [25741868](https://pubmed.ncbi.nlm.nih.gov/25741868/).
- Ilinca A, Samuelsson S, Piccinelli P, et al. A stroke gene panel for whole-exome sequencing. *Eur J Hum Genet.* 2019; 27(2): 317–324, doi: [10.1038/s41431-018-0274-4](https://doi.org/10.1038/s41431-018-0274-4).
- Ilinca A, Puschmann A, Putaala J, et al. Updated stroke gene panels: rapid evolution of knowledge on monogenic causes of stroke. *Eur J Hum Genet.* 2023; 31(2): 239–242, doi: [10.1038/s41431-022-01207-6](https://doi.org/10.1038/s41431-022-01207-6), indexed in Pubmed: [36253534](https://pubmed.ncbi.nlm.nih.gov/36253534/).
- Nicolas G, Pottier C, Charbonnier C, et al. Phenotypic spectrum of probable and genetically-confirmed idiopathic basal ganglia calcification. *Brain.* 2013; 136(Pt 11): 3395–3407, doi: [10.1093/brain/awt255](https://doi.org/10.1093/brain/awt255), indexed in Pubmed: [24065723](https://pubmed.ncbi.nlm.nih.gov/24065723/).
- Charidimou A, Boulouis G, Frosch MP, et al. The Boston criteria version 2.0 for cerebral amyloid angiopathy: a multicentre, retrospective, MRI-neuropathology diagnostic accuracy study. *Lancet Neurol.* 2022;

- 21(8): 714–725, doi: [10.1016/S1474-4422\(22\)00208-3](https://doi.org/10.1016/S1474-4422(22)00208-3), indexed in Pubmed: [35841910](https://pubmed.ncbi.nlm.nih.gov/35841910/).
31. Keogh MJ, Pyle A, Daud D, et al. Clinical heterogeneity of primary familial brain calcification due to a novel mutation in PDGFB. *Neurology*. 2015; 84(17): 1818–1820, doi: [10.1212/WNL.0000000000001517](https://doi.org/10.1212/WNL.0000000000001517), indexed in Pubmed: [25832657](https://pubmed.ncbi.nlm.nih.gov/25832657/).
 32. Wardlaw JM, Smith EE, Biessels GJ, et al. Neuroimaging standards for research into small vessel disease and its contribution to ageing and neurodegeneration. *Lancet Neurol*. 2013; 12(8): 822–838, doi: [10.1016/S1474-4422\(13\)70124-8](https://doi.org/10.1016/S1474-4422(13)70124-8), indexed in Pubmed: [23867200](https://pubmed.ncbi.nlm.nih.gov/23867200/).
 33. Avrahami E, Cohn DF, Feibel M, et al. MRI demonstration and CT correlation of the brain in patients with idiopathic intracerebral calcification. *J Neurol*. 1994; 241(6): 381–384, doi: [10.1007/BF02033355](https://doi.org/10.1007/BF02033355), indexed in Pubmed: [7931433](https://pubmed.ncbi.nlm.nih.gov/7931433/).
 34. Nicolas G, Charbonnier C, de Lemos RR, et al. Brain calcification process and phenotypes according to age and sex: lessons from SLC20A2, PDGFB, and PDGFRB mutation carriers. *Am J Med Genet B Neuropsychiatr Genet*. 2015; 168(7): 586–594, doi: [10.1002/ajmg.b.32336](https://doi.org/10.1002/ajmg.b.32336), indexed in Pubmed: [26129893](https://pubmed.ncbi.nlm.nih.gov/26129893/).
 35. Nicolas G, Pottier C, Maltête D, et al. Mutation of the *PDGFRB* gene as a cause of idiopathic basal ganglia calcification. *Neurology*. 2013; 80(2): 181–187, doi: [10.1212/wnl.0b013e31827ccf34](https://doi.org/10.1212/wnl.0b013e31827ccf34), indexed in Pubmed: [23255827](https://pubmed.ncbi.nlm.nih.gov/23255827/).
 36. Tadic V, Westenberger A, Domingo A, et al. Primary familial brain calcification with known gene mutations: a systematic review and challenges of phenotypic characterization. *JAMA Neurol*. 2015; 72(4): 460–467, doi: [10.1001/jamaneurol.2014.3889](https://doi.org/10.1001/jamaneurol.2014.3889), indexed in Pubmed: [25686319](https://pubmed.ncbi.nlm.nih.gov/25686319/).
 37. Miklossy J, Mackenzie IR, Dorovini-Zis K, et al. Severe vascular disturbance in a case of familial brain calcinosis. *Acta Neuropathol*. 2005; 109(6): 643–653, doi: [10.1007/s00401-005-1007-7](https://doi.org/10.1007/s00401-005-1007-7), indexed in Pubmed: [15937691](https://pubmed.ncbi.nlm.nih.gov/15937691/).
 38. Unkrig S, Gullotta F, Madea B. Morbus Fahr—considerations on a case of sudden death. *Forensic Sci Int*. 2011; 204(1-3): e12–e15, doi: [10.1016/j.forsciint.2010.05.020](https://doi.org/10.1016/j.forsciint.2010.05.020), indexed in Pubmed: [21216359](https://pubmed.ncbi.nlm.nih.gov/21216359/).
 39. Ebke M, Dichgans M, Bergmann M, et al. CADASIL: skin biopsy allows diagnosis in early stages. *Acta Neurol Scand*. 1997; 95(6): 351–357, doi: [10.1111/j.1600-0404.1997.tb00224.x](https://doi.org/10.1111/j.1600-0404.1997.tb00224.x), indexed in Pubmed: [9228269](https://pubmed.ncbi.nlm.nih.gov/9228269/).
 40. Plaisier E, Gribouval O, Alamowitch S, et al. COL4A1 mutations and hereditary angiopathy, nephropathy, aneurysms, and muscle cramps. *N Engl J Med*. 2007; 357(26): 2687–2695, doi: [10.1056/NEJMoa071906](https://doi.org/10.1056/NEJMoa071906), indexed in Pubmed: [18160688](https://pubmed.ncbi.nlm.nih.gov/18160688/).
 41. Yao XP, Wang C, Su HZ, et al. Mutation screening of PDGFB gene in Chinese population with primary familial brain calcification. *Gene*. 2016, doi: [10.1016/j.gene.2016.10.037](https://doi.org/10.1016/j.gene.2016.10.037), indexed in Pubmed: [27984190](https://pubmed.ncbi.nlm.nih.gov/27984190/).
 42. Wang C, Ma X, Xu X, et al. A PDGFB mutation causes paroxysmal nonkinesigenic dyskinesia with brain calcification. *Mov Disord*. 2017; 32(7): 1104–1106, doi: [10.1002/mds.26988](https://doi.org/10.1002/mds.26988), indexed in Pubmed: [28556368](https://pubmed.ncbi.nlm.nih.gov/28556368/).
 43. Zhan FX, Tian WT, Zhang C, et al. Primary familial brain calcification presenting as paroxysmal kinesigenic dyskinesia: genetic and functional analyses. *Neurosci Lett*. 2020; 714: 134543, doi: [10.1016/j.neulet.2019.134543](https://doi.org/10.1016/j.neulet.2019.134543), indexed in Pubmed: [31618668](https://pubmed.ncbi.nlm.nih.gov/31618668/).
 44. Koyama S, Sato H, Kobayashi R, et al. Clinical and radiological diversity in genetically confirmed primary familial brain calcification. *Sci Rep*. 2017; 7(1): 12046, doi: [10.1038/s41598-017-11595-1](https://doi.org/10.1038/s41598-017-11595-1), indexed in Pubmed: [28935882](https://pubmed.ncbi.nlm.nih.gov/28935882/).