

Available online at www.sciencedirect.com

ScienceDirect

journal homepage: <http://www.elsevier.com/locate/pjnns>

Original research article

Hypoglossal nerve palsy as an isolated syndrome of internal carotid artery dissection: A review of the literature and a case report



Martyna Mes¹, Piotr Palczewski², Piotr Szczudlik¹, Anna Łusakowska¹,
Edyta Maj³, Małgorzata Gawel^{1,*}

¹Department of Neurology, Medical University of Warsaw, Warsaw, Poland

²I Department of Clinical Radiology, Medical University of Warsaw, Warsaw, Poland

³II Department of Clinical Radiology, Medical University of Warsaw, Warsaw, Poland

ARTICLE INFO

Article history:

Received 13 January 2018

Accepted 25 June 2018

Available online 6 July 2018

Keywords:

Internal carotid artery dissection

Hypoglossal nerve palsy

Fibrillations

ABSTRACT

A review of literature on the dissection of internal carotid artery was presented with a presentation of a rare case of patient with transient left hypoglossal nerve palsy caused by mechanic compression from intramural hematoma in higher extracranial portion of dissected carotid artery confirmed in MRI and CT scans. The clinical presentation and management are discussed.

© 2018 Polish Neurological Society. Published by Elsevier Sp. z o.o. All rights reserved.

1. Introduction

Internal carotid artery dissection (ICAD) is a common cause of stroke in young and middle age patients. ICAD typically presents through headache, neck pain, ipsilateral Horner's syndrome and symptoms of transient or persistent cerebral ischemia. Isolated hypoglossal nerve palsy caused by pressure of extended wall of dissected artery is a rare manifestation of ICAD.

Spontaneous internal artery dissections are uncommon. In community-based studies in the United States and France, the annual incidence of spontaneous carotid-artery dissection ranged from 2.5 to 3 per 100,000 [1,2]. Isolated 12th cranial

nerve palsy is a rare manifestation of internal carotid artery dissection. A comprehensive literature search revealed twenty two reported cases [3–20]. In two cases, bilateral dissection was encountered [3,17]. Isolated hypoglossal palsy may comprise different etiologies including surgical procedures causes, especially endarterectomy (29%), primary and metastatic tumors, radiation and trauma. Dissection of internal carotid artery was reported in 1.2% patients with hypoglossal nerve palsy [21].

The typical symptoms of internal carotid artery dissection are presumed to result from the following mechanisms: (1) ischemia caused by artery stenosis, (2) embolism, (3) antegrade propagation of the thrombus, (4) pressure on sympathetic

* Corresponding author at: Department of Neurology, Medical University of Warsaw, Banacha 1A, 02-097 Warsaw, Poland.

E-mail address: mgawel@wum.edu.pl (M. Gawel).

<https://doi.org/10.1016/j.pjnns.2018.06.006>

0028-3843/© 2018 Polish Neurological Society. Published by Elsevier Sp. z o.o. All rights reserved.

fibers by dissecting artery that cause partial Horner syndrome, consisting of miosis and ptosis, but not anhidrosis. The isolated hypoglossal nerve palsy suggests that local factors to contribute to neurological deficit. The hypoglossal nerve leaves the skull through its own canal and descends into the retrostyloid space along with cranial nerves IX, X, and XI, the sympathetic chain, jugular vein, and carotid artery [23]. In cases where internal carotid artery dissection occurs in the higher extracranial portion, as in the present case, the expanded dissected arterial wall could directly compress only the hypoglossal nerve resulting in palsy.

Internal carotid artery dissection can occur in patients of all ages. Risk factors predisposing to dissection include the following: hypertension (previously known or patient under antihypertensive treatment or blood pressure $\geq 140/90$ mmHg during nonacute phase), hypercholesterolemia (total cholesterol ≥ 6.20 mmol/L or low-density lipoprotein-cholesterol ≥ 4.1 mmol/L, measured within 48 h after admission to the hospital or diagnosed by the treating physician or patient under lipid-lowering treatment), diabetes mellitus (fasting glucose >7 mmol/L during nonacute phase or use of an antidiabetic therapy), smoking, body mass index, and migraine [22]. Possible reasons for ICAD include congenital tissue defects like fibromuscular dysplasia, Marfan syndrome, type IV Ehler-Danlos syndrome, alpha-1 antitrypsin deficiency, autosomal dominant polycystic kidney disease, osteogenesis imperfecta. Possible reasons for an ICAD include minor and major trauma: coughing, vomiting, sports, cervical manipulation. In reviewed cases 22% (5/22) of patients ICAD was connected with trauma: judo training activity [9], construction work [4], hairdresser [15], dental care [11,16]. Most of the reviewed patients presented headache (60%), some suffered from neck pain (13.5%), mandibular pain (9%). Dysarthria was reported in 68% and dysphagia in 52% patients.

Due to the continuous development of medical imaging technologies, the CAD diagnosis largely depends on imaging techniques, such as computed tomography angiogram (CTA), magnetic resonance imaging (MRI), digital subtraction angiography (DSA), and Doppler ultrasound. Of these techniques, DSA has long been considered as the gold standard for CAD diagnosis. In DSA, artery dissection exhibits beaded and thread-like symptoms, irregular fan-shaped stenosis, indirect signs, such as pseudoaneurysm and venous phase contrast agent retention, and direct signs, such as dual chamber symptoms of two-way blood flow [9]. Due to its wide application and noninvasiveness, CTA can provide important information for the diagnosis of CAD. CTA has a false positive rate of 0 for the diagnosis of vascular occlusion and a detection rate of 96% for the diagnosis of vessel wall thickening and irregular changes and is superior to MRI in revealing intimal flaps and pseudoaneurysms. Color Doppler ultrasound can directly show the situation of the arterial wall and detect both direct and indirect signs of CAD. Transcranial Doppler (TCD) is capable of measuring the blood flow velocity and performing arterial emboli monitoring and helps to determine the presence of CAD. In severe carotid artery stenosis or occlusion, the sensitivity of ultrasound can be 100%, whereas, in mild stenosis, the sensitivity drops to 40%. Currently, noninvasive imaging techniques, such as MRI and magnetic resonance angiography (MRA), are playing increasingly important roles in

the CAD diagnosis. MRI diffusion-weighted imaging (DWI) can lead to the early detection of CAD-induced cerebral changes. Axial MRI can show the situation on the blood vessel wall or lumen to some extent MRA experiences less interference from the bone structure and more completely displays vascular structures, especially in the presence of a contrast agent. High-resolution imaging of the vascular wall structure presented by high-resolution MRI (HRMRI) can differentiate the carotid artery and the surrounding tissues, such as the vertebral artery and the surrounding veins, and is more conducive to the identification of a vessel wall hematoma and intravascular thrombus [24].

Of the twenty two cases reported, 9 persons from were treated by anticoagulants and 5 had taken antiplatelet drugs, however, there is no evidence for superiority of anticoagulation or antiplatelet therapy in prevention of stroke after carotid and vertebral artery dissection [25]. Drug treatment primarily consists of antithrombotic therapy (i.e., anticoagulant and antiplatelet therapies). Anticoagulant therapy includes intravenous heparin therapy coupled with oral application of warfarin, whereas antiplatelet therapy includes a single oral antiplatelet treatment with one antiplatelet aggregation drug or

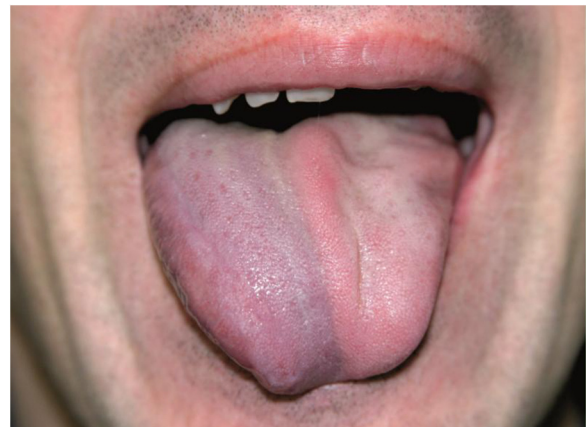


Fig. 1 – Left side tongue paresis – a picture taken at the admission.

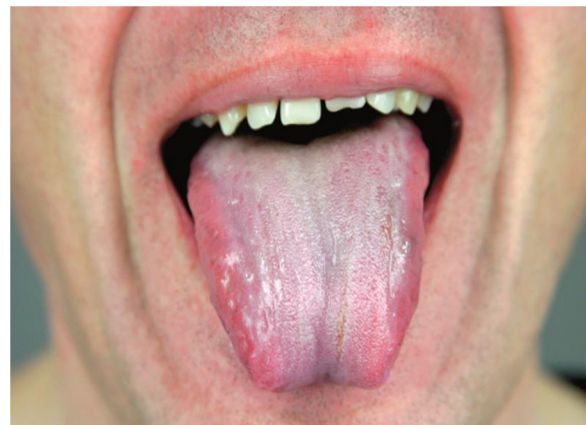

Fig. 2 – Normal tongue – a picture taken 15 weeks later.

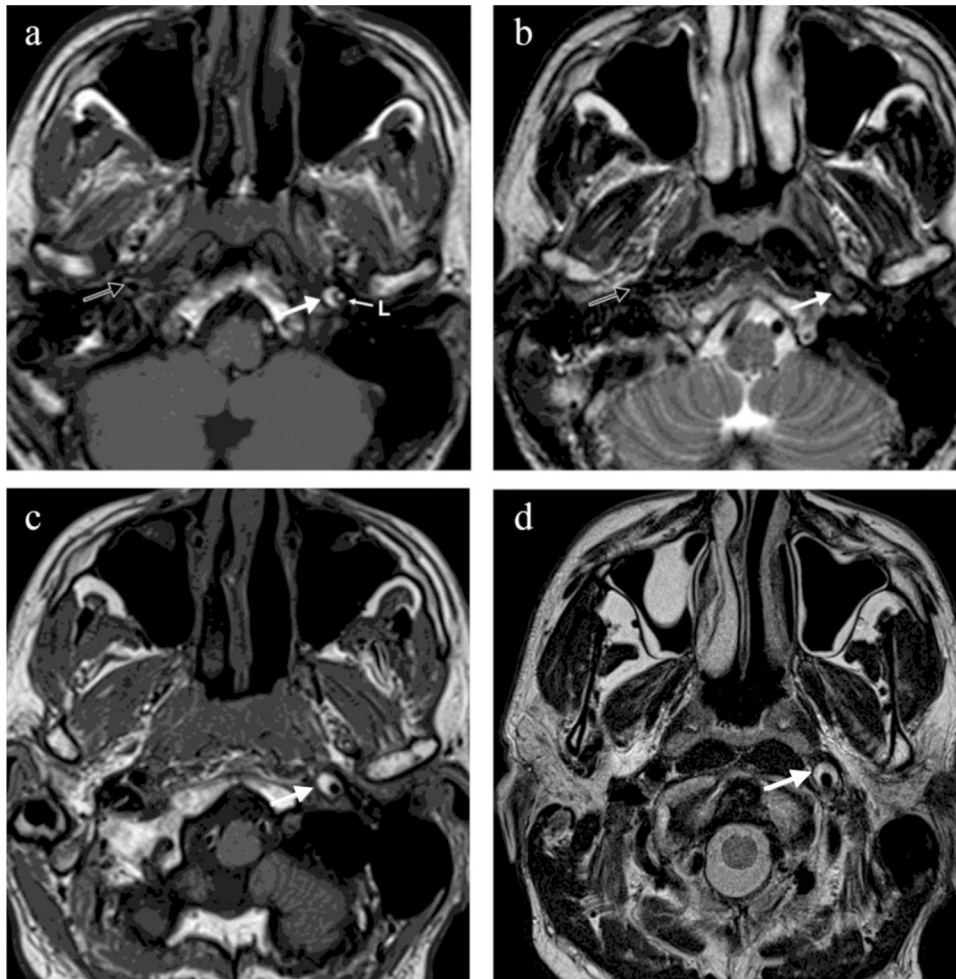


Fig. 3 – Evolution of the dissection in MRI scans. Admission MRI shows intramural hematoma (white arrow) in LICA in a subacute phase with a high signal on T1 (a) and intermediate on T2 (b). The artery is extended, however its lumen (L) is substantially narrowed. Increased signal in the lumen of the artery indicates slow flow. RICA (black arrow) has a low T1 and T2 signal caused by flow void artifact. Follow-up MRI (c and d) after 15 weeks revealed the transition the hematoma (white arrow) to a chronic phase with a high signal on T1 (c) and T2 and normalization of the lumen of the artery.

a dual antiplatelet treatment with a combination of two antiplatelet aggregation drugs as the main treatment programs; antiplatelet treatment includes aspirin, dipyridamole, or clopidogrel alone or in combination. Endovascular treatment of cervical artery dissection (CAD) has been widely used to treat cardiovascular and cerebrovascular diseases. However, randomized controlled studies on the application of endovascular treatment or surgeries for CAD patients have not been reported to date and the efficacy and safety of endovascular therapy or surgical treatment have not been evaluated in CAD patients [24]. If drug therapy is ineffective for the patient and the patient can generally withstand surgery and is suggested to have acute cerebral infarction by laboratory examination, stenosis, or occlusion caused by hematoma based on the pathophysiological manifestations, or an expanding dissection lesion, the implementation of endovascular surgery would generate more benefits than risks [26].

2. Case report

The emergency room intake procedures identified a previously healthy 42-years old man presenting with a 2-day history of swallowing problems and speaking difficulties. A day before the symptoms developed, the patient's blood pressure had risen to 170/100 mmHg. The patient did not suffer head or neck trauma and had no history of cancer or surgery. The neurologic examination, except dysphagia and dysarthria, revealed tongue deviation to the left indicating left hypoglossal nerve palsy (Fig. 1). No other neurological deficits were detected. Blood pressure was 160/80 mmHg. There were no abnormal signs in cardiorespiratory system. Routine blood tests were unremarkable.

The patient was referred to magnetic resonance imaging of the brain which included a diffusion-weighted sequence and

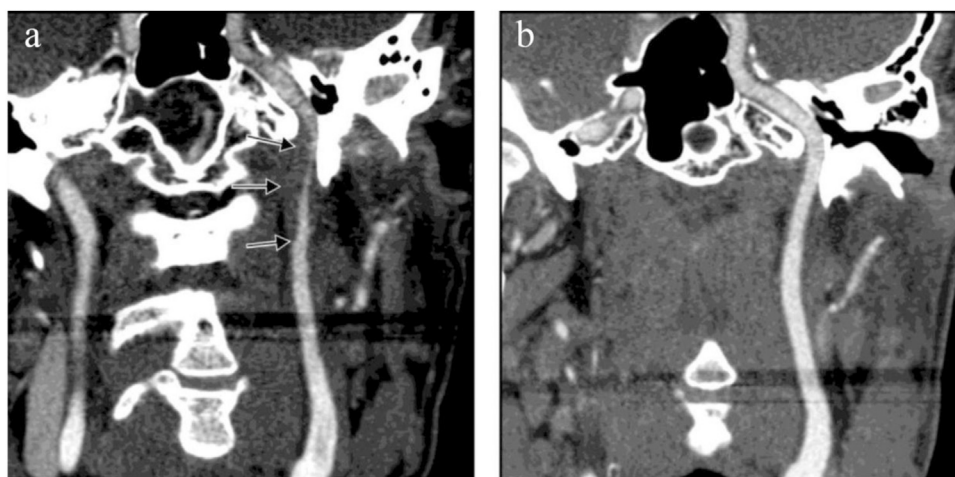


Fig. 4 – (a) CT angiography performed 5 days after admission revealed significant stenosis of LICA (the arrows indicate the extent of intramural hematoma). (b) Follow-up CT angiography 15 weeks after the first visit showed a near total reconstitution of LICA lumen.

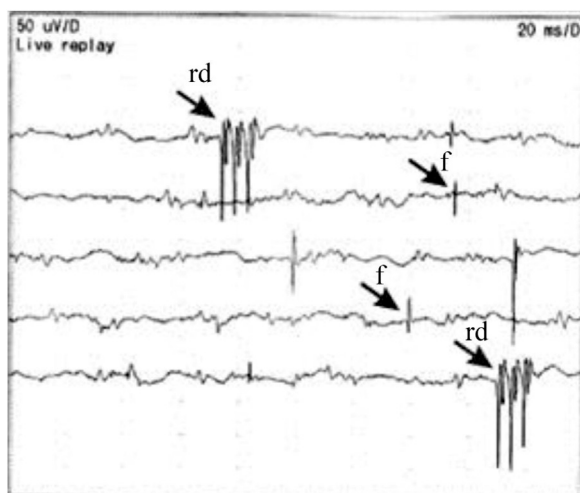


Fig. 5 – The left side tongue muscle electromyography – short complex repetitive discharges (rd) and fibrillations (f) are an evidence of acute denervation.

was reported as normal (Fig. 3). Duplex Doppler sonography suggested an occlusion of the left internal carotid artery (LICA) and was followed by CT-angiography that revealed a significant stenosis of LICA approximately 7 cm distal to the bifurcation. Electromyography of the tongue performed 10 days after the onset of symptoms was normal. Seven days later spontaneous activity in the form of fibrillations and complex repetitive discharges appeared, as an evidence of acute denervation (fibrillations) (Fig. 5).

Left hypoglossal nerve palsy was diagnosed in a person with a significant stenosis of left internal carotid artery. Because dissection of LICA was suspected, the patient was treated with acetylsalicylic acid (75 mg daily). He also was treated with Ramipril 5 mg because of hypertension. During hospitalization dysarthria and dysphagia slowly retreated.

The patient was re-admitted to the Department of Neurology after 15 weeks. The patient denies any swallowing problems or speaking difficulties. Upon neurologic examination, no abnormalities were detected (Fig. 2). The result of the Duplex Doppler study was normal. The retrospective analysis of previous cerebral MRI demonstrated a critical stenosis of the LICA due to an intramural hematoma into a subacute phase (Fig. 3a and b). The subsequent MRI showed a conversion of hematoma to a chronic phase with normalization the lumen of the left carotid artery (Fig. 3c and d). A new CT angiography showed a near total reconstitution of the LICA lumen (Fig. 4b). However, analysis of the original the CT angiography was performed again and indicated that ICA stenosis was caused by intramural hemorrhage (Fig. 4, a). In control tongue electromyography – examination during rest revealed no signs of denervation.

3. Discussion

Our patient has not presented the symptoms of stroke despite the significant stenosis of ICA due to collateral circulation through the anterior communicating artery, shown by Duplex Doppler. A natural reduction of the mechanic compression or one brought about by therapeutic intervention was observed in our patient, which reduced the palsy. This reduction of mechanic compression was additionally confirmed by disappearance of electromyographic symptoms of denervation. Recanalisation of LICA and resolution of left hypoglossal nerve paresis were confirmed by the relief of neurological symptoms, and also, what is very interesting, by disappearance of acute denervation in electromyography of tongue.

There was no conflicts of interest and commercial relationships including grants, honoraria, speaker's lists, significant ownership, and/or support from pharmaceutical or other companies, during our study.

As a principal author I take full responsibility for the data, the analyses and interpretation, and the conduct of the research. I have full access to all of the data and I have the right to publish any and all data. This manuscript is not under consideration by another journal and has not been previously published. All authors have read and approved the revised manuscript.

Conflict of interest

None declared.

Acknowledgement and financial support

None declared.

REFERENCES

- [1] Schievink WI, Mokri B, Whisnant JP. Internal carotid artery dissection in a community. Rochester, Minnesota, 1987–1992. *Stroke* 1993;24(Nov 11):1678–80.
- [2] Giroud M, Fayolle H, André N, Dumas R, Becker F, Martin D, Baudoin N, Krause D. Incidence of internal carotid artery dissection in the community of Dijon. *J Neurol Neurosurg Psychiatry* 1994;57(Nov (11)):1443.
- [3] Olzowy B, Lorenzl S, Guerkov R. Bilateral and unilateral internal carotid artery dissection causing isolated hypoglossal nerve palsy: a case report and review of the literature. *Eur Arch Otorhinolaryngol* 2006;263(Apr (4)):390–3. Epub 2005 Oct 27.
- [4] Mateen FJ, Boes CJ, Kumar N. Unilateral headache and hypoglossal nerve palsy: a report of three cases. *Cephalalgia* 2007;27(Jul (7)):840–2.
- [5] Kaushik S, Abhishek K, Sofi U. Spontaneous dissection of internal carotid artery masquerading as angioedema. *J Gen Intern Med* 2009;24(Jan (1)):126–8. <http://dx.doi.org/10.1007/s11606-008-0813-8>. Epub 2008 Oct 3
- [6] Marin LF, Bichuetti DB, Felício AC, dos Santos WA, de Oliveira FF, Morita ME, et al. Hypoglossal nerve palsy as the sole manifestation of spontaneous internal carotid artery dissection. *Arq Neuropsiquiatr* 2009;67(Mar (1)):107–8.
- [7] Bezerra ML, Pedrosa JL, Pieri A. Spontaneous carotid dissection with hypoglossal nerve palsy as residual deficit: the importance of magnetic resonance evaluation. *Arq Neuropsiquiatr* 2009;67(Dec (4)):1109–10.
- [8] Mathey DG, Wandler A, Rosenkranz M. Images in cardiovascular medicine. Hypoglossal-nerve palsy caused by carotid dissection. *Circulation* 2010;121(3):457. <http://dx.doi.org/10.1161/CIRCULATIONAHA.109.908186>
- [9] Freilinger T, Heuck A, Strupp M, Jund R. Images in vascular medicine: hypoglossal nerve palsy due to internal carotid artery dissection. *Vasc Med* 2010;15(Oct (5)):435–6. <http://dx.doi.org/10.1177/1358863X10378789>
- [10] Okunomiya T, Kageyama T, Suenaga T. Teaching NeuroImages: isolated hypoglossal nerve palsy due to internal carotid artery dissection. *Neurology* 2012;79(4):e37. <http://dx.doi.org/10.1212/WNL.0b013e3182604506>
- [11] De Santis F, Martini G, Thüringen P, Thaler M, Mani G, Steckholzer K. Internal carotid artery dissection after inferior alveolar nerve block for third molar dental care presented as hypoglossal nerve palsy. *Vasc Endovascular Surg* 2012;46(Oct (7)):591–5. <http://dx.doi.org/10.1177/1538574412456437>. Epub 2012 Aug 21
- [12] Riancho J, Infante J, Mateo JJ, Berciano J, Agea L. Unilateral isolated hypoglossal nerve palsy associated with internal carotid artery dissection. *J Neurol Neurosurg Psychiatry* 2013;84(Jun 6):706. <http://dx.doi.org/10.1136/innp-2013-304923>. Epub 2013 Mar 7
- [13] Pongmoragot J, Bharatha A, Saposnik G. Pearls and oysters: carotid dissection with normal arterial lumen. *Neurology* 2013;80(Mar (11)):e115–7. <http://dx.doi.org/10.1212/WNL.0b013e31828727e8>
- [14] Ferlazzo E, Gasparini S, Arcudi L, Versace P, Aguglia U. Isolated hypoglossal nerve palsy due to spontaneous carotid artery dissection: a neuroimaging study. *Neurol Sci* 2013;34(Nov 11):2043–4. <http://dx.doi.org/10.1007/s10072-013-1354-4>. Epub 2013 Mar 14
- [15] Hennings JM, Hoehn D, Schumann-Spaeth E, Weber F. Painless hypoglossal palsy as an isolated symptom of spontaneous carotid dissection. *J Stroke Cerebrovasc Dis* 2014;23(Aug (7)):1988–90. <http://dx.doi.org/10.1016/j.jstrokecerebrovasdis.2014.02.001>. Epub 2014 May 1
- [16] Fujii H, Ohtsuki T, Takeda I, Hosomi N, Matsumoto M. Isolated unilateral hypoglossal nerve paralysis caused by internal carotid artery dissection. *J Stroke Cerebrovasc Dis* 2014;23(Sep (8)):e405–6.
- [17] Qi B, Lu ZC, Wu W, Li YP. Bilateral dissecting aneurysms of the internal carotid arteries misdiagnosed as skull base tumors: a case report. *Oncol Lett* 2015;10(Aug (2)):931–3. Epub 2015 Jun 8.
- [18] Joshi P, Bourke D. Isolated hypoglossal nerve palsy due to internal carotid artery dissection. *Pract Neurol* 2017;17(Jun (3)):233–4. <http://dx.doi.org/10.1136/practneurol-2017-001617>. Epub 2017 Mar 20
- [19] Cruciata G, Parikh R, Pradhan M, Shah J, Greif E, Stein EG. Internal carotid artery dissection and pseudoaneurysm formation with resultant ipsilateral hypoglossal nerve palsy. *Radiol Case Rep* 2017;12(Mar (2)):371–5. <http://dx.doi.org/10.1016/j.radcr.2017.01.016>. eCollection 2017 Jun
- [20] Torbus-Paluszczyk M, Mucha S, Wawrzyńczyk M, Pierzchała K, Bartman W, Adamczyk-Sowa M. Hypoglossal nerve palsy in the course of dissection of the internal carotid arteries – case reports. *Neurol Neurochir Pol* 2018;52(Mar (2)):267–73. <http://dx.doi.org/10.1016/j.pjnns.2017.08.012>. Epub 2017 Aug 30
- [21] Stino AM, Smith BE, Temkit M, Reddy SN. Hypoglossal nerve palsy: 45 cases. *Muscle Nerve* 2016;54(Dec (6)):1050–4.
- [22] Béjot Y, Aboa-Eboulé C, Debette S, Pezzini A, Tatlisumak T, Engelter S, et al. Characteristics and outcomes of patients with multiple cervical artery dissection. *Stroke* 2014;45(Jan (1)):37–41. <http://dx.doi.org/10.1161/STROKEAHA.113.001654>. Epub 2013 Dec 10
- [23] Brazis PW, Masdeu JC, Biller J. Localization in clinical neurology. 6th edn. Philadelphia: Lippincott Williams & Wilkins; 2012.
- [24] Peng J, Liu Z, Luo C, Chen L, Hou X, Xiao L, et al. Treatment of cervical artery dissection: antithrombotics, thrombolysis, and endovascular therapy. *Biomed Res Int* 2017;2017:3072098. <http://dx.doi.org/10.1155/2017/3072098>. Epub 2017 May 21
- [25] CADISS trial investigators, Markus HS, Hayter E, Levi C, Feldman A, Venables G, Norris J. Antiplatelet treatment compared with anticoagulation treatment for cervical artery dissection (CADISS): a randomised trial. *Lancet Neurol* 2015;14(Apr (4)):361–7. [http://dx.doi.org/10.1016/S1474-4422\(15\)70018-9](http://dx.doi.org/10.1016/S1474-4422(15)70018-9). Epub 2015 Feb 12
- [26] Pham MH, Rahme RJ, Arnaout O, Hurley MC, Bernstein RA, Batjer HH, et al. Endovascular stenting of extracranial carotid and vertebral artery dissections: a systematic review of the literature. *Neurosurgery* 2011;68(Apr (4)):856–66. <http://dx.doi.org/10.1227/NEU.0b013e318209ce03>. discussion 866