

Available online at www.sciencedirect.com

ScienceDirect

journal homepage: <http://www.elsevier.com/locate/pjnns>

Case report

Symptomatic medulla compression by vertebral artery

Leszek Lombarski^a, Przemysław Kunert^{a,*}, Marcin Skawiński^a, Marek Prokopienko^a, Zbigniew Lewandowski^b, Andrzej Marchel^a^aDepartment of Neurosurgery, Medical University of Warsaw, Banacha 1a st., 02-097 Warsaw, Poland^bDepartment of Epidemiology and Biostatistics, Medical University of Warsaw, Oczki 3 st., 02-007 Warsaw, Poland

ARTICLE INFO

Article history:

Received 6 August 2017

Accepted 10 March 2018

Available online 17 March 2018

Keywords:

Vertebral artery

Medulla oblongata

Neurovascular conflict

Microvascular decompression

ABSTRACT

Objective: Vertebral artery medulla compression syndrome (VAMCS) is a very rare condition manifesting as different neurological focal deficits. The case of a 36-year-old male with symptomatic brainstem compression by vertebral artery (VA) treated by means of microvascular decompression (MVD) and a review of the literature is presented.

Case report: On admission, a 36-year-old patient presented with hypoalgesia, hypothermia and hemiparesis on the left side. Magnetic resonance imaging (MRI) of the head disclosed the right VA loop compressing the ventrolateral medulla and excluded other entities such as brain tumor, stroke and multiple sclerosis. Since displacement and significant compression of the right pyramidal tract was confirmed by diffusion tensor imaging (DTI), neurovascular compression syndrome was diagnosed. The patient underwent MVD of the medulla using a Gore-Tex implant as a separating material via the right far-lateral approach. The left hemiparesis and hemisensory loss remitted rapidly after the procedure. The post-procedural neurological improvement was maintained at one year follow-up. Based on a review of the literature, a total of 33 cases of surgically treated VAMCS has been reported so far.

Conclusion: VAMCS should be considered as the cause of neurological deficits when other pathological entities are ruled out. In symptomatic conflict of the VA with the medulla, microvascular decompression using a Gore-Tex implant can be an effective method of treatment. Nevertheless, a statistical analysis on all reported cases showed favorable results using the VA repositioning technique when compared with MVD (success rate 91% vs. 58%, $p < 0.05$).

© 2018 Polish Neurological Society. Published by Elsevier Sp. z o.o. All rights reserved.

* Corresponding author.

E-mail addresses: info@neurochirurgia.edu.pl (L. Lombarski), pkunert@wp.pl, info@neurochirurgia.edu.pl (P. Kunert), info@neurochirurgia.edu.pl (M. Skawiński), info@neurochirurgia.edu.pl (M. Prokopienko), epidemiologia@wum.edu.pl (Z. Lewandowski), info@neurochirurgia.edu.pl (A. Marchel).<https://doi.org/10.1016/j.pjnns.2018.03.005>

0028-3843/© 2018 Polish Neurological Society. Published by Elsevier Sp. z o.o. All rights reserved.

1. Introduction

The clinical significance of neurovascular compression has been explained by Jannetta, who linked it with trigeminal neuralgia. According to his theory, both the compression of nerve V and pulsatile blood flow in arteries affected by atherosclerosis and age-related elongation cause irritation and hyperactivity of this nerve [1]. Currently, neurovascular conflict is a commonly known clinical condition associated with disorders such as trigeminal neuralgia, hemifacial spasm and glossopharyngeal neuralgia [2]. Vertebral artery medulla compression syndrome (VAMCS) is a condition of significantly lower prevalence and more severe clinical course. The complex clinical presentation of VAMCS, as well as the frequent asymptomatic modeling of the brainstem by the vertebral artery (VA) [3], requires meticulous diagnostics. It is necessary to prove that the symptoms result from the compression of the brainstem by the VA, and clinical conditions such as brain tumor, stroke and multiple sclerosis should be ruled out.

In this paper, we report on the case of a young patient with symptomatic VAMCS. We also present a review of the literature concerning VAMCS with special attention paid to clinical symptoms, diagnostics and therapeutic methods. Cases of brainstem compression by VA aneurysm and compression of the upper cervical spinal cord were excluded from the analysis.

2. Case presentation

2.1. History and examination

A 36-year-old male with a history over the last six months of limping on his left leg and touch sensation impairment in the left half of the body presented with left hemiparesis. Over three months prior to admission, he experienced two episodes of syncope. During this period, the patient complained of paroxysmal "lightning" pain provoked by physical effort and neck flexion in the right occipital region extending to the opposite side of the body with concomitant nausea and periodic vomiting. Similar headaches appeared two years previously and spontaneously remitted after several months. On admission, neurological examination disclosed sensory loss to pain, temperature and non-discriminative touch on the left side of the body. Mild left hemiparesis with increased muscle tone and ankle clonus were observed.

2.2. Imaging studies

An MRI of the head revealed compression of the ventrolateral aspect of the medulla oblongata by an elongated and tortuous right VA (Fig. 1A-C). There were no pathological contrast enhancement or diffusion restriction regions in the brain. CT angiography and DSA (Fig. 1E) disclosed the loop of V4 segment of the right VA projecting posteriorly. Diffusion tensor imaging (DTI) demonstrated the compression and medial displacement of the right pyramidal tract at the level of the upper medulla oblongata (Fig. 1D). A post-processing tool (the syngo.MR

Tractography, Siemens, Erlangen, Germany) was used for DTI analysis. ROI-based analysis was performed on the medulla oblongata to reconstruct the pyramidal tracts. Based on MRI, CT angiography and DSA, other conditions such as tumor, aneurysm and multiple sclerosis were excluded.

2.3. Surgical procedure

The patient was qualified for microvascular decompression (MVD). The motor and somatosensory evoked potentials were monitored intraoperatively. Right lateral suboccipital craniotomy with asymmetric removal of the posterior arch of C1 was performed using an inverted U-shaped musculocutaneous flap. Approximately, the posterior quarter of the occipital condyle was drilled out. The dura was opened with a lazy C incision posteriorly to the VA, followed by cisterna magna opening. The V4 segment of the right VA was exposed and, after stepwise microsurgical dissection along its course, the arterial loop compressing the medulla was reached. Then, the VA loop was dissected and shifted away from the brainstem, followed by placement of the separating material between the medulla and the VA. A short portion of Gore-Tex vascular prosthesis (Gore-Tex® Stretch Vascular Graft, 6 mm, W.L. Gore & Associates, Inc., Flagstaff, AZ) was used for this purpose (Fig. 1F). After visual verification of proper brainstem decompression, the implant position was fixed with fibrin glue (Tissucol®, 4 ml, Baxter Innovations, GmbH, Vienna, AT). VA repositioning with suturing to the dura was also considered before the procedure, but intraoperatively it was determined to be too risky. The motor and somatosensory evoked potential values were stable during the surgery. The dura was closed with watertight sutures, the bone flap was restored and the procedure was completed in the standard fashion.

2.4. Postoperative course and follow-up

No intra- or postoperative complications occurred. The neurological status of the patient improved rapidly in the postoperative period; all motor and sensory deficits resolved completely. Postoperative CT revealed proper fixation of the Gore-Tex implant at the ventrolateral aspect of the decompressed brainstem. The patient was discharged home on postoperative day 7. There was no recurrence of focal deficits within one year of follow-up.

3. Discussion and review of the literature

In 1967, Jannetta et al. reported five clinical cases presenting with trigeminal neuralgia related to a conflict of the superior cerebellar artery branch with the fifth cranial nerve, all of which were treated with MVD [1]. Since then, MVD has been commonly used in the surgical treatment of neurovascular conflicts, including hemifacial spasm and glossopharyngeal neuralgia [2]. Kim et al. reported the first case of a symptomatic conflict of the vertebral artery and the medulla in a patient who presented with hemiparesis and hypoglossal nerve paresis [4]. To the best of our knowledge, a total of 33 cases of surgically treated VAMCS has been reported so far (see Table 1).

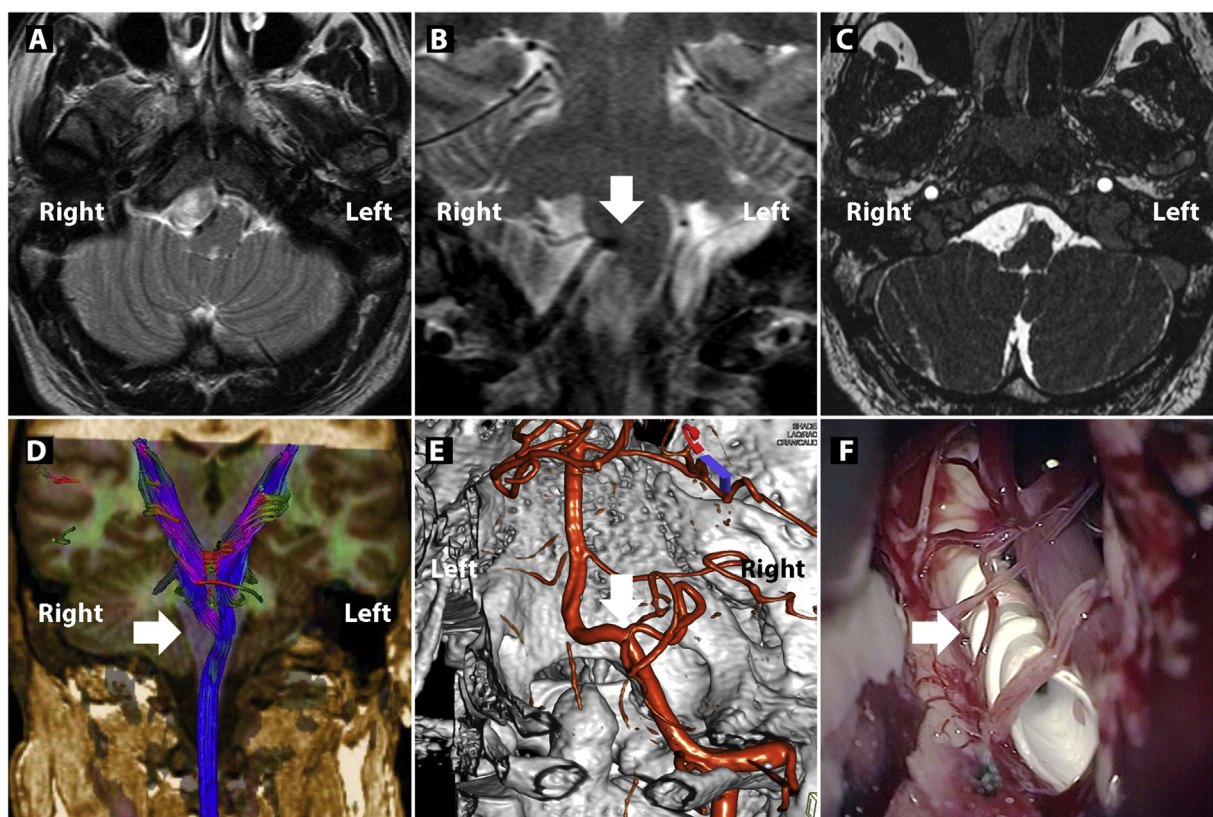


Fig. 1 – Diagnostic imaging of VAMCS.

Preoperative diagnostic imaging modalities (A–E) and intraoperative photograph (F).

MRI T2-weighted axial (A) and coronal (B) scans as well as the CISS sequence (C) demonstrating the compression of the ventrolateral aspect of the medulla oblongata by a tortuous vertebral artery (arrow). (D) Diffusion tensor imaging demonstrated the compression and displacement of the right pyramidal tract (arrow). (E) 3D reconstruction of the right vertebral DSA showing the loop of the V4 segment (arrow). (F) Intraoperative view of the offending VA loop after MVD utilizing the Gore-Tex® vascular prosthesis (arrow) as a separating material.

VAMCS is caused by a tortuous or dolichoectatic VA. It is associated with aging processes, hypertension and progression of atherosclerosis [2]. Therefore, compression of the medulla by VA is mainly reported in the elderly (mean age 51 years, 23 out of 34 cases >40 years). In the case series presented by Savitz et al., two peaks were reported at circa 30 years old and at more than 60 years old [5]. Vertebral dolichoectasia may be the cause of ischemic symptoms that result from turbulent blood flow and atherosclerosis as well as compression symptoms. In our case, the ischemic lesions were excluded in MRI, therefore it might be concluded that the neurological deficits were related to brainstem compression. If the displacement of the spinal cord increases, the risk of occurrence of a number of focal deficits and autonomic nervous system symptoms is also increased [6]. A considerable impact of pulsatile compression on the medulla may be confirmed by the exacerbation of preexisting symptoms, which were observed following physical effort [7]. In our case, the paroxysmal pain in the right occipital region was also provoked by physical effort.

The first clinical cases reported in the literature regarding brainstem compression by the intracranial artery referred to patients suffering from drug-resistant essential hypertension

with no neurological deficits [8]. According to the hypothesis of Jannetta, the compression of the left rostral ventrolateral medulla in the region of the glossopharyngeal and vagus nerve root entry zones by the loop of intracranial vessel may have a considerable effect on the progression of hypertension [2]. Furthermore, VAMCS may contribute to the progression of central sleep apnea [9], which results from the compression of the brainstem respiratory centers or obstructive sleep apnea [10] associated with the blockage of the upper airway due to paresis of the lower cranial nerves.

A list of other symptoms associated with VAMCS includes focal deficits, which result from long tract damage or cranial nerve damage. Depending on the level of the medulla compression by the VA with regard to the decussation of pyramids, VAMCS may be associated with ipsilateral [4,11,12] or contralateral hemiparesis [13–15]. Furthermore, the outermost nerve fibers innervate the lower extremities, which may be associated with an earlier occurrence of motor deficit in the lower extremities [4,5,16,17]. In the presented case, one of the first symptoms was limping on the left leg. Left-sided paresis, pain and temperature sensory disturbances resulted from the compression of the long tracts above their decussation by the right VA.

Table 1 – Review of the case reports of surgically treated patients presenting VAMCS.

Ref. n./year	Gender/age	Side/VA char.	Site of compression	Symptoms	Surgical approach	Treatment method	Outcome/follow-up
[4], 1985	M/53	L/NVA, tortuous	lat. s. + XII	L h.p., L h.r., L ankle clonus, L XII paresis	L far-lat	VA retraction (Dacron slings)	Grad. imp./5 months
[22], 1989	M/30	L/NVA, elongated	vent. s.	q.p., L h.h.e. including the V2, V3 regions	L far-lat.	VA retraction (Dacron slings)	Trans. imp. (deterioration)/1 year
[18], 1991	M/38	R/DVA	c.-m. junct. + XI	NP, N&V, vertigo, visual disturbances, R spasmodic torticollis, cardiac arrhythmias	mid. subocc.	VA retraction (Gore-Tex band)	Imp./2 years
[17], 1992	F/39	B/NVA, medial deviation	lat. s.	HA, L h.p., left h.r., g.a., down-beat nystagmus	mid. subocc.	VA retraction (Gore-Tex band)	Imp./NA
[16], 1993	M/30	L/NVA, elongated	lat. s.	t.p. (R upper and both lower extremities), R h.h.e. including L side of the face	mid. subocc.	(I) MVD; (II) VA section distal to PICA	Trans. imp. (deterioration)/5.5 year
[23], 1955	F/58	B/NVA, tortuous	vent.-lat. s.	q.p., s.d. below C2 level, onion-skin pattern s.d. of the face, both SCM weakness	mid. subocc.	MVD (Dacron pieces)	Grad. imp./NA
[10], 1995	M/62	L/DVA	vent.-lat. s. + IX, X	OSA, d. ph., diminished sensation on the post. aspect of the tongue and B absent gag reflex	L retrosig.	MVD	Imp./3 months
[11], 1999	M/36	R/NVA, tortuous	vent.-lat. s.	R h.p., R h.h.e., onion skin-like s.d., d.ph., decreased gag reflex on the R, R XI palsy	R far-lat.	VA retraction (Teflon felt)	Grad. imp./9 years
[11], 1999	M/47	L/NVA, tortuous	vent.-lat. s.	Vertigo, L cerebellar dysfunction, d.ph., L deafness, decreased gag reflex on the L	L far-lat.	VA retraction (Gore-Tex sheet)	Imp./3 months
[13], 2000	F/54	L/NVA, tortuous	lat. s.	R h.p., R h.r., soft palate deviation, d.ar.	NA	MVD	Imp./NA
[27], 2000	M/47	L/DVA	lat. s.	Palatal myoclonus	NA	MVD	Imp./NA
[21], 2001	M/51	B/NVA, medial deviation	c.-m. junct.	LOC with transient q.p., h.r. Of the L lower extremity, L h.h.a., L h.h.th.	mid. subocc.	VA retraction (Gore-Tex tapes)	Imp./NA
[24], 2001	F/53	L/NVA, elongated	vent.-lat. s. + IX, X	HA and NP, N&V, R h.p., L facial hyperalgesia, R h.h.e.	NA	MVD (Teflon felts)	Grad. imp./2 months
[25], 2002	M/70	L/DVA	c.-m. junct.	q.p., B impaired proprioception and s.d., d.m., d.ar., d.ph., g.a.; B VI palsy, B deafness, absent gag reflex, R spasmodic torticollis, R XII paresis, L adduction nystagmus, RF	L far-lat.	VA retraction (Gore-Tex band)	Part. imp./6 months
[12], 2004	F/55	R/DVA	vent.-lat. s.	R h.p., d.ph.	R retrosig.	VA retraction (Gore-Tex sheet)	Imp./1 year

Table 1 (Continued)

Ref. n./year	Gender/age	Side/VA char.	Site of compression	Symptoms	Surgical approach	Treatment method	Outcome/follow-up
[12], 2004	M/58	L/DVA	vent.-lat. s.	t.p. (L upper and both lower extremities), d.ph.	L retrosig.	VA retraction (Gore-Tex sheet)	Imp./1 year
[12], 2004	M/63	R/DVA	vent.-lat. s.	Dysphonia, d.ph.	R retrosig.	VA retraction (Gore-Tex sheet)	Imp./1 year
[12], 2004	M/67	R/DVA	vent.-lat. s.	q.p.	R retrosig.	VA retraction (Gore-Tex sheet)	Imp./1 year
[12], 2004 [5], 2006	M/73 F/32	L/DVA L/NVA, tortuous	vent.-lat. s. lat. s.	q.p. Hoarseness and d.ph., vocal cord paralysis, asymmetric L palate elevation	L retrosig. NA	MVD MVD	Part. imp./1 year Part. imp. (new deficits)/NA
[5], 2006	F/32	L/NVA, tortuous	vent. s.	HA, vertigo, LOC, L torsional nystagmus, reduced L corneal reflex	NA	MVD	Trans. imp. (recurrence)/4 months
[30], 2008	M/55	B/DVA	lat. s.	d.ar., d.ph., g.a.	NA	VA retraction (Gore-Tex sheet)	Imp./NA
[29], 2008	M/60	L/DVA	vent. s.	Mild progressive d.ar., L h.r.	L far-lat.	VA retraction (Nylon sutures)	Grad. imp./6 months
[20], 2009	M/24	R/NVA, elongated	vent.-lat. s. + V	HA, R V3 neuralgia, s.d. of the R upper extremity and V2, V3 region, R uvula deviation	R far-lat.	VA retraction (Gore-Tex sheet)	Imp./18 months
[20], 2009	M/25	L/NVA, elongated	vent.-lat. s.	HA	L far-lat.	VA retraction (Gore-Tex sheet)	Imp./18 months
[28], 2011	M/54	L/DVA	vent.-lat. s.	g.a., d.ar., B d.m., dysdiadochokinesia	L retrosig.	VA retraction (Silk thread)	Grad. imp./6 months
[26], 2013	M/58	B/NVA, tortuous	NA	p.p., h.r., mild s.d. in both lower extremities	NA	MVD	Grad. imp./NA
[9], 2014	F/71	R/NVA, enlarged	lat. s.	d.ar., d.ph., decreased pharyngeal and cough reflexes, B vocal cord paralysis, RF	R far-lat.	VA retraction (Gore-Tex sheet)	Grad. imp./10 months
[9], 2014	F/71	B/NVA, tortuous	R lat. s.; L vent. s.	Hoarseness and d.ph.	R far-lat.	VA retraction (Gore-Tex sheet)	Grad. imp./several months
[9], 2014	F/72	L/NVA, tortuous	vent.-lat. s.	Decreased pharyngeal and cough reflexes, tongue weakness, RF	L far-lat.	VA retraction (Gore-Tex sheet)	Grad. imp./2 months
[19], 2015	F/69	L/DVA	inf. and post. limit of IV th ventricle	Intractable N&V, dizziness and diplopia	L retrosig.	VA retraction (pericranial graft sling)	Imp./2 years
[14], 2016	M/36	R/DVA	vent.-lat. s.	L h.p., L h.a.	R far-lat.	VA retraction (Teflon sling)	Imp./14 months

Table 1 (Continued)

Ref. n./year	Gender/age	Side/VA char.	Site of compression	Symptoms	Surgical approach	Treatment method	Outcome/follow-up
[15], 2016	F/50	L/DVA	vent. s.	R h.p., R d.m., g.a., binocular conjugate torsional jerk nystagmus simultaneous with contraction of the soft palate	NA	MVD	No change/2 months
2017	M/36	R/NVA, tortuous	vent.-lat. s.	HA and LOC episodes, L h.p., L h.h.a., L h.h.th.	R far-lat.	MVD (Gore-Tex vascular graft)	Imp./1 year

Abbreviations: M – male; F – female; L – left; R – right; B – bilateral; post. – posterior; inf. – inferior; NVA – normal vertebral artery; DVA – dolichoectatic vertebral artery; lat. s. – lateral surface; vent. s. – ventral surface; vent.-lat. s. – ventro-lateral surface; c.-m. junct. – cervicomedullary junction; V – trigeminal nerve; V2 – maxillary nerve; V3 – mandibular nerve; VI – abducens nerve; IX – glossopharyngeal nerve; X – vagus nerve; XI – accessory nerve; XII – hypoglossal nerve; h.p. – hemiparesis; t.p. – triparesis; q.p. – quadriparesis; p.p. – paraparesis; h.r. – hyperreflexia; h.h.e. – hemihypoesthesia; h.h.a. – hemihypoalgesia; h.h.th. – hemihypoanesthesia; h.a. – hemianesthesia; s.d. – sensory disturbance; g.a. – gait ataxia, d.ph. – dysphagia; d.ar. – dysarthria; d.m. – dysmetria; HA – headaches; NP – neck pain; N&V – nausea and vomiting; OSA – obstructive sleep apnea; LOC – loss of consciousness; RF – respiratory failure; far-lat. – far-lateral approach; mid. subocc. – midline suboccipital approach; retrosig. – retrosigmoid approach; MVD – microvascular decompression; VA – vertebral artery; PICA – posterior inferior cerebellar artery; Imp. – improved; Grad. imp. – gradually improved; Part. imp. – partially improved; Trans. imp. – transiently improved; NA – not available.

CT of the head may reveal displacement of the brainstem. Sometimes, it can also show hyperdense calcifications in the VA near the compressed medulla [18]. DSA makes determination of the VA lumen possible with an indirect visualization of atherosclerosis, which is of particular significance when planning the surgery [4,11,14,16–25]. MRI with a CISS sequence reveals precisely the intracranial course of the VA and its relation to the compressed brainstem, therefore it is the examination of choice when a neurovascular conflict is suspected (Fig. 1C) [12]. However, advances in imaging techniques are associated with more common visualization of a conflict of VA with the medulla in 8.3%–25.0% of asymptomatic patients, which create diagnostic and interpretative difficulties [3]. Therefore, taking into account the rarity of VAMCS, the much more common entities such as stroke, brain tumor and multiple sclerosis must be ruled out using standard MR imaging of the brain. Furthermore, DTI may reveal compression and displacement of the pyramidal tracts, which suggests a causal relationship between the conflict and the clinical symptoms. This examination determined the therapeutic decision.

There are a number of pharmacological and invasive treatment methods for trigeminal neuralgia. On the contrary, treatment options of VAMCS are limited to surgical techniques conducted at the site of the conflict (Table 1). A list of surgical techniques includes (a) VA section [16], (b) microvascular decompression [5,10,12,13,15,16,23,24,26,27] using Dacron pieces [23] or Teflon felt [24], and (c) transposition of the VA with its simultaneous anchoring to the dura mater of the posterior cranial fossa [4,9,11,12,14,17–22,25,28–30]. The main difference between the last two surgical procedures mentioned above, i.e., (b) and (c), is the utilization of suturing of the VA to the surrounding dura. In the case of VA repositioning, for example, Dacron slings were used to attach the VA loop firmly to the nearby dura. During the MVD, the separating material

was placed between the offending vertebral artery and the brainstem. Despite the greater technical difficulty and the risk of VA and posterior inferior cerebellar artery (PICA) perforators, VA repositioning is associated with absolute separation of the offending VA from the brainstem. The insertion of separating material between the offending vessel and the brainstem may not be sufficient due to the pulsatility, dimensions and stiffness of the VA. Moreover, MVD may be associated with increased neural compression when the separating material is placed in the conflict area. Therefore, VA repositioning is approved by many authors as the method of choice for VAMCS treatment [12,20,28,29]. Hongo et al. presented three cases of VAMCS [11,16]. One patient deteriorated after MVD and, during revision surgery, the authors sectioned the VA distally to the PICA [16]. In two other cases, the VA repositioning technique was utilized with good clinical outcome [11]. MVD is considered when the transposition of the VA is impossible [24]. The use of a Gore-Tex vascular prosthesis makes possible brainstem decompression with concurrent repositioning of the offending VA without the need for stitching. The use of a Gore-Tex vascular graft as a separating material is not common. Nevertheless, this method has been successfully applied for MVD at our Department for many years. Midline suboccipital craniectomy was employed in cases for whom the repositioning of two offending VA was required [17,21,23] or in a case with compression of the cervicomedullary junction [18,21]. The far-lateral approach and the retrosigmoid approach were used in cases of ipsilateral decompression of the medulla or compression located between the cervicomedullary and pontomedullary junctions (Table 1).

The literature review made possible a statistical analysis of potential relations between the outcomes of surgery and factors such as age, gender, the sides of the conflict (bilateral or unilateral), symptomatic period, VA characteristics and

Table 2 – The success rate of at least gradual improvement depending on baseline variables.

Variable	Improvement		OR	95%CI	p
	At least gradual, n = 27	At most partial, n = 7			
Age (per 1 year)	52.3 ± 13.5	45.3 ± 19.2	1.03	0.98–1.10	0.267
Age years:					
≤40	63.6%	36.4%	1.00		
>40	87.0%	13.0%	3.81	0.68–21.4	0.129
Gender:					
Female	75.0%	25.0%	1.00		
Male	81.1%	18.2%	1.50	0.28–8.19	0.640
Treatment:					
MVD	58.3%	41.7%	1.00		
VA	90.9%	9.1%	7.14	1.12–45.5	0.038
Symptomatic period (per 1 year)	2.6 ± 2.7	0.6 ± 0.5	2.62	0.26–26.9	0.418
VA characteristics:					
Dolichoectatic	80.0%	20.0%	1.00		
Normal VA	79.0%	21.1%	0.94	0.18–5.02	0.940
Sides ^a	–	–	–	–	0.961

^a –: n/a (not applicable due to the number of patients).

Table 3 – Success rate of rapid improvement depending on baseline variables.

Variable	Improvement		OR	95%CI	p
	Rapid	Nonrapid			
Age ^a (per 1 year)			0.98	0.93–1.03	0.369
Age years:					
≤40	54.6%	45.5%	1.00		
>40	47.8%	52.2%	0.76	0.18–3.23	0.714
Gender:					
Female	33.3%	66.7%	1.00		
Male	59.1%	40.9%	2.89	0.66–12.6	0.158
Treatment:					
MVD	33.3%	66.7%	1.00		
VA	59.1%	40.9%	2.89	0.66–12.6	0.158
Symptomatic period ^a (per 1 year)			2.26	1.09–4.72	0.029
VA characteristics:					
Dolichoectatic	66.7%	33.3%	1.00		
Normal VA	36.8%	63.2%	0.29	0.07–1.21	0.089
Sides:					
Unilateral	50.0%	50.0%	1.00		
Bilateral	50.0%	50.0%	1.00	0.17–5.83	1.000

^a –: significant levels for linear and nonlinear relation were included in Fig. 2.

treatment method (see Tables 2 and 3 and Fig. 2). Logistic regression and generalized additive models were used to assess the success rate (expressed by odds ratio) depending on qualitative and quantitative variables, respectively. Analysis was performed using SAS System 9.4 and S-Plus 6.1. Taking into account the qualitative character of the outcome variable, a subgroup of patients was identified, who showed at the most a partial improvement in neurological status ($n = 7$) and this group was compared with the group of the rest of the patients (gradual or rapid improvement, $n = 27$). Next, a subgroup of patients was identified, who did not achieve rapid improvement and this group was compared with the group of the rest of the patients. Comparing the group of patients whose neurological status showed gradual or rapid improvement with the group of the rest of the patients, it was found that the chance of achieving at least gradual improvement was significantly higher in the group operated with the VA repositioning method (OR = 7.14, 95%CI: 1.12–45.5, $p < 0.038$).

Comparing the group of patients who achieved rapid improvement with the group of patients who did not achieve rapid improvement, it was found that the chance of achieving rapid improvement was significantly associated with the duration of the symptoms. The chance of achieving rapid improvement was more than two times higher as calculated for each year of duration of the symptoms (OR = 2.26, 95%CI: 1.09–4.72, $p < 0.029$). In the group of normal VA in comparison with dolichoectatic, the risk of achieving total improvement was, on the border of statistical significance, 71% less (OR = 0.29, 95%CI: 0.07–1.21, $p < 0.089$). For two quantitative variables (age and symptomatic period), statistical analysis was performed to test the linear and nonlinear relationship between these variables and the chance of rapid improvement. There were no nonlinear trends between rapid improvement and baseline variables (significant levels are included in Fig. 2).

A temporary improvement followed by deterioration of the neurological condition was reported in two patients [16,22]. In

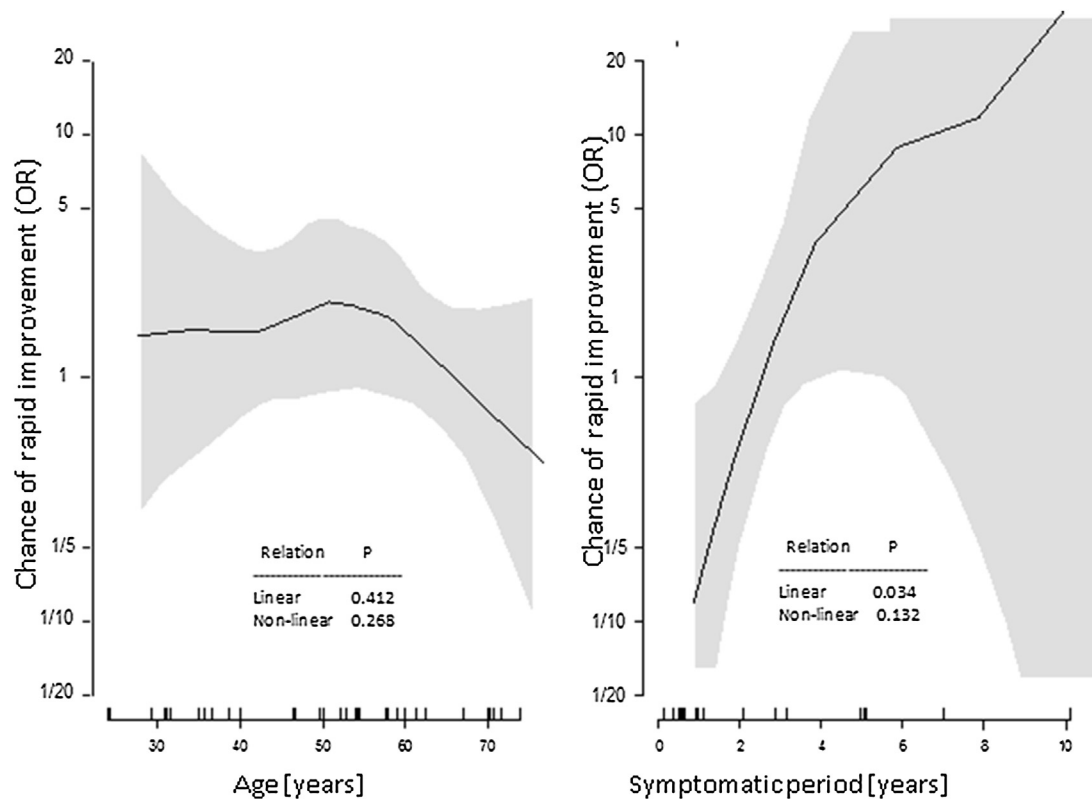


Fig. 2 – Age and symptomatic period as predictors of rapid improvement.

another case, the primary symptoms recurred [5], and the surgery did not have an effect on the neurological status in another [15]. Another three patients exhibited partial improvement after surgical treatment [5,12,25] with the occurrence of new neurological deficits in one of them [5]. In the remaining patients, long-term improvement was achieved, which means that the success rate amounted to 79% (27/34). Postoperative complications occurred in 6% of the patients (2/34) and included liquorrhea in a patient who underwent VA repositioning [12] and oscillopsia, dizziness and ipsilateral occipital neuralgia, deafness and tongue muscle weakness in another patient following MVD [5].

Rarely described in the literature, spontaneous resolution of VAMCS symptoms may result from their ischemic etiology, which is supported by ischemic lesions revealed by diagnostic imaging of the compressed brainstem and adjacent structures [5,15,25].

4. Conclusions

VAMCS should be considered in the differential diagnosis of hemiparesis. DTI seems to be an important diagnostic modality in the case of VAMCS. Microvascular decompression using a Gore-Tex vascular prosthesis as a separating material may be an efficient method to treat VAMCS. However, the results of the statistical analysis favor VA repositioning over the MVD technique in terms of satisfactory clinical outcomes.

Conflict of interest

None declared.

REFERENCES

- [1] Jannetta PJ. Arterial compression of the trigeminal nerve at the pons in patients with trigeminal neuralgia. *J Neurosurg* 1967;26(1 Pt 2):159–62.
- [2] Jannetta PJ. Neurovascular compression in cranial nerve and systemic disease. *Ann Surg* 1980;192(4):518–24.
- [3] Reuther G, Masur H, Müller S, Fahrendorf G. Assessment of vascular grooves at the brainstem. *Eur Radiol* 1992;2(2): 148–53.
- [4] Kim P, Ishijima B, Takahashi H, Shimizu H, Yokochi M. Hemiparesis caused by vertebral artery compression of the medulla oblongata: case report. *J Neurosurg* 1985;62(3): 425–9.
- [5] Savitz SI, Ronthal M, Caplan LR. Vertebral artery compression of the medulla. *Arch Neurol* 2006;63(2): 234–41.
- [6] Resta M, Gentile MA, Di Cuonzo F, Vinjau E, Brindicci D, Carella A. Clinical-angiographic correlations in 132 patients with megadolichovertebrobasilar anomaly. *Neuroradiology* 1984;26(3):213–6.
- [7] Ejma M, Koszewicz M, Podemski R, Marianska K, Budrewicz S, Turek T. Anatomical variation of the vertebral artery clinically mimicking myasthenia gravis. *Neurol Sci* 2011;32(4): 715–7.

- [8] Fein JM, Frishman W. Neurogenic hypertension related to vascular compression of the lateral medulla. *Neurosurgery* 1980;6(6):615–22.
- [9] Nakahara Y, Kawashima M, Matsushima T, Kouguchi M, Takase Y, Nanri Y, et al. Microvascular decompression surgery for vertebral artery compression of the medulla oblongata: 3 cases with respiratory failure and/or dysphagia. *World Neurosurg* 2014;82(3):535–611.
- [10] Hoffman RM, Stiller RA. Resolution of obstructive sleep apnea after microvascular brainstem decompression. *Chest* 1995;107(2):570–2.
- [11] Hongo K, Nakagawa H, Morota N, Isobe M. Vascular compression of the medulla oblongata by the vertebral artery: report of two cases. *Neurosurgery* 1999;45(4):907.
- [12] Tomasello F, Alafaci C, Salpietro FM, Longo M. Bulbar compression by an ectatic vertebral artery: a novel neurovascular construct relieved by microsurgical decompression. *Operat Neurosurg* 2005;56(1):117–24.
- [13] Salvi F, Mascialchi M, Bortolotti C, Meletti S, Plasmati R, Rubboli G, et al. Hypertension, hyperekplexia, and pyramidal paresis due to vascular compression of the medulla. *Neurology* 2000;55(9):1381–5.
- [14] Sadashiva N, Shukla D, Bhat DI, Devi BI. Vertebral artery dolichoectasia with brainstem compression: role of microvascular decompression in relieving pyramidal weakness. *Acta Neurochir (Wien)* 2016;158(4):797–801.
- [15] Vanikieti K, Cheecharoen P, Jindahra P, Lueangaram S, Padungkiatsagul T. Atypical oculopalatal tremor as the presentation of vertebral artery dolichoectasia. *Int Med Case Rep J* 2016;9:273–7.
- [16] Hongo K, Kobayashi S, Hokama M, Sugita K. Vertebral artery section for treating arterial compression of the medulla oblongata: case report. *J Neurosurg* 1993;79(1):116–8.
- [17] Kobayashi T, Ogawa A, Kameyama M, Uenohara H, Yoshimoto T. Chiari malformation with compression of the medulla oblongata by the vertebral arteries: case report. *J Neurosurg* 1992;77(2):307–9.
- [18] Vincentelli F, Caruso G, Rabehanta PB, Rey M. Surgical treatment of a rare congenital anomaly of the vertebral artery: case report and review of the literature. *Neurosurgery* 1991;28(3):416–20.
- [19] Gorton L, Ashour AM, Lebovitz J, Di AC, Abdulrauf SI. Intractable vomiting caused by vertebral artery compressing the medulla: a case report. *J Craniovertebr Junction Spine* 2015;6(2):89–91.
- [20] Hänggi D, Steiger HJ. Symptomatic vertebral artery conflicts to the medulla oblongata and microsurgical treatment options: review of the literature. *Neurosurg Rev* 2009;32(2):143–9.
- [21] Koyama S. Lower medulla and upper cervical cord compression caused by bilateral vertebral artery. Case illustration. *J Neurosurg* 2001;94(2 Suppl.):337.
- [22] Maruyama K, Tanaka M, Ikeda S, Tada T, Yanagisawa N. A case report of quadriplegia due to compression of the medulla oblongata by the elongated left vertebral artery. *Rinsho Shinkeigaku* 1989;29(1):108–11.
- [23] Murata H, Waga S, Kojima T, Shimizu T, Shimizu S. Medulla oblongata compression by tortuous vertebral artery: case report. *No Shinkei Geka* 1995;23(4):349–53.
- [24] Takano S, Saitoh M, Miyasaka Y, Fujii K, Takagi H. A case report of hemiparesis due to compression of the medulla oblongata by an elongated vertebral artery. *No Shinkei Geka* 2001;29(3):247–51.
- [25] Ubogu EE, Chase CM, Verrees MA, Metzger AK, Zaidat OO. Cervicomedullary junction compression caused by vertebral artery dolichoectasia and requiring surgical treatment: case report. *J Neurosurg* 2002;96(1):140–3.
- [26] Kamada T, Tateishi T, Yamashita T, Nagata S, Ohyagi Y, Kira J. A case of medulla oblongata compression by tortuous vertebral arteries presenting with spastic quadriplegia. *Rinsho Shinkeigaku* 2012;53(5):356–61.
- [27] Meyer MA, David CE, Chahin NS. Palatal myoclonus secondary to vertebral artery compression of the inferior olive. *J Neuroimaging* 2000;10(4):221–3.
- [28] Hung PE, Shen CC. Neurovascular decompression for lateral medullary syndrome caused by vertebral artery dolichoectasia. *J Med Sci* 2011;31(6):283–8.
- [29] Pereira-Filho AA, Faria MB, Bleil C, Kraemer JL. Brainstem compression syndrome caused by vertebrobasilar dolichoectasia: microvascular repositioning technique. *Arq Neuropsiquiatr* 2008;66(2B):408–11.
- [30] Rahimi SY, Shakir AR, Alleyne CH. Brainstem compression by “kissing vertebral arteries”. *Neurology* 2008;71(12):954.