

Available online at www.sciencedirect.com

ScienceDirect

journal homepage: <http://www.elsevier.com/locate/pjnns>

Original research article

The 'radical combined approach' in cerebral arteriovenous malformation treatment: Technical note



Umit Kocaman ^a, Tayfun Dalbasti ^b, Utku Mahir Yildirim ^c, Hakan Yilmaz ^{d,*}

^a Izmir Cigli Education and Research Hospital, Department of Neurosurgery, Izmir, Turkey

^b Ege University Faculty of Medicine, Department of Neurosurgery, Izmir, Turkey

^c University of Izmir of Medicine, Department of Interventional Radiology, Izmir, Turkey

^d Usak State Hospital, Department of Neurosurgery, Usak, Turkey

ARTICLE INFO

Article history:

Received 26 April 2016

Accepted 3 August 2017

Available online 12 August 2017

Keywords:

Arteriovenous malformation

Interventional treatment

Radical combined approach

ABSTRACT

AVMs are vessel anomalies where a connection between arterial and venous systems is present and the capillary bed is absent between the two. AVMs tend to present with seizures, headaches, focal neurological deficits and hemorrhage. Hemorrhage is the most common form of presentation. AVM's have a 2–4% annual risk of hemorrhage. Certain studies report this rate as 1%. The greatest discussion in AVM treatment is whether to use interventional treatment or monitor with medical treatment. There are 3 modalities that can be used for interventional treatment; microsurgical resection, endovascular embolization and stereotactic radiosurgery. Combined techniques are also possible. We defined the 'radical combined approach' combines embolization and microsurgery. We will discuss this procedure in this article as we believe it has several advantages.

© 2017 Polish Neurological Society. Published by Elsevier Sp. z o.o. All rights reserved.

1. Introduction

AVMs are vessel anomalies where a connection between arterial and venous systems is present and the capillary bed is absent between the two [1]. They emerge with the persistence of arteriovenous shunts that do not contain a capillary bed during the fetal period [2]. They consist of three main components: feeder arteries, the nidus, and draining veins. The nidus includes the artery, vein and cavernous channels [3]. Parenchymal areas are present in AVMs but they are not

functional [4]. These lesions are thought to be present at a rate of 0.1% in the general population. According to the autopsy studies, 12% become symptomatic during life [5]. AVMs tend to present with seizures, headaches, focal neurological deficits and hemorrhage. Hemorrhage is the most common form of presentation [6]. The annual risk of hemorrhage related to AVMs is around 2–4% [7,8]. Certain studies report this rate as 1% [9,10].

The greatest discussion in AVM treatment is whether to choose interventional treatment or monitor them with medical treatment [11]. There are 3 modalities that can be

* Corresponding author.

E-mail address: dr_hakanyilmaz@hotmail.com (H. Yilmaz).

<http://dx.doi.org/10.1016/j.pjnns.2017.08.001>

0028-3843/© 2017 Polish Neurological Society. Published by Elsevier Sp. z o.o. All rights reserved.

used for interventional treatment: microsurgical resection, endovascular embolization and stereotactic radiosurgery. Multimodality treatment of AVM was defined previously [12-14]. We defined the 'radical combined approach' that combines embolization and microsurgery and describes the principle of using the tool techniques on the same day. This procedure has not been described before. We used radical combined approach in 11 AVM cases between 2013 and 2015. These cases consisted of 4 patients with Spetzler-Martin grade 2, 5 patients with grade 3, and 2 patients with grade 4 cases.

2. Operative procedure

Pre-operative preparation was performed. All patients underwent four-vessel cerebral angiography. All imaged were evaluated by the neurosurgery and interventional radiology departments.

After the patient is administered, general anesthesia with intratracheal intubation, central, venous and arterial vascular access was ensured. The endovascular embolization procedure was then started. Once the guiding catheter was inserted into a suitable feeder artery, the lesion was accessed with a microcatheter. The microcatheter was advanced as far as possible inside the nidus and liquid embolic agent (Onyx) was administered into the lesion. The catheter was withdrawn and the procedure ended when reflux was present on the catheter. This was performed for each feeder artery individually and maximal embolization ensured in a single session. Next, the patient was taken to the neurosurgery operating room while still under anesthesia and appropriate position for operation was given. A proper craniotomy was performed, the dura was opened carefully and the AVM nidus that had turned acutely into a mass was circumferentially dissected from normal brain tissue. We already knew the preoperative location in the lesion of any superficial or deep feeder arteries that had not been closed and

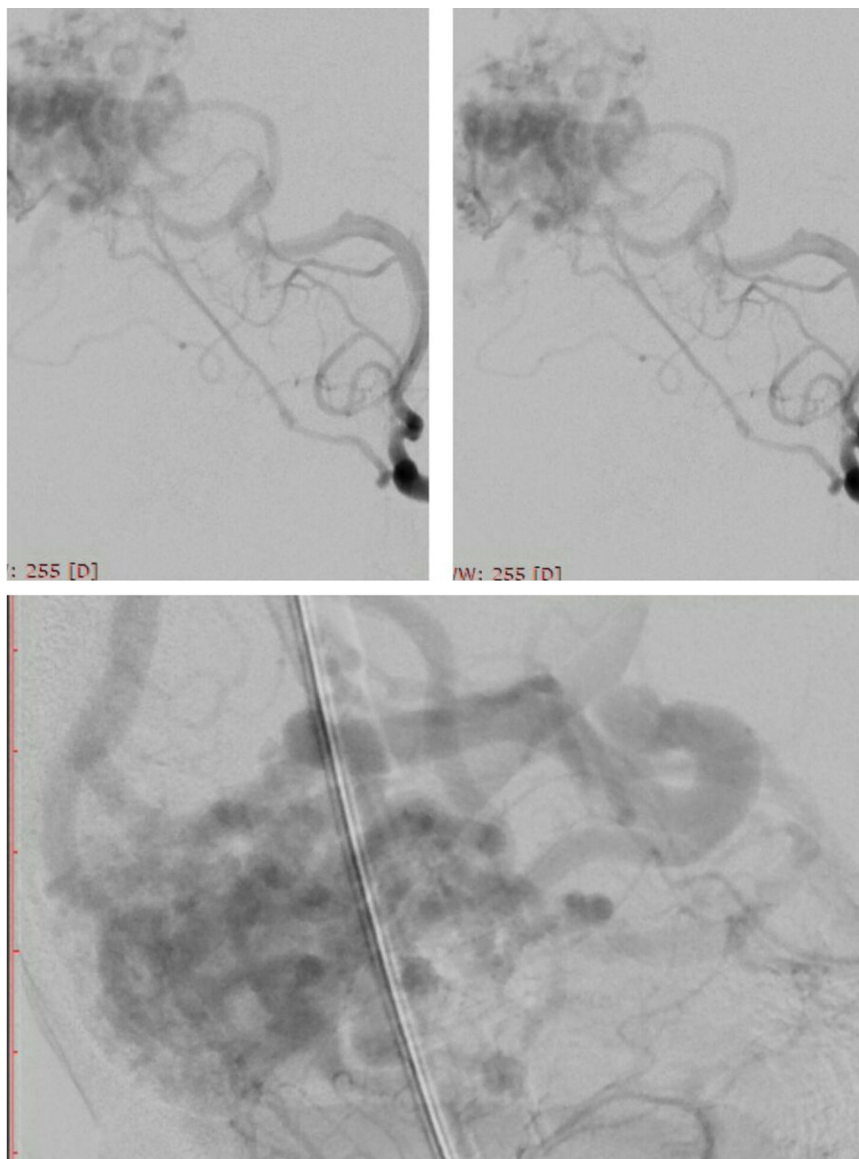


Fig. 1 – Preoperative DSA images.

this provided a significant safety margin. Bleeding control was performed after the excision of the entire nidus. The patient was taken to intensive care to recover slowly in the postoperative period. We present the images of our Spetzler–Martin grade 4 patient below (Figs. 1–5). In the postoperative period, there was no mortality and no permanent neurological deficit.

3. Discussion

The combined method we implemented brings a radical solution to AVM treatment. What we want to emphasize with the word 'radical' is a safe and complete treatment at one session. The patient is taken to the operating room without being awakened after maximum embolization and the AVM resection is performed. AVM treatment should be planned with the patient due to its morbidity and mortality risks during as well as after the treatment. The most important point of discussion is still whether to use interventional treatment or just follow-up. Most recent prospective studies report the annual hemorrhage rate of AVMs as 1%, unlike the general knowledge [9,10]. If the physician and the patient decide for AVM eradication despite its risks, there are three main methods: 1) microsurgical excision, 2) endovascular embolization, 3) stereotactic radiotherapy. These three methods can be used alone or in combination [13,14]. We should emphasize in particular that the ARUBA study revealed medical treatment alone to be superior to medical and interventional treatment in terms of death or stroke rates. This was the result of 33 months of follow-up [11]. The opinion of the patient about

the treatment will of course be the most important factor in the final decision.

Microsurgery is the gold standard in AVM treatment. It includes the craniotomy, careful dural opening, and circumferential dissection to ensure the total removal of the AVM nidus. The biggest advantage of surgery is the high total obliteration rate. The limitations are anatomical accessibility, edema due to retraction, intraoperative rupture, normal brain tissue resection, and the risk of thrombosis in the blood vessels supplying the normal parenchyma. The surgical mortality rate was 0–12.2% and the permanent morbidity rate was 5.9–14.7%. Surgical morbidity and mortality rates are consistent with the Spetzler–Martin grading [15,16]. Vascular damage develops after the administration of high-dose localized radiation to the

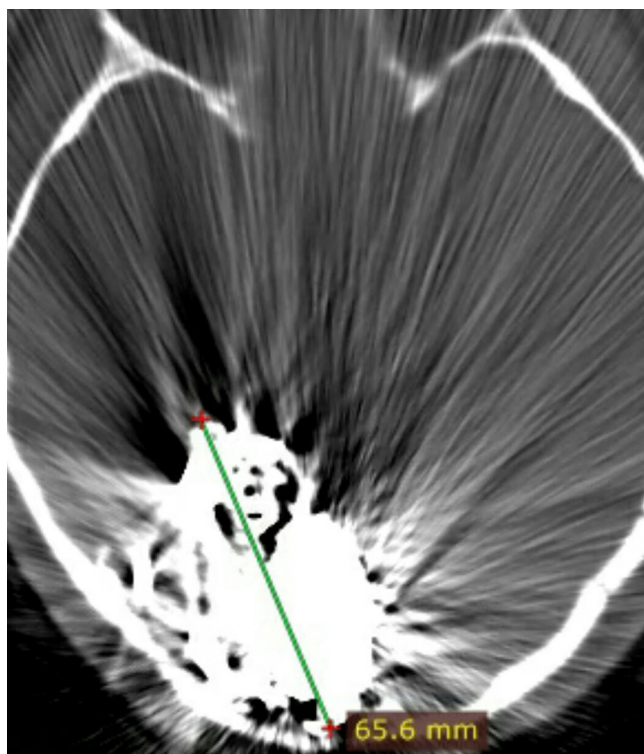


Fig. 2 – Cranial tomography images taken while the patient was asleep after the embolization and before being taken to the operation room.

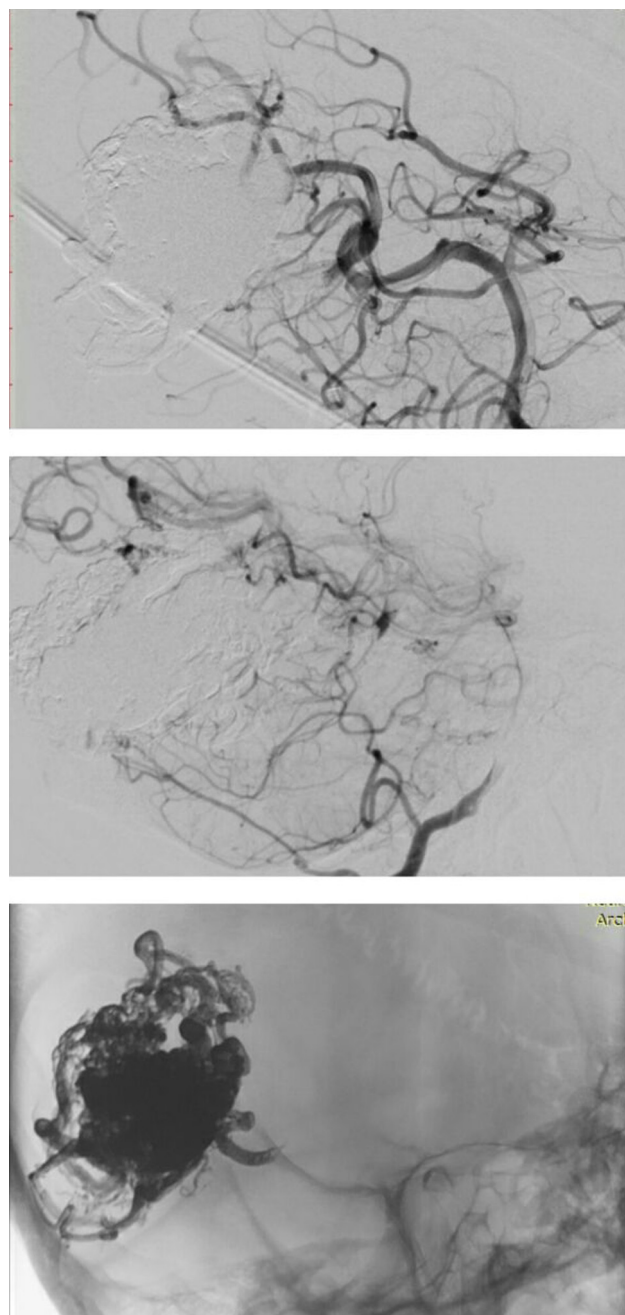


Fig. 3 – Post-embolization and preoperative DSA images.

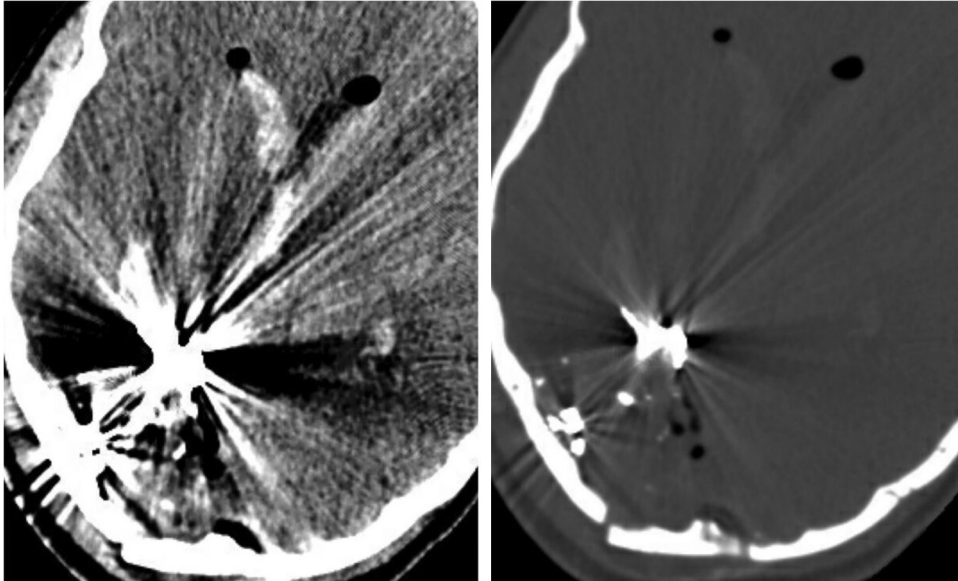


Fig. 4 – Postoperative 1st day cranial tomography images.

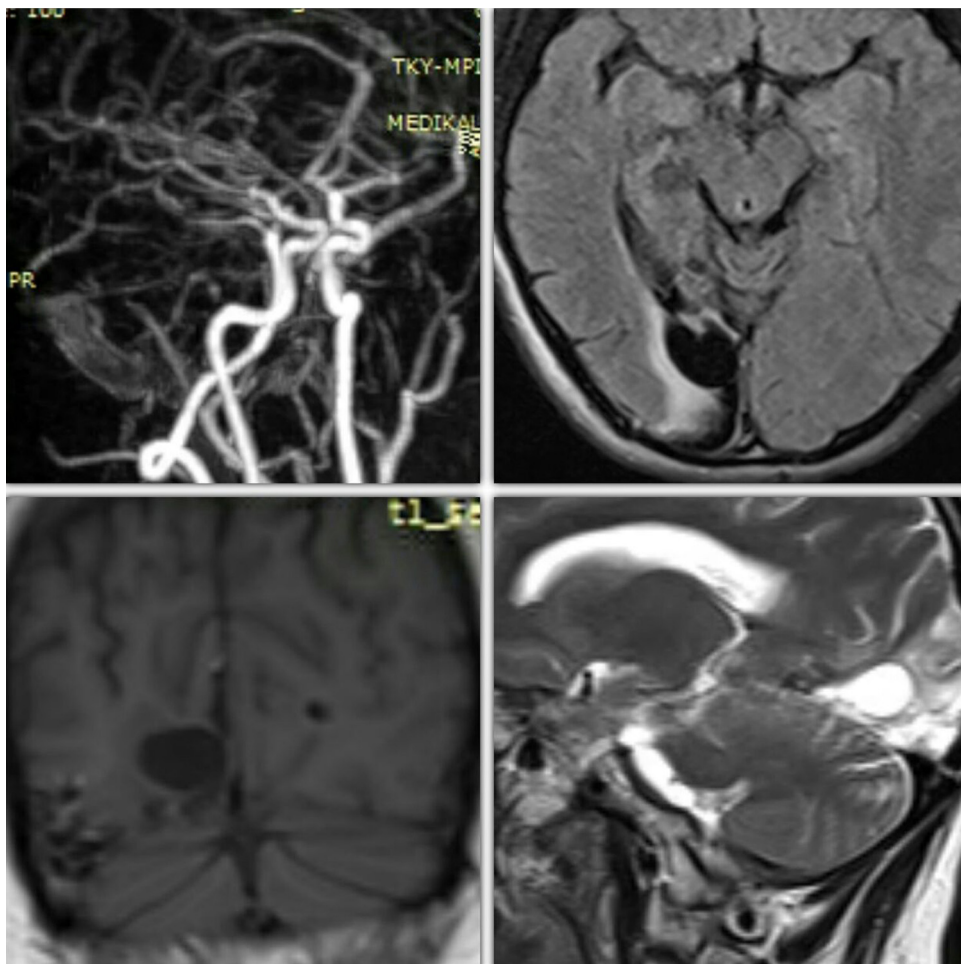


Fig. 5 – Cranial MR and MR angiography. Images 6 months after the treatment (showing total obliteration).

AVM during radiosurgery. This gradual sclerosis in the vascular structures results in vascular obliteration during a period of approximately 2–3 years. However, the patient is vulnerable to hemorrhage while obliteration is developing during this period. The annual rate of hemorrhage in these patients is the same as the natural course [17]. The morbidity and death rates in Spetzler–Martin grade 1–3 patients was less with microsurgery than with radiosurgery in the series of Pikus et al. [18]. The morbidity rate after radiosurgery is around 11.1% [19]. The treatment can be performed pre-operatively with embolic agents. This method decreases the AVM size and also decreases the rate of clinically significant complications to 6.5% [20]. It can be used to shrink the AVM to the appropriate size before radiosurgery [21]. The main strategy in pre-microsurgical embolization is the elimination of deep arterial feeders that are often seen at the final stage of the surgery and the elimination of AVM-related aneurysms away from the resection field. Certain interventional radiologists close all accessible arterial pedicles. This constitutes the first stage of our radical combined treatment. The closure of all arterial pedicles is controversial [22–24]. The general approach is to close one arterial pedicle each week. It is believed this method stabilizes local and regional hemodynamics. Besides, iatrogenic arterial and venous thrombosis for AVM treatment develops quickly in a wide area and can cause secondary hemorrhage. A hemorrhage can occur with the hemorrhagic infarct mechanism. Progressive embolization decreases this risk [12,25,26]. This forms the basis of our approach. Once the entire AVM nidus, feeders and drainage veins are closed with maximum embolization, the rate of hemorrhage is very high, especially in those with a large drainage vein. There is also a risk of hemorrhage with partial embolization performed with the closure of a feeder every week. For instance, this risk will be three times as high in an AVM nidus with 3 feeders. In our 'radical combined approach', the patient is taken to the surgery immediately without being awakened after maximum embolization and craniotomy is performed quickly. Besides, filling the AVM nidus with liquid embolizing agent turns the AVM into a somewhat acute tumor and the AVM borders are significantly more distinct during the surgery. Perinidal edema can occur with acute tumor formation. Craniotomy performed immediately after embolization also creates a safety zone regarding this matter. Risks such as hemorrhage and perinidal edema are also present with partial embolization.

Another benefit of the radical combined approach is the patient receiving general anesthesia only once. This protects the patient from the risks and psychological burden of repeated general anesthesia.

Another benefit of the radical combined approach is that the AVM nidus filled with liquid embolizing agent becomes similar to a tumor and its borders can be determined easily. In addition, the characteristic small flashes of light and smell after the contact of embolizing agent with bipolar cautery make determining AVM borders during circumferential dissection significantly easier. The AVM nidus can be handled just like a meningioma.

Another benefit of the radical combined approach is that the possibility of intraoperative AVM rupture is minimized. Less bleeding and safer surgery can be possible. Besides, any non-embolized feeders can also be closed surgically.

We believe this is a safe and appropriate treatment method for the treatment of AVMs as the procedure can be completed in a single session and the psychological burden of the patient is alleviated.

4. Conclusion

We created a safe interval for complications such as hemorrhage and edema that may be seen with partial embolization in the radical combined approach. AVM treatment was completed in a single session. Thus, recurrent risks are not encountered and the psychological burden of the patient is decreased. Circumferential dissection is easier with this method and the probability of rupture is lower. We believe that the 'radical combined approach' combines embolization and microsurgery in the best possible way. One should always follow the general follow-up and treatment principles of neurosurgery at all stages.

Conflict of interest

None declared.

Acknowledgement and financial support

None declared.

REFERENCES

- [1] Osborn AG. Intracranial vascular malformations. In: Osborn AG, editor. *Diagnostic neuroradiology*. Mosby Year Book: St. Louis; 1994. p. 284–301.
- [2] Marin-Padilla M. Vascular malformation of the central nervous system: embryological considerations. In: Yaşargil MG, editor. *Microneurosurgery*, vol. 3A. Stuttgart: Thieme; 1987. p. 23–47.
- [3] Martin NA, Vinters HV. Arteriovenous malformations. In: Carter LP, Spetzler RF, Hamilton MG, editors. *Neurovascular surgery*. New York: McGraw-Hill; 1995. p. 875–902.
- [4] Burger PC, Sheithauer BW, Vogel FS. Cerebrovascular disease. In: Burger PC, Sheithauer BW, Vogel FS, editors. *Surgical pathology of the nervous system and its coverings*. Churchill Living Stone: New York; 1991. p. 439–67.
- [5] Brown Jr RD, Wiebers DD, Torner JC, O'Fallon WM. Frequency of intracranial hemorrhage as a presenting symptom and subtype analysis: a population-based study of intracranial vascular malformations in Olmsted County, Minnesota. *J Neurosurg* 1996;85:29–32.
- [6] Arteriovenous Malformation Study Group. Arteriovenous malformations of the brain in adults. *N Engl J Med* 1999;340:1812–8.
- [7] Crawford PM, West CR, Chadwick DW, Shaw MD. Arteriovenous malformations of the brain: natural history in unoperated patients. *J Neurol Neurosurg Psychiatry* 1986;49:1–10.
- [8] Graf CJ, Perret GE, Torner JC. Bleeding from cerebral arteriovenous malformations as part of their natural history. *J Neurosurg* 1983;58:331–7.

- [9] Halim AX, Johnston SC. Longitudinal risk of intracranial hemorrhage in patients with arteriovenous malformation of the brain within a defined population. *Stroke* 2004;35:1697-702.
- [10] Stapf C, Mast H, Sciacca RR, Choi JH, Khaw AV, Connolly ES, et al. Predictors of hemorrhage in patients with untreated brain arteriovenous malformation. *Neurology* 2006;66:1350-5.
- [11] Mohr JP, Parides MK, Stapf C. Medical management with or without interventional therapy for unruptured brain arteriovenous malformations (ARUBA): a multicentre, non-blinded, randomised trial. *Lancet* 2014;383(February (9917)):614-21.
- [12] Ellis JA, Lavine SD. Role of embolization for cerebral arteriovenous malformations. *Methodist Debaque Cardiovasc J* 2014;10(4):234-9.
- [13] Beijnum VJ, Warp Van der HB, Buis DR, Al-Shahi Salman R, Kappelle LJ, Rinkel GJ, et al. Treatment of brain arteriovenous malformations: a systematic review and meta-analysis. *JAMA* 2011;306:2011-9.
- [14] Hartmann A, Mast H, Mohr JP, Pile Spellman J, Connolly ES, Sciacca RR, et al. Determinants of staged endovascular and surgical treatment outcome of brain arteriovenous malformations. *Stroke* 2005;36:2431-5.
- [15] Javadpour M, Al-Mahfoudh R, Mitchell PS, Kirillos R. Outcome of microsurgical excision of unruptured brain arteriovenous malformations in ARUBA-eligible patients. *Br J Neurosurg* 2016;30(December (6)):619-22.
- [16] Hong CS, Peterson EC, Ding D, Sur S, Hasan D, Dumont AS, et al. Intervention for a randomized trial for unruptured brain arteriovenous malformations (ARUBA)-eligible patients: an evidence-based review. *Clin Neurol Neurosurg* 2016;150:133-8.
- [17] Hernesniemi JA, Dashti R, Juvela S, Vaart K, Nielmela M, Laakso A. Natural history of brain arteriovenous malformations: a long term follow up study of risk of hemorrhage in 238 patients. *Neurosurgery* 2008;63(5):823-9.
- [18] Pikus HJ, Beach ML, Harbaugh RE. Microsurgical treatment of arteriovenous malformations: analysis and comparison with stereotactic radiosurgery. *J Neurosurg* 1998;88(4):641-6.
- [19] Bitaraf MA, Kataozpour R, Azar M, Nouri M, Mortazavi SA, Amiriamshidi A. Radiosurgery in treatment of cerebral arteriovenous malformation: mid-term results of 388 cases from a single center. *Asian J Neurosurg* 2017;12(2):159-66.
- [20] Ledezma CJ, Hoh BL, Carter BS, Pryor JC, Putman CM, Ogilvy CS. Complications of cerebral arteriovenous malformation embolization: multivariate analysis of predictive factors. *Neurosurgery* 2006;58(4):602-11.
- [21] Aliboye N, Chalouhi N, Starke RM, Zanaty M, Bell R. Cerebral arteriovenous malformations: evaluation and management. *Scient World J* 2014;2014:649036.
- [22] Crowley RW, Ducruet AF, Mc Dougall CG, Albuguerge FC. Endovascular advances for brain arteriovenous malformations. *Neurosurgery* 2014;74(February (Suppl. 1)):74-82.
- [23] Heros RC. Embolization of arteriovenous malformations. *J Neurosurgery* 2004;100(5):807-9.
- [24] Siddiqui AH, Chen PR, Rosenwasser RH. Endovascular therapy: indications, complications, and outcome. In: Stieg PE, Batjer HH, Samson D, editors. *Intracranial arteriovenous malformations*. New York: Informa Healthcare; 2007. p. 407-27.
- [25] Sahlein DH, Mora P, Becske T, Nelson PK. Nidal embolization of brain arteriovenous malformations: rates of cure, partial embolization, and clinical outcome. *J Neurosurg* 2012;117(July (1)):65-77.
- [26] Spetzler RF, Martin NA, Carter LP. Surgical management of large AVM's by staged embolization and postoperative excision. *J Neurosurg* 1987;67(July (1)):17-28.