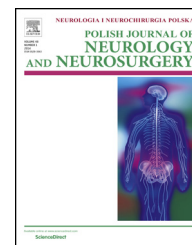


Available online at www.sciencedirect.com

ScienceDirect

journal homepage: <http://www.elsevier.com/locate/pjnns>

Original research article

Stent-assisted coiling of very small wide-necked intracranial aneurysms: Complications, anatomical results and clinical outcomes



Wenjun Ji^{a,1}, Huibin Kang^{a,b,1}, Aihua Liu^{a,*}, Youxiang Li^{a,*}, Xin Feng^a, Zenghui Qian^a, Xiaolong Wen^a, Wenjuan Xu^a, Chuhan Jiang^a, Xinjian Yang^a, Zhongxue Wu^a

^a Department of Interventional Neuroradiology, Beijing Tiantan Hospital, Beijing Neurosurgical Institute, Capital Medical University, Beijing, China

^b Department of Neurosurgery, Beijing Luhe Hospital, Capital Medical University, China

ARTICLE INFO

Article history:

Received 12 October 2015

Accepted 19 July 2016

Available online 28 July 2016

Keywords:

Intracranial aneurysm

Stent

Coiling

Very small

Wide-necked

ABSTRACT

Background and objective: Treatment of very small (≤ 3 mm) wide-necked intracranial aneurysms remains controversial, we investigated the efficacy and safety of stent-assisted coiling of such aneurysms.

Methods: From September 2008 to December 2012, 112 very small wide-necked intracranial aneurysms in 108 patients were embolized with stent-assisted coiling. We assessed the initial neurological conditions, complications and anatomic results. The follow-up results were evaluated with DSA and mRS.

Results: Stent deployment was successful in 104 of 108 procedures (96.3%). 11 complications (10.2%) occurred during procedures, including 5 events of aneurysm rupture, 3 events of thromboembolism. The rate of complication, rupture and thromboembolism was not statistically different between the ruptured and unruptured patients ($P = 0.452$, $P = 0.369$, $P = 1.000$, respectively). The initial aneurysmal occlusion was Raymond scale (RS) 1 in 34 patients (31.5%), RS2 in 53 patients (49.1%), and RS3 in 21 patients (19.4%). 79 aneurysms were available for anatomic follow-up of 12–47 months, stable occlusion in 45 aneurysms (57.0%), progressive complete occlusion in 34 aneurysms (43.0%). 95 patients (88.0%) were available for a clinical follow-up of 12–52 months, 92 patients (96.8%) had favorable clinical outcomes (mRS ≤ 2), 3 patients (3.2%) had morbidity (mRS: 3–5). The morbidity was not statistically different between the ruptured and unruptured patients ($P = 1.000$).

* Corresponding authors at: Department of Interventional Neuroradiology, Beijing Tiantan Hospital, Beijing Neurosurgical Institute, Capital Medical University, Tiantan Xili 6, Dongcheng District, Beijing 10050, China. Tel.: +86 10 67098852; fax: +86 10 65113164.

E-mail addresses: jwdoctor@sina.com (W. Ji), kanghuibin@163.com (H. Kang), liuaihua@163.com (A. Liu), liyoxiang_ttyy@126.com (Y. Li), 627440730@qq.com (X. Feng), 370453167@qq.com (Z. Qian), 371357547@qq.com (X. Wen), 841700194@qq.com (W. Xu), jiangchuhan_ttyy@126.com (C. Jiang), 1053157367@qq.com (X. Yang), wuzhongxue_yjs@126.com (Z. Wu).

¹ Wenjun Ji and Huibin Kang contributed equally to this work.

<http://dx.doi.org/10.1016/j.pjnns.2016.07.004>

0028-3843/© 2016 Polish Neurological Society. Published by Elsevier Sp. z o.o. All rights reserved.

Conclusions: Stent-assisted coiling of very small wide-necked intracranial aneurysms may be effective and safe. Because of low risk of rupture in such aneurysms, the coiling of unruptured such aneurysms must be selective. The long-term efficacy and safety of coiling such aneurysms remains to be determined in larger prospective series.

© 2016 Polish Neurological Society. Published by Elsevier Sp. z o.o. All rights reserved.

1. Introduction

The International Subarachnoid Aneurysm Trial (ISAT) provided evidence of the efficacy of coiling [1]. Endovascular coiling of intracranial aneurysms has become an efficient technique comparable to surgical clipping. However, International Subarachnoid Aneurysm Trial hasn't specifically provided the outcomes of endovascular treatment of very small (≤ 3 mm) intracranial aneurysms. To the best of our knowledge, endovascular treatment for very small intracranial aneurysms has been sporadically reported and Guglielmi detachable coiling of very small intracranial aneurysms was demonstrated to be feasible. However, this technique remains controversial for its high failure rates, especially for wide-necked and very small aneurysms, which are considered to have technically challenging and high complication rates [2,3].

Brinjikji et al. reported the results of a meta-analysis suggesting that the treatment of very small aneurysms was feasible and effective in more than 90% of treated aneurysms [4]. However, that study did not clearly show the results of very small intracranial aneurysms with wide-necked. In the present study, to investigate the feasibility and efficacy of stent-assisted coiling of very small aneurysms with a maximum aneurysm size ≤ 3 mm and a dome-to-neck ratio < 1.5 , we reported our series of 108 patients with initial and mid-long term results of the management of very small wide-necked intracranial aneurysms using stent-assisted coiling.

2. Materials and methods

2.1. Patients

After institutional review board approval, we performed a retrospective analysis of all consecutive adult patients who underwent attempted stent-assisted coiling of intracranial aneurysms at our institution between September 2008 and December 2012 to identify embolization procedures performed in very small (maximum dimension, 3 mm) and wide-necked (dome-to-neck ratio < 1.5) intracranial aneurysms. The indication for treatment and its modality were based on characteristics of individual patients and aneurysms through interdisciplinary decision making by a neurovascular team, offering endovascular embolization as a primary treatment. For ruptured very small aneurysms, the patients with older age, and the aneurysms located in the posterior circulation were included. For very small unruptured intracranial aneurysms, patients included for treatment were according to results of International Study of Unruptured Intracranial Aneurysms (ISUIA) and Unruptured Cerebral Aneurysm Study (UCAS) of Japan [5–7]. Aneurysms with irregular shape, located

in anterior communicating artery and posterior communicating artery, aneurysm size increasing after dynamic imaging follow-up, and multiple aneurysms with previous subarachnoid hemorrhage were included. Furthermore, patient preferences were also considered.

All patients provided approval for the use of their medical records for retrospective analysis. Patients were identified through a search of angiographic records and then further identified on the basis of the size of their intracranial aneurysms. For each patient, demographic data, clinical presentation, clinical outcome, aneurysm size and dome-to-neck ratio measured by 3D digital subtraction angiography (DSA), aneurysm rupture status, and aneurysm location were collected. For patients who presented with subarachnoid hemorrhage, Hunt and Hess scores were provided by the neurology team who was responsible for the management of the patients.

2.2. Endovascular procedure and complications

Patients with unruptured aneurysms or ruptured aneurysms in the nonacute phase were premedicated for 3 days prior to the procedure with dual antiplatelet therapy consisting of aspirin (100 mg/d) and clopidogrel (75 mg/d). Patients with acutely ruptured aneurysms were loaded with clopidogrel (300 mg) and aspirin (300 mg) before the procedure.

Patients typically were treated while under general anesthesia. Typically, 6F or 8F guiding catheters (Envoy, Codman, Miami Lakes, FL, USA) were placed into the internal carotid or vertebral arteries. All of the DSA examinations were performed by using a biplane, digital angiography suite (Integris Philips Medical Systems, Best, Netherlands). A volume of 24(18) ml of nonionic contrast medium was injected through a 6–8 F catheter by use of an injector with a velocity of 4(3) ml/s. Biplane DSA images of the entire circulation were usually performed, followed by “working-projection” DSA. A coaxial technique was used for microcatheter and stent catheter access. We navigated the microcatheter (Prowler select plus, Codman, Fremont, CA, USA; Renegade microcatheter, Stryker Neurovascular, Fremont, CA, USA; Headway-21, eV3, Irvine, CA, USA) over a standard microguidewire (Traxcess14, Microvention, Aliso Viejo, CA, USA; Synchro14, Boston Scientific, Fremont, CA, USA) as distally as possible beyond the aneurysm neck. Another steam-shaped microcatheter (Prowler-14, Cordis Neurovascular, Bridgewater, NJ, USA) or Echelon-10 (eV3, Irvine, CA, USA) was navigated into the aneurysm dome or near the neck. Positioning of the microcatheters, a coil was partially deployed into the aneurysm sac, and then the stent and delivery system were advanced beyond the neck within the microcatheter. The stent was semi-deployed or fully deployed. Aneurysms were coiled until there was no further evidence of angiographic contrast

filling of the aneurysm or until the microcatheter was pushed out by the coil mass. After the completion of embolization, and all stents were fully deployed. Of 112 aneurysms, 108 stents were used (Leo stent, Balt, Montmorency, France; Solitaire stent, eV3, Irvine, CA, USA; Enterprise stent, Codman Neurovascular, Miami Lakes, FL, USA; Neuroform stent, Boston Scientific/Target Therapeutics, Fremont, CA, USA). We used bare platinum coils for most of the patients in this series including the Orbit Detachable Coil System (Cordis Neurovascular, Miami Lakes, FL, USA), Gugleilmi detachable coils (Boston Scientific, Fremont, CA, USA), Microplex (Microvention, Aliso Viejo, CA, USA). Axiom 3D and Helix (eV3, Irvine, CA, USA) or a combination of them. In 112 aneurysms, 1 coil was used in 75 patients, 2 coils were used in 25 patients, and 3 coils were used in 12 patients.

After the procedure, clopidogrel (75 mg/d) was given orally for 6 weeks and aspirin (100 mg/d) was given for 6 months. Periprocedural adverse events such as aneurysm rupture, thromboembolism were recorded.

2.3. Anatomic results and clinical follow-up

Patients who survived the hospital stay were routinely scheduled for a follow-up visit at 6 months, 1 year, and 3 years for follow-up with DSA. The anatomic results were evaluated with the Raymond grading system as follows: complete occlusion (Raymond Scale 1, RS1), residual neck (Raymond Scale 2, RS2) and residual aneurysm (Raymond Scale 3, RS3) [8]. Anatomic results of follow-up were classified as stable (no interval change of occlusion degree compared with the initial result), progressive complete occlusion (initially residual neck or residual aneurysm), and recurrence. Each patient's clinical status was evaluated at last follow-up using the modified Rankin Scale (mRS).

2.4. Statistical analysis

Mean and frequency data were compared using student t test and the χ^2 test or Fisher exact test, respectively. All data were statistically analyzed using SPSS16.0 statistical package (SPSS for windows, release 9.13.2007, SPSS Inc.). The significance threshold was established at $P < 0.05$.

3. Results

3.1. Patient and aneurysm characteristics

A total of 112 very small wide-necked intracranial aneurysms in 108 patients (41 male, 67 female) were embolized with

Table 1 – Baseline characteristics of the patients.

Characteristics	Patients (n, %)
Age	
Mean \pm SD	53.9 \pm 7.4
Range	31–72
Gender	
Male	41/108 (38.0%)
Female	67/108 (62.0)
Smoking	45/108 (41.7%)
Current smoker	42/45 (93.3%)
Former smoker	3/45 (6.7%)
Medical history	
Hypertension	70/108 (64.8%)
Treatment of hypertension	26/70 (37.1%)
No. of multiple aneurysms patients	4/112 (3.6%)
Ruptured aneurysm patients	56/108 (51.9%)
Hunt and Hess I-II	43/56 (76.8%)
Hunt and Hess III	12/56 (21.4%)
Hunt and Hess IV	1/56 (1.8%)
Unruptured aneurysm patients detection	52/108 (48.1%)
Screening	12/52 (23.1%)
Headache or dizziness	30/52 (57.7%)
Symptoms caused by embolic episodes	8/52 (15.4%)
Others	2/52 (3.8%)
mRS (0–2)	52/52 (100%)

stent-assisted coiling; the patients were 31–72 years of age (mean, 53.9 years). Of 112 aneurysms, 58 (51.8%) were ruptured and 54 (48.2%) were unruptured. The locations of the 112 aneurysms included: ICA-ophthalmic ($n = 58$), posterior communicating artery ($n = 27$), anterior communicating artery ($n = 6$), ICA-cavernous ($n = 5$), middle cerebral artery ($n = 3$), basilar tip ($n = 3$), ICA-carotid terminus ($n = 3$), and posterior cerebral artery ($n = 3$), anterior cerebral artery ($n = 2$), and vertebral artery ($n = 2$). The aneurysm size was 2.62 ± 0.29 mm (range, 1.8–3.0 mm) in maximum dome diameter, while the dome-to-neck ratio was 1.03 ± 0.24 (range, 0.5–1.4). [Tables 1 and 3](#) show the characteristics of the patients and aneurysms. The characteristics of the patients and aneurysms were not statistically different between the ruptured group and unruptured group ([Tables 2 and 4](#)).

3.2. Procedural feasibility and complication

Stent was successfully deployed in 104 of 108 patients (96.3%). In 4 patients (3.7%), failure to deploy the stent was due to the inability to cross the aneurysmal neck with the microcatheter (2 patients) and vessel vasospasm (2 patients).

In the 108 patients, 11 adverse events occurred during the procedure. 7 occurred in ruptured aneurysm, 4 occurred in unruptured aneurysm. The rate of procedure-related

Table 2 – Patient characteristics in unruptured and ruptured aneurysms.

Characteristics	Ruptured aneurysm	Unruptured aneurysm	P-Value
Age (mean \pm SD)	54.8 \pm 8.5	52.9 \pm 5.8	0.191 (F = 7.782)
Gender (female/male)	34/22	31/21	0.907 ($\chi^2 = 0.014$)
Smoking	25/56	20/52	0.724 ($\chi^2 = 0.175$)
Hypertension	39/56	31/52	0.614 ($\chi^2 = 0.255$)

SD: standard deviation.

Table 3 – Baseline characteristics of the aneurysms.

Characteristics	Aneurysms (n, %)
Ruptured aneurysms	58/112 (51.8%)
Unruptured aneurysms	54/112 (48.2%)
Aneurysm maximum diameter	2.62 ± 0.29 mm
Dome-to-neck ratio	1.03 ± 0.24
Anterior circulation	104/112 (92.9%)
ICA-Ophthalmic	58/112 (51.8%)
ICA-Posterior communicating	27/112 (24.1%)
ICA-Cavernous	5/112 (4.5%)
ICA-Carotid terminus	3/112 (2.7%)
Anterior communicating artery	6/112 (5.4%)
Middle cerebral artery	3/112 (2.7%)
Anterior cerebral artery	2/112 (1.7%)
Posterior circulation	8/112 (7.1%)
Basilar tip	3/112 (2.7%)
Posterior cerebral artery	3/112 (2.7%)
Vertebral artery	2/112 (1.7%)

ICA: internal carotid artery.

complication was not statistically different between ruptured and unruptured aneurysm ($P = 0.452$). 5 procedural-related ruptures (4.6%) occurred during the procedure, three of them were aneurysmal dome perforations by a microguidewire, while the other two were caused by the retrieval of a coil that migrated through the stent struts to the distal portion of the middle cerebral artery. Intraprocedural aneurysm rupture occurred more frequently in the ruptured aneurysm than it occurred in unruptured aneurysm (7.1% vs. 1.9%), but the rate of intraprocedural aneurysm rupture was not statistically different ($P = 0.369$). Three events of thromboembolisms occurred during the procedure, the rate of thromboembolism was not statistically different between the ruptured and unruptured aneurysm ($P = 1.000$). Complications including hemorrhagic and ischemic events among different stent types were not statistically significant ($P = 0.352$; $P = 0.118$). The summary of the feasibility and complication listed in [Table 5](#).

Table 4 – Aneurysm characteristics in unruptured and ruptured aneurysms.

Characteristics	Ruptured aneurysm	Unruptured aneurysm	P-Value
Aneurysm maximum diameter (mean ± SD)	2.55 ± 0.31	2.68 ± 0.27	0.586 ($F = 0.298$)
Dome-to-neck ratio (mean ± SD)	1.05 ± 0.26	1.00 ± 0.21	0.073 ($F = 3.270$)
Anterior/posterior circulation	52/6	52/2	0.173 ($\chi^2 = 1.860$)

Table 5 – Summary of periprocedural outcome of coiling.

Characteristics	n (%)	P-Value
Feasibility		
Success	104/108 (96.3%)	
Ruptured patients	54/56 (96.4%)	0.992 ($\chi^2 = 0.000$)
Unruptured patients	50/52 (96.2%)	
Failure	4/108 (3.7%)	
Ruptured patients	2/56 (3.4%)	1.000 ^a
Unruptured patients	2/52 (3.8%)	
Anatomic outcome		
RS1	34/108 (31.5%)	
RS2	53/108 (49.1%)	
RS3	21/108 (19.4%)	
(RS1 + RS2)/RS3		0.001 ($\chi^2 = 11.237$)
Ruptured patients	52/4	
Unruptured patients	35/17	
Procedure-related complications	11/108 (10.2%)	
Ruptured aneurysm	7/56 (12.5%)	0.452 ($\chi^2 = 0.564$)
Unruptured aneurysm	4/52 (7.7%)	
Intraprocedural aneurysm rupture	5/108 (4.6%)	
Ruptured aneurysm	4/56 (7.1%)	0.369 ^a
Unruptured aneurysm	1/52 (1.9%)	
Ischemic events	3/108 (2.8%)	
Ruptured aneurysms	2/56 (3.6%)	1.000 ^a
Unruptured aneurysms	1/52 (1.9%)	
Puncture site hematoma	2/108 (1.8%)	
Others	1/108 (0.9%)	
Complications based on stent types		
Neuroform	3/18 (16.7%)	0.352 ^a
Enterprise	2/42 (8.3%)	
Solitaire	2/38 (5.3%)	
Leo	1/10 (10.0%)	
Complications based on stent types		
Open cell	3/18 (16.7%)	0.118 ($\chi^2 = 2.448$)
Closed cell	5/90 (5.6%)	

RS1: complete occlusion; RS2: residual neck RS3: residual aneurysm.

^a Fisher exact test.

Table 6 – Anatomic results of follow-up according to initial occlusion.

Follow-up results	Initial occlusion			No. of aneurysms (%)
	RS1	RS2	RS3	
Stable occlusion	16	24	5	45 (57.0%)
Progressive occlusion		20	14	34 (43.0%)

RS1: complete occlusion; RS2: residual neck; RS3: residual aneurysm.

3.3. Initial anatomic results and results of follow-up

Initial aneurysm occlusion after coiling was RS1 in 34 patients (31.5%), RS2 in 53 patients (49.1%), and RS3 in 21 patients (19.4%). The rate of occlusion (RS1 + RS2) was statistically different between the ruptured group and unruptured group ($P = 0.001$).

Of 108 aneurysms, 79 (73.1%) in 76 patients were available for 12-month or longer imaging follow-up with DSA. In 28 patients with 29 aneurysms, no follow-up imaging was performed for the following reasons: follow-up refusal due to old age, financial issues, or other medical conditions (9 patients); follow-up lost (9 patients); and scheduling of a follow-up imaging study (10 patients). The mean follow-up duration was 18.9 months (range, 12–47 months). Overall, imaging follow-up revealed stable occlusion in 45 aneurysms (57.0%; 16 with RS1, 24 with RS2, and 5 with RS3 at the time of initial coiling) and progressive complete occlusion in 34 (43.0%; 20 with RS2 and 14 with RS3 at the time of initial coiling). There were no patients of aneurysmal recurrence or in-stent stenosis found during the follow-up. Initial anatomic results and results of follow-up are compared in Tables 5 and 6.

3.4. Clinical outcomes of follow-up

Of 108 patients, 95 patients were available for a clinical follow-up of 13–52 months (mean, 25.8 months), 92 patients (96.8%) had favorable clinical outcomes (mRS ≤ 2). Three patients (2.1%) had morbidity (mRS: 3–5), no aneurysms ruptured or ruptured during the follow-up, and 13 patients were lost to follow-up and could not be located. Table 7 shows the outcome of follow-up. Rates of current smoking and treatment of hypertension before and after coiling were statistically different ($P = 0.001$, $P = 0.018$). The clinical outcomes were

not statistically different between ruptured aneurysms and unruptured aneurysms for favorable outcome and morbidity ($P = 0.946$, $P = 1.000$).

4. Discussion

Endovascular coiling for the treatment of intracranial aneurysms has become a widely accepted procedure [4]. However, coiling of wide-necked and very small aneurysms (≤ 3 mm in maximum diameter and a dome-to-neck ratio < 1.5) has been considered controversial due to technical difficulties such as the dropping out of microcatheters during coil packing and the high rate of procedural aneurysm rupture [9]. For these reasons, patients with very small intracranial aneurysms were not included in the International Subarachnoid Aneurysm Trial [1]. However, with newly developed coils with better designs and smaller sizes, coiling of very small intracranial aneurysms is far safer than previously. Recent reports have shown that coiling may be an effective strategy for very small intracranial aneurysms [10,11]. In addition, stent-assisted aneurysm coiling is well established for wide-necked intracranial aneurysms, because the stent serves as a scaffold to bridge the aneurysm neck and prevent coils from protruding into the parent artery [12].

In our series, stent was successfully deployed in 104 of 108 patients (96.3%), stent deployment failed in 3.7% of patients. The results of two other studies were similar to ours [13–15]. Procedural rupture, one of the most significant complications of coiling, may be caused by perforation with the microguidewire or microcatheter, or may occur during coil placement. The clinical consequences of the rupture range from minimal to massive subarachnoid hemorrhage [16,17], resulting in permanent morbidity in 1.4% of patients and mortality in 2.4% [4]. Several earlier reports stated that the risk of intraprocedural aneurysm rupture is higher if the aneurysm is < 3 mm in maximum diameter. Jun L et al. reported an intraprocedural rupture rate of 3.8% [14]. Van Rooij et al. and Nguyen et al. reported that the intraprocedural rupture rate of very small aneurysms was more than twice (7.7%) and five times (11.7%) that of the rate of larger aneurysms, respectively [17,18]. In our series, intraprocedural rupture occurred in 5 aneurysms (4.6%), and 2 had persistent neurologic morbidity (2.1%). Several studies have shown that intraprocedural rupture rates were higher in smaller and ruptured aneurysm when

Table 7 – Clinical outcome of follow-up.

Characteristic	Patients (N = 95) before coiling	Patients (N = 95) on follow up	P-value
Current smoker/smoker	35/40	1/40	0.000 ($\chi^2 = 24.227$)
Treatment of hypertension/hypertension	34/65	65/65	0.018 ($\chi^2 = 5.613$)
mRS			
0–2		92/95 (96.8%)	
Ruptured patients		47/49 (95.9%)	0.946 ($\chi^2 = 0.005$)
Unruptured patients		45/46 (97.8%)	
3–5		3/95 (3.2%)	
Ruptured patients		2/49 (4.1%)	1.000 ^a
Unruptured patients		1/46 (2.2%)	

^a Fisher exact test.

compared with larger and unruptured aneurysms, the result is similar to us (7.1% vs. 1.9%), but our study shown no statistical difference between the ruptured group and the unruptured group, the reason may be the number of patients in this series being small. The rate of thromboembolic events in very small wide-necked aneurysm has not been evaluated thoroughly. Thromboembolic events occurred in 3.1% in the Ioanniaid et al. series [19]. The morbidity rate due to thromboembolic events was 1.3% in unruptured aneurysms and 2.1% in ruptured aneurysms in a meta-analysis [4]. In our series, the rate of thromboembolic events occurred in 2.8% of aneurysms, there was not statistical different between the ruptured and unruptured aneurysms (3.6% vs. 1.9%).

Although 74 (68.5%) aneurysms in our series were residual neck or residual aneurysm at the time of the initial coiling, no aneurysmal recurrence was seen during the angiographic follow-up. Meanwhile, 34 (43%) residual neck or residual aneurysms progressed to complete occlusion. Weber et al. were the first to report the progressive occlusion rate of 31 unruptured wide-necked aneurysms using Enterprise stent-assisted coiling [12]. They reported that the progressive occlusion was achieved in 10 of 25 patients (40%) with initial incomplete occlusion aneurysms, and the complete occlusion was achieved in 16 of 31 patients (51.6%) at the time of follow-up. Therefore, the initial complete occlusion rate (19.4%, 6 of 31), the progressive occlusion rate (40%) and the follow-up complete occlusion rate (51.6%) were lower than in our series (31.5%, 43.0% and 63.0%) with a mean 18.9-month follow-up. Based on its features, a very small aneurysm is usually embolized using only one or two coils. However, this makes the operators worry about recanalization of the aneurysm. Several previous published reports and our study showed that incomplete initial packing of very small aneurysms did not lead to a high recanalization rate in mid-long term follow-up; Furthermore, some patients become progressively more occluded with further thrombosis on angiographic follow-up. The high rate of progressive occlusion may be explained by the mechanical and physiological properties of the stent itself. The stent may also promote progressive thrombosis and offer scaffolding for reconstruction of the intimal layer of the parent artery at the aneurysm neck with respect to the mechanical, hemodynamic, and biological benefits provided by stent. These benefits can prevent coil protrusion into the parent artery, reduce flow redirection, reduce intra-aneurysmal blood flow, and promote vessel wall healing [20,21].

Goddard et al. reported four recurrences from 25 small aneurysms coiled with one coil [8]. There was no relationship between the coil embolization ratio and recurrence in that study. Gupta et al. also reported that the embolization of very small aneurysms with one or two coils resulted in thrombosis of the aneurysm despite initial loose packing [22]. Similarly, Yang et al. used undersized coil packing with a loose coil core for very small ruptured aneurysms in 12 patients, only one recurrence was noted [23]. Chalouhi et al. reported that, with the use of stent-assisted coiling, moderate and high aneurysm packing seems to provide equivalent angiographic obliteration rates [24]. In our series, There were no patients of aneurysmal recurrence and rupture, the first reason may be due to high rate (80.6%) of moderate and high packing (residual neck and complete occlusion in immediate angiography) with

stent-assisted coiling, especial for ruptured aneurysms (52/56, 92.9%). The second reason may be due to control of smoking and hypertension which related to growth and rupture of aneurysms [25,26]. The third reason may be due to low risk of rupture of the very small aneurysm. The results also need long-term follow-up.

In our series, morbidity on follow-up was 3.2%, mortality was 0%. The morbidity was not statistical different between the unruptured aneurysm and ruptured aneurysm (2.2% vs. 4.1%). The results was similar to the meta-analysis, which showed that morbidity was lower in unruptured very small aneurysms compared to ruptured aneurysm (2.5% vs. 4.0%) [4].

The ruptured very small wide-necked intracranial aneurysm is indicated to management undoubtedly, the way of intervention (surgical repairing or coiling) should be assessing by the institutional outcome and the patient's condition. However, the treatment of unruptured very small wide-necked intracranial aneurysms has to consider the low risk of spontaneous rupture of such lesions and the risks of intervention. As for unruptured very small wide-necked aneurysm, more factors must be considered. The key factor included: patient age, life expectancy, and comorbid disease; previous subarachnoid hemorrhage, family history of subarachnoid hemorrhage, or nicotine use; aneurysm size, location and lobulation; growth or de novo aneurysm formation on serial imaging; risk of treatment [27]. Those having history of subarachnoid hemorrhage, family history of subarachnoid hemorrhage, growth, multiplicity, irregular shape or with a bleb should be considered to treat. In other cases, a good option is probably to have regular imaging (DSA, CTA or MRA) follow-up to detect any modification in size or shape of the aneurysm. Which will lead to an active intervention of these aneurysms [5-7,18,27].

4.1. Strengthen and limitations

Our study has several limitations. First, the study is a retrospective research, and the number of patients in this series is small. Second, the study has selection and follow-up bias. The patients with very small unruptured intracranial aneurysms were treated in selected patients, and the percentage of angiographic follow-up for the treated patients is relatively low. Angiographic follow-up was not available due to the wide geographic distribution of our patients in China, their financial limitations, and low compliance. Third, the accuracy of measuring the size of small aneurysms has been limited and, although 3D reconstructed angiography may precisely determine the aneurysm size and volume, the subjectively defined grayscale thresholding can produce large variations in the partial size and volume calculation. Fourth, due to a lack of long-term follow-up of coiling of very small wide-necked intracranial aneurysms, we could not derive conclusions about the long-term efficacy and safety of coiling of these lesions.

5. Conclusions

The rate of complication, anatomical results and clinical outcomes of stent-assisted coiling for very small wide-necked

intracranial aneurysm was low and favorable. However, based on low risk of spontaneous rupture of such aneurysms, the coiling of unruptured such aneurysms must be cautious and in selected patients, its long-term efficacy and safety should be further evaluated in larger prospective series.

Conflict of interest

None declared.

Acknowledgment and financial support

This article was supported by the National Natural Science Foundation (No. 81441038 and No. 81371314), the Natural Science Foundation of Beijing, China (No. 7142032), the Specific Research Projects for Capital Health Development (No. 2014-3-2044 and No. 2011-1015-04).

Ethics

The work described in this article has been carried out in accordance with The Code of Ethics of the World Medical Association (Declaration of Helsinki) for experiments involving humans; Uniform Requirements for manuscripts submitted to Biomedical journals.

REFERENCES

- [1] Molyneux A, Kerr R, International Subarachnoid Aneurysm Trial Collaborative Group, Stratton I, Sandercock P, Clarke M, et al. International subarachnoid aneurysm trial (ISAT) of neurosurgical clipping versus endovascular coiling in 2143 patients with ruptured intracranial aneurysms: a randomized trial. *J Stroke Cerebrovasc Dis* 2002;11:304–14.
- [2] Cognard C, Weill A, Castaings L, Rey A, Moret J. Intracranial berry aneurysms: angiographic and clinical results after endovascular treatment. *Radiology* 1998;206:499–510.
- [3] Doerfler A, Wanke I, Egelhof T, Dietrich U, Asgari S, Stolke D, et al. Aneurysmal rupture during embolization with Guglielmi detachable coils: causes, management, and outcome. *AJNR Am J Neuroradiol* 2001;22:1825–32.
- [4] Brinjikji W, Lanzino G, Cloft HJ, Rabinstein A, Kallmes DF. Endovascular treatment of very small (3 mm or smaller) intracranial aneurysms: report of a consecutive series and a meta-analysis. *Stroke* 2010;41:116–21.
- [5] International Study of Unruptured Intracranial Aneurysms Investigators. Unruptured intracranial aneurysms – risk of rupture and risks of surgical intervention. *N Engl J Med* 1998;339:1725–33.
- [6] Wiebers DO, Whisnant JP, Huston 3rd J, Meissner I, Brown JR, Piepgras DG, et al. Unruptured intracranial aneurysms: natural history, clinical outcome, and risks of surgical and endovascular treatment. *Lancet* 2003;362:103–10.
- [7] Investigators UJ, Morita A, Kirino T, Hashi K, Aoki N, Fukuhara S, et al. The natural course of unruptured cerebral aneurysms in a Japanese cohort. *N Engl J Med* 2012;366:2474–82.
- [8] Raymond J, Roy D, Bojanowski M, Mounmdjian R, L'Esperance G. Endovascular treatment of acutely ruptured and unruptured aneurysms of the basilar bifurcation. *J Neurosurg* 1997;86:211–9.
- [9] Goddard JK, Moran CJ, Cross 3rd DT, Derdeyn CP. Absent relationship between the coil-embolization ratio in small aneurysms treated with a single detachable coil and outcomes. *AJNR Am J Neuroradiol* 2005;26:1916–20.
- [10] Tsutsumi M, Aikawa H, Onizuka M, Kodama T, Nii K, Matsubara S, et al. Endovascular treatment of tiny ruptured anterior communicating artery aneurysms. *Neuroradiology* 2008;50:509–15.
- [11] Hong B, Yang PF, Zhao R, Huang QH, Xu Y, Yang ZG, et al. Endovascular treatment of ruptured tiny intracranial aneurysms. *J Clin Neurosci: Off J Neurosurg Soc Austral* 2011;18:655–60.
- [12] Weber W, Bendszus M, Kis B, Boulanger T, Solymosi L, Kuhne D. A new self-expanding nitinol stent (Enterprise) for the treatment of wide-necked intracranial aneurysms: initial clinical and angiographic results in 31 aneurysms. *Neuroradiology* 2007;49:555–61.
- [13] Gupta V, Chugh M, Jha AN, Walia BS, Vaishya S. Coil embolization of very small (2 mm or smaller) berry aneurysms: feasibility and technical issues. *AJNR Am J Neuroradiol* 2009;30:308–14.
- [14] Kwon HJ, Park JB, Kwon Y, Ahn JS, Kwun BD. Long-term clinical and radiologic results of small cerebral aneurysms embolized with 1 or 2 detachable coils. *Surg Neurol* 2006;66:507–12.
- [15] Lu J, Liu JC, Wang LJ, Qi P, Wang DM. Tiny intracranial aneurysms: endovascular treatment by coil embolisation or sole stent deployment. *Eur J Radiol* 2012;81:1276–81.
- [16] Molyneux AJ, Kerr RS, Birks J, Ramzi N, Yarnold J, Sneade M, et al. Risk of recurrent subarachnoid haemorrhage, death, or dependence and standardised mortality ratios after clipping or coiling of an intracranial aneurysm in the international subarachnoid aneurysm trial (ISAT): long-term follow-up. *Lancet Neurol* 2009;8:427–33.
- [17] Nguyen TN, Raymond J, Guilbert F, Roy D, Berube MD, Mahmoud M, et al. Association of endovascular therapy of very small ruptured aneurysms with higher rates of procedure-related rupture. *J Neurosurg* 2008;108:1088–92.
- [18] Pierot L, Barbe C, Spelle L, A. Investigators. Endovascular treatment of very small unruptured aneurysms: rate of procedural complications, clinical outcome, and anatomical results. *Stroke* 2010;41:2855–9.
- [19] Ioannidis I, Lalloo S, Corkill R, Kuker W, Byrne JV. Endovascular treatment of very small intracranial aneurysms. *J Neurosurg* 2010;112:551–6.
- [20] Wanke I, Forsting M. Stents for intracranial wide-necked aneurysms: more than mechanical protection. *Neuroradiology* 2008;50:991–8.
- [21] Lopes D, Sani S. Histological postmortem study of an internal carotid artery aneurysm treated with the neuroform stent. *Neurosurgery* 2005;56:E416. discussion E416.
- [22] van Rooij WJ, Keeren GJ, Peluso JP, Sluzewski M. Clinical and angiographic results of coiling of 196 very small (< or =3 mm) intracranial aneurysms. *AJNR Am J Neuroradiol* 2009;30:835–9.
- [23] Yang MS, Wong HF, Yang TH, Chen YL, Chan SW, Lee HJ, et al. Alternative option in the treatment of very small ruptured intracranial aneurysms. *Surg Neurol* 2009;72 (Suppl. 2):S41–6.
- [24] Chalouhi N, Dumont AS, Hasan D, Tjoumakaris S, Gonzalez LF, Starke RM, et al. Is packing density important

-
- in stent-assisted coiling? *Neurosurgery* 2012;71:381-6. discussion 386-7..
- [25] Sonobe M, Yamazaki T, Yonekura M, Kikuchi H. Small unruptured intracranial aneurysm verification study: Suave study, Japan. *Stroke* 2010;41:1969-77.
- [26] Morita A. Current perspectives on the unruptured cerebral aneurysms: origin, natural course, and management. *J Nippon Med School Nippon Ika Daigaku Zasshi* 2014;81:194.
- [27] Brown Jr RD, Broderick JP. Unruptured intracranial aneurysms: epidemiology, natural history, management options, and familial screening. *Lancet Neurol* 2014;13:393-404.