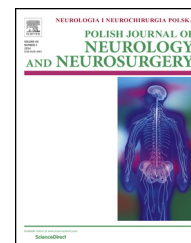


Available online at www.sciencedirect.com

ScienceDirect

journal homepage: <http://www.elsevier.com/locate/pjnns>

Original research article

Management of spinal tumors in neurofibromatosis type 2 patients

Arkadiusz Nowak^{*}, Tomasz Dziedzic, Tomasz Czernicki,
Przemysław Kunert, Andrzej Marchel

Klinika Neurochirurgii, Warszawski Uniwersytet Medyczny, Poland

ARTICLE INFO

Article history:

Received 17 June 2015

Accepted 13 November 2015

Available online 26 November 2015

Keywords:

Spinal tumor

Natural history

Neurofibromatosis type 2

ABSTRACT

Objective: We sought to determine clinical characteristics of NF2 patients with spinal lesions and to define when and like the spinal tumors are a major problem in the treatment of patients with NF2.

Methods: The authors retrospectively reviewed the clinical records, neuroimaging studies, and follow-up data of the 34 patients with neurofibromatosis type 2, who were treated at our institution between 1998 and 2014. 23 patients harbored one or multiple spinal tumors.

Results: Patients with spinal tumors had a lower age at first symptoms of the disease, a higher number of intracranial meningiomas and non-vestibular schwannomas. 11 patients had one or more intramedullary tumors with MRI characteristics of spinal ependymomas. 22 patients had intradural extramedullary tumors. 7 patients presented with symptomatic spinal tumors on admission or developed symptoms during the follow-up. Only two intramedullary and four extramedullary tumors demonstrated growth in the mean radiological follow-up period of over 6 years. It was found that symptomatic both intra- and extramedullary tumors were associated with younger age at the onset of NF2-related symptoms. 2 patients with intramedullary tumors and 12 patients with extramedullary tumors underwent their tumors resection. In case of symptomatic tumors partial recovery was observed in two patients.

Conclusion: It seems that close surveillance with MR imaging is a reasonable option for asymptomatic spinal tumors. Nevertheless, intramedullary tumor removal in non-growing and asymptomatic cases may be an option when ABI implantation is considered. Symptomatic tumors and those of documented growth should be eligible for surgical intervention.

© 2015 Polish Neurological Society. Published by Elsevier Sp. z o.o. All rights reserved.

1. Introduction

Neurofibromatosis type 2 is an autosomal dominant syndrome predisposing to multiple benign tumors of the central and

peripheral nervous system. The hallmark of this disease is the development of bilateral vestibular schwannomas, which occurs in 90–95% of patients [1–3]. Spinal NF2-associated tumors include schwannomas of spinal nerves, meningiomas and spinal cord ependymomas. Schwannomas of the spinal

^{*} Corresponding author at: Klinika Neurochirurgii, ul. Banacha 1a, 02-097 Warszawam, Poland. Tel.: +48 606 787 433; fax: +48 225991574. E-mail address: arkady.n@wp.pl (A. Nowak).

<http://dx.doi.org/10.1016/j.pjnns.2015.11.004>

0028-3843/© 2015 Polish Neurological Society. Published by Elsevier Sp. z o.o. All rights reserved.

nerve root are frequently multiple and they account for almost 90% of extramedullary spinal tumors [4,5]. Intradural, extramedullary spinal meningiomas are present in about 20% of patients [1-4]. These tumors, however, may not be distinguished radiologically or even at the time of surgery. Ependymomas account for more than 75% of intramedullary spinal cord tumors associated with neurofibromatosis type 2 [4,6-8]. Their imaging evidence is found in 18-53% of patients but they cause clinical symptoms in fewer than 20% [4-6,9]. Intramedullary astrocytomas of the spinal cord and intramedullary schwannomas have been rarely reported in NF2 [4-9]. In contrast to sporadic tumors, the majority of NF2-related spinal tumors are asymptomatic during observation. Although several previous reports concerned clinical and imaging characteristics of spinal tumors little is known about their natural history in these patients. In this study we sought to evaluate probability of growth of various spinal tumor subtypes, identify prognostic factors for symptomatic cases and establish a strategy for the management of these tumors. Moreover we aim to assess the risk and effectiveness of surgical treatment for this tumor types. We compare NF2 patients with spinal tumors to those without in order to identify differences between the two patient subgroups. We assessed clinical characteristics, growth patterns and surgical outcome of spinal tumors in NF2 patients with long-term clinical and imaging follow-up.

2. Material and methods

2.1. Patient population

34 patients with neurofibromatosis type 2, as defined on the basis of the modified National Institute of Health (NIH) Consensus Panel Criteria [10], were surgically treated at our institution between 1998 and 2014. We have retrospectively reviewed the clinical records, neuroimaging studies, and follow-up data of the treated patients. Among 34 patients, in 11 we did not identified any spinal tumors whereas 23 harbored one or multiple spinal tumors. Patients with spinal tumors were divided into those with intramedullary tumors and those with extramedullary tumors or intradural tumors of the cauda equina. Some patients were included in more than one subgroup because they had tumors in both locations. Three symptomatic spinal tumors in 3 patients

(1 meningioma in thoracic spine and 2 schwannomas in cauda equina) were resected in their childhood at another institution without sequel and were not included in the surgical treatment and growth rate analysis. We included in the natural growth study patients who harbored intra- or extramedullary spinal tumor and were observed for at least 1 year. Resected tumors were graded according to the WHO 2000 and the WHO 2007 [11] grading scheme.

2.2. Clinical and radiological follow-up

Our treatment philosophy assumed that the optimal strategy for each NF2 patient is to maintain good quality of life for as long as possible with special attention to maintain hearing. NF2 is not a one uniform illness but comprises several subtypes of tumor of the brain, spinal cord and peripheral nerves and as the spontaneous clinical course of the disease varies from patient to patient it may need different treatment strategies. The rule of conduct in every newly diagnosed case of NF2 was the performance of the brain and entire spine MRI diagnostics. Then all patients with spinal tumors had a clinical examination and spinal MRI study performed at least once a year. MRI was aimed at determining the presence of a tumor, defining its nature and in particular evaluating of any tumor growth in subsequent studies.

2.3. Statistical analysis

Data analyses were performed using Statistica version 12.0 (StatSoft) by means of Student's t-test and contingency tables using the Pearson Chi-square test or Chi-square test with Yates correction. Significance level was established at $p < 0.05$.

3. Results

3.1. Patient and tumor characteristics

There were 19 women and 15 men in the entire cohort of NF2 patients. Characteristics of the patients and the comparison between NF2 patients with spinal tumors and those without the lesions are given in Table 1. Among the 23 patients with spinal tumors non-vestibular schwannomas were significantly more frequently observed ($p < 0.05$). Besides, patients with spinal tumors had a lower age at first symptoms of the disease and had a higher number of intracranial meningiomas.

Table 1 – NF2 patients' characteristics.

| Characteristic | No. of patients (%) | | p-Value |
|--|------------------------------|-----------------------------|--------------|
| | Spinal tumor present 23 (67) | Spinal tumor absent 11 (33) | |
| Female | 14 (61) | 5 (45) | 0.63 |
| Mean age at first symptoms (SD) (years) | 19 (10.3) | 23 (9) | 0.28 |
| Bilateral vestibular schwannoma | 20 (87) | 11 (100) | 0.54 |
| Non-vestibular schwannoma | 9 (39) | 0 (0) | 0.045 |
| Intracranial meningioma | 16 (70) | 5 (45) | 0.33 |
| SD – standard deviation. | | | |
| Values in bold indicate statistical significance | | | |

Table 2 – Characteristics of patients harboring intramedullary tumors.

| Case no. | Age at first symptoms | Sex | Tumors location | Multiple tumors | Growing or symptomatic tumor | Cystic tumor | Coexisted extramedullary tumors | Coexisted intracranial meningioma |
|----------|-----------------------|-----|--------------------------------------|-----------------|------------------------------|--------------|---------------------------------|-----------------------------------|
| 1 | 28 | F | C1-C2 Th3 | (+) | | | (+) | (+) |
| 2 | 19 | F | Th9-Th11 C1 C6 | (+) | | | (+) | (+) |
| 3 | 3 | F | C1-C5 Th4-Th6 | (+) | (+) | (+) | (+) | (+) |
| 4 | 13 | F | C3 | | | | (+) | (+) |
| 5 | 36 | M | C1-C2 | | | | | |
| 6 | 10 | F | C2-C4 C7 | (+) | | | (+) | (+) |
| 7 | 16 | F | C2-C3 | | | | (+) | (+) |
| 8 | 3 | M | C2-C5 | (+) | (+) | (+) | (+) | (+) |
| 9 | 27 | M | C4-C7 | (+) | | | (+) | (+) |
| 10 | 16 | F | C1-C5 | (+) | | | (+) | (+) |
| 11 | 6 | F | C2-C3 C6-C7 Th2-Th3 Th7-Th8 | (+) | | | (+) | (+) |

3.2. Intramedullary tumors

11 patients had one or more intramedullary tumors with MRI characteristics of spinal ependymomas (Table 2). Multiple ependymomas with the MRI appearance of a “string of pearls” were seen in 8 (73%) patients. The cervical spine or cervicomedullary junction was affected in all patients. Synchronous involvement of the cervical and thoracic spine occurred in 3 (27%) patients. Only two (18%) patients had a cystic component to their ependymomas. The mean length of radiological follow-up was 6.4 ± 2.7 years (range 3–12 years). Tumor growth was observed in 2 (18%) patients. Symptoms related to the intramedullary tumor were noted in one (9%) of these patients and included small spasticity in the lower limbs with a positive Babinski sign. Before these mild symptoms of intramedullary tumor occurred, this patient had underwent

symptomatic meningioma surgery in the thoracic region. The second patient has remained asymptomatic. Tumor growth was associated with a younger age at the onset of NF2-related symptoms. During the radiological follow-up, in two patients new intramedullary spinal tumors were revealed. These tumors are asymptomatic and are subject to observation.

3.3. Extramedullary spinal tumors and cauda equina tumors

Characteristics of patients with extramedullary spinal tumors and cauda equina tumors are listed in Table 3. 22 patients had one or more intradural extramedullary tumors. In 6 patients both extramedullary and cauda equina tumors were detected. In 10 patients extramedullary spinal tumor coexisted with intramedullary tumor. Most tumors were located in the

Table 3 – Characteristics of patients harboring extramedullary and cauda equina tumors.

| Prognostic factor | | No. of patients (%) | | | p-Value |
|-------------------------------------|--------------|--------------------------------|------------------------------------|--------------------------------------|---------|
| | | Entire cohort (22 patients) | Symptomatic tumors (6 patients) | Asymptomatic tumors (16 patients) | |
| Mean age at first symptoms (years) | | 18.2 ± 9.9 | 17.2 ± 9.4 | 18.6 ± 10.3 | 0.76 |
| Age (years) | <18 | 11 | 4 (67) | 7 (44) | 0.63 |
| | ≥18 | 11 | 2 (33) | 9 (56) | |
| Sex | Female | 14 | 2 (33) | 12 (75) | 0.19 |
| | Male | 8 | 4 (67) | 4 (25) | |
| Tumor location | Cervical | 16 | 5 | 11 | 0.11 |
| | Thoracic | 12 | 1 | 11 | |
| | Lumbo-sacral | 7 | 0 | 7 | |
| Coexisted intramedullary tumor | Yes | 10 | 4 (67) | 6 (38) | 0.46 |
| | No | 12 | 2 (33) | 10 (62) | |
| Coexisted intracranial meningioma | Yes | 16 | 6 (100) | 10 (62) | 0.22 |
| | No | 6 | 0 (0) | 6 (38) | |
| Coexisted non-vestibular schwannoma | Yes | 9 | 2 (33) | 7 (44) | 0.96 |
| | No | 13 | 4 (67) | 9 (56) | |

cervical spine. Both the cervical and thoracic spine were affected in 6 patients. Among 22 extramedullary and cauda equina patients 6 were symptomatic: 4 patients had motor and sensory deficits and 2 patients presented with sensory deficits without weakness in the extremities. Three symptomatic patients presented with their symptoms on admission. In the mean radiological follow-up period of 6.7 ± 3.4 years (range 2–16 years) four tumors in 4 patients demonstrated growth. Three patients in this subgroup became symptomatic while the other one remain asymptomatic in the follow-up. It was found that symptomatic extramedullary spinal tumors were associated with coexisted intracranial meningiomas and coexisted intramedullary tumors, however, statistical analysis showed no statistical significance (Table 3). At the end of follow-up three de novo tumors (radiological appearance of meningiomas) appeared in 3 patients. These tumors, however, did not exhibit significant growth in control imaging studies and are being monitored.

3.4. Surgical treatment

3.4.1. Intramedullary tumors

Two patients underwent tumor resection. Indication for surgery was the presence of related neurological symptoms in one patient and the confirmation of a radiological progression in the second case. In the first patient the second equally important indication for surgery apart from mild neurological symptoms was the need for ABI implantation because of bilateral deafness. Complete tumor resection was achieved in both patients. Intraoperative monitoring was performed during these surgeries. Histological analysis revealed ependymomas (WHO GII) in both patients. Postoperatively, neurological function was worse in both cases. In the symptomatic patient partial neurological recovery was observed and despite the patient is ambulatory she still has mild symptoms of proximal upper extremity weakness. There is no tumor recurrence during the 4-year postoperative follow-up. In the second case of asymptomatic tumor rapid decline was observed after the operation (including tetraparesis and respiratory failure) that has been probably related to concomitant foramen magnum meningioma. On the other day meningioma was removed and the patient fully recovered. This patient developed small recurrent tumor on subsequent imaging studies three years after surgery. Since tumor recurrence is asymptomatic the patient remains in observation.

3.4.2. Extramedullary tumors and cauda equina tumors

Fifteen intradural extramedullary tumors were surgically removed in 12 patients. Histological analysis showed meningiomas and schwannomas in 13 and 2 cases, respectively. Three patients were operated twice: the second surgery for another tumor was performed 3, 9 and 15 years after the first spinal surgery. The clinical indications for surgery included 6 symptomatic cases, 7 large but asymptomatic tumors that cause spinal cord compression, 1 asymptomatic moderate-sized C1-C2 meningioma removed during expanded procedure for vestibular schwannoma and one asymptomatic tumor that proved radiological progression in the follow-up. In 11 patients postoperative period was uneventful with full neurological

recovery. However, 1 patient showed only moderate improvement and his motor deficit proved permanent. Among patients who underwent surgery the mean postoperative clinical and radiological follow-up period was 6.0 ± 4.2 years (range 2–14 years) and no patients developed recurrent tumors.

4. Discussion

Neurofibromatosis type 2 (NF2) is a heritable tumor predisposition syndrome that leads to the development of multiple intracranial and spinal tumors. About 60% of NF2 patients had single or multiple spinal tumors [3,4,6,12]. It is believed that in NF2 patients spinal tumors besides meningiomas are associated with disease severity [13].

The results of the present study tend to agree in several respects with those of previously published works on spinal tumors in patients with NF2 [4–6,9]. In the present study over 70% of NF2 patients had spinal tumors which is comparable to previously reported data [3,4,6,12]. Patients with spinal tumors had a lower age at first symptoms of the disease, higher number of intracranial meningiomas and intracranial non-vestibular schwannomas ($p < 0.05$). Among 34 patients 11 (32%) had intramedullary tumors, 22 (65%) had extramedullary tumors, and 8 (24%) had tumors of the cauda equina. In a study of Aboukais et al. [12] patients with intra-, extramedullary and cauda equina tumors accounted for 22.5, 45 and 31% of the entire NF2 cohort, respectively. Of their 48 patients with spinal tumors, 20 were symptomatic (among which prevailed extramedullary tumors) and in 17 patients the first symptom of the disease was related to spinal tumors. Authors [12] emphasize that contrary to popular belief spinal tumors in NF2 could be associated with significant morbidity. Our experience does not confirm this opinion. In the mean follow-up period of almost 7 years we found 7 symptomatic cases (one intra- and six extramedullary tumors) and only 6 patients demonstrated their tumors growth. In contrast to intramedullary tumors which are associated with less favorable functional prognosis after surgery, extramedullary tumors give the possibility of full recovery after surgical treatment.

Our study confirms that high percentage of NF2 patients with ependymomas reveal evidence of extramedullary spinal tumors and intracranial meningiomas (both in 91%) which is similar to previous reports [1,5,14]. This proves that intramedullary tumors in NF2 patients are associated with disease severity. We also found that in all patients some tumors were located in the cervical spine which is consistent with previous reports [14]. This predilection of ependymomas for cervical cord and craniomedullary junction (CMJ) is different from that for patients with sporadic tumors which are more commonly located within the brain and less common in the cervical cord [15,16]. Moreover, spinal ependymomas in NF2 patients are usually multiple and present with typical appearance of a “string of pearls” in neuroimaging. In our study, similarly to previous works [4–6,9], only two patients (18%) underwent surgical treatment for their ependymomas. In our analysis it was found that the presence of tumor-associated cysts and young age at first symptoms of NF2 may be associated with tumor growth, the occurrence of clinical symptoms and the need for surgical intervention in patients with intramedullary

tumors. However, due to small numbers of patients in our series no meaningful conclusions can be drawn. Better outcome of surgical treatment for intramedullary ependymomas has been achieved with growing but asymptomatic tumor like in sporadic intraspinal tumors [17]. The majority of our patients remained asymptomatic during an extended follow-up period. This is quite typical for NF2 patients that their ependymomas are often asymptomatic and usually encountered during routine imaging studies of the central nervous system. Our study corroborates previous reports [12,14] suggesting that most NF2 patients with ependymomas can be safely monitored without indication for surgical treatment. It should be noted, however, that even non-growing, asymptomatic intramedullary spinal tumor in patient with NF2 may be an indication for surgery: we should consider tumor removal when implantation of ABI is needed because after this procedure we lack the possibility of any tumor growth monitoring by MR imaging. Aboukais et al. [12] reported that in their three symptomatic patients operated on for intramedullary tumors, neurological recovery was only partial in two patients and absent in one. In contrast no postoperative worsening was reported for the three asymptomatic patients. This suggests that growing tumors should be considered for surgery before clinical symptoms appear. Therefore our treatment strategy in all cases of spinal cord tumors assumes strict clinical and radiological monitoring considering surgery in any case of documented tumor growth before the onset of neurological symptoms.

5. Conclusions

Spinal tumors in patients with NF2 are most commonly found in the cervical spine and are associated with the disease severity. These tumors remain asymptomatic in the long-term follow-up and rarely require surgical treatment which is especially typical of intramedullary tumors. It seems that close surveillance with MR imaging is a reasonable option for asymptomatic spinal tumors. Nevertheless, intramedullary tumor removal in non-growing and asymptomatic cases may be an option when ABI implantation is considered. Symptomatic tumors and those of documented growth should be eligible for surgical intervention.

Conflict of interest

We wish to confirm that there are no known conflicts of interest associated with this publication.

Acknowledgement and financial support

We confirm that there has been no significant financial support for this work that could have influenced its outcome.

Ethics

The work described in this article has been carried out in accordance with the Code of Ethics of the World Medical Association (Declaration of Helsinki) for experiments involving

humans; uniform requirements for manuscripts submitted to biomedical journals.

REFERENCES

- [1] Evans DGR, Huson SM, Donnai D, Neary W, Blair V, Newton V, et al. A clinical study of type 2 neurofibromatosis. *Q J Med* 1992;84:603–18.
- [2] Maunter VF, Lindenau M, Baser ME, Hazim W, Tatagiba M, Haase W, et al. The neuroimaging and clinical spectrum of neurofibromatosis 2. *Neurosurgery* 1996;38:880–6.
- [3] Parry DM, Eldridge R, Kaiser-Kupfer MI, Bouzas EA, Pikus A, Patronas N. Neurofibromatosis 2 (NF2): clinical characteristics of 63 affected individuals and clinical evidence and clinical evidence for heterogeneity. *Am J Med Genet* 1994;52:450–61.
- [4] Patronas 1st N, Courcousakis N, Bromley CM, Katzman GL, MacCollin M, Parry DM. Intramedullary and spinal canal tumors in patients with neurofibromatosis 2: MR imaging findings and correlation with genotype. *Radiology* 2001;218(2):434–42.
- [5] Mautner VF, Tatagiba M, Lindenau M, Fünsterer C, Pulst SM, Baser ME, et al. Spinal tumors in patients with neurofibromatosis type 2: MR imaging study of frequency, multiplicity, and variety. *AJR Am J Roentgenol* 1995;165(4):951–5.
- [6] Dow 1st G, Biggs N, Evans G, Gillespie J, Ramsden R, King A. Spinal tumors in neurofibromatosis type 2. Is emerging knowledge of genotype predictive of natural history? *J Neurosurg Spine* 2005;2(5):574–9.
- [7] Lee M, Rezai AR, Freed D, Epstein FJ. Intramedullary spinal cord tumors in neurofibromatosis. *Neurosurgery* 1996;38(1):32–7.
- [8] Egelhoff 1st JC, Bates DJ, Ross JS, Rothner AD, Cohen BH. Spinal MR findings in neurofibromatosis types 1 and 2. *AJNR Am J Neuroradiol* 1992;13(4):1071–7.
- [9] Rennie 1st AT, Side L, Kerr RS, Anslow P, Pretorius P. Intramedullary tumours in patients with neurofibromatosis type 2: MRI features associated with a favourable prognosis. *Clin Radiol* 2008;63(2):193–200.
- [10] Acoustic neuroma. NIH Consensus Statement 1991;9:1–24.
- [11] Louis DN, Ohgaki H, Wiestler OD, Cavenee WK. WHO histological typing of tumours of the central nervous system. Lyon: International Agency for Research on Cancer; 2007.
- [12] Aboukais R, Baroncini M, Zairi F, Bonne NX, Schapira S, Vincent C, et al. Prognostic value and management of spinal tumors in neurofibromatosis type 2 patients. *Acta Neurochir (Wien)* 2013;155(5):771–7.
- [13] Baser ME, Friedman JM, Aeschliman D, Joe H, Wallace AJ, Ramsden RT, et al. Predictors of the risk of mortality in neurofibromatosis 2. *Am J Hum Genet* 2002;71(4):715–23.
- [14] Plotkin 1st SR, O'Donnell CC, Curry WT, Bove CM, MacCollin M, Nunes FP. Spinal ependymomas in neurofibromatosis type 2: a retrospective analysis of 55 patients. *J Neurosurg Spine* 2011;14(4):543–7.
- [15] Miyazawa N, Hida K, Iwasaki Y, Koyanagi I, Abe H. MRI at 1.5 T of intramedullary ependymoma and classification of pattern of contrast enhancement. *Neuroradiology* 2000;42(11):828–32.
- [16] Sun B, Wang C, Wang J, Liu A. MRI features of intramedullary spinal cord ependymomas. *J Neuroimaging* 2003;13(4):346–51.
- [17] Brotchi J, Noterman J, Baleriaux D. Surgery of intramedullary spinal cord tumours. *Acta Neurochir (Wien)* 1992;116(2–4):176–8.