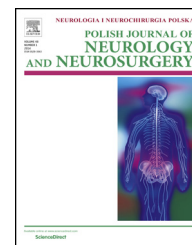

Available online at [www.sciencedirect.com](http://www.sciencedirect.com)

ScienceDirect

journal homepage: <http://www.elsevier.com/locate/pjnns>

## Original research article

# Thoracolumbar burst fractures requiring instrumented fusion: Should reduced bone fragments be removed? A retrospective study



Can Yaldiz<sup>a,\*</sup>, Kiyasettin Asil<sup>b</sup>, Birol Özkal<sup>c</sup>, Davut Ceylan<sup>a</sup>, Tibet Kacira<sup>a</sup>

<sup>a</sup> Sakarya University Training and Research Hospital, Department of Neurosurgery, Sakarya, Turkey

<sup>b</sup> Sakarya University Training and Research Hospital, Department of Radiology, Sakarya, Turkey

<sup>c</sup> Alanya Government Hospital, Clinic of Neurosurgery, Alanya, Turkey

## ARTICLE INFO

## Article history:

Received 19 February 2015

Accepted 26 August 2015

Available online 4 September 2015

## Keywords:

Bone fragment

Posterior spinal instrumentation

Thoracolumbar burst fracture

## ABSTRACT

**Background:** Thoracolumbar burst fractures are common clinical entity encountered in neurosurgical practice, accounting for 10–20% of all spinal fractures. Clinical picture could be devastating due to severe neurological deficits which lead the patients dependent both socially and emotionally.

**Materials and methods:** This study compared two groups of patients who were operated because of thoracolumbar burst fracture secondary to spinal trauma in terms of neurologic deficits, degree of improvement, and radiologic measurements at one-year follow-up. The first group (group I) included the patients who underwent posterior total laminectomy, peroperative reduction of intracanal bone fragments, and posterior spinal instrumentation and the second group (group II) included the patients who underwent total laminectomy, and spinal instrumentation without reduction of free bone fragments.

**Results:** Neither group showed significant correlation with any measurement parameter. Radiological assessments and clinical improvements did not disclosed significant difference between the two groups at one-year follow-up.

**Conclusion:** Retropulsion of free bone fragments extend the time of surgery and causes complications. This study found that there is no need to retropulse the bone fragments in the spinal canal in patients with unstable burst fractures who underwent total laminectomy and posterior long segment stabilization.

© 2015 Polish Neurological Society. Published by Elsevier Sp. z o.o. All rights reserved.

## 1. Introduction

The thoracolumbar region is one of the most important biomechanic transition zone in which rigid thoracic kyphosis

and flexible lumbar lordosis meet. So that in this zone forces act upon in different directions which makes this zone vulnerable to the spinal trauma [1–7]. Nearly 90% of all spinal fractures occur in thoracolumbar area, 10–20% of which is burst fractures. Neurological deficits, from simple

\* Corresponding author at: Department of Neurosurgery, Sakarya Training and Research Hospital, Sakarya, Turkey. Tel.: +90 2642750090 1460; fax: +90 3643460101; mobile: +90 5053572222.

E-mail address: [drcanyaldiz@yahoo.com](mailto:drcanyaldiz@yahoo.com) (C. Yaldiz).

<http://dx.doi.org/10.1016/j.pjnns.2015.08.005>

0028-3843/© 2015 Polish Neurological Society. Published by Elsevier Sp. z o.o. All rights reserved.

paresthesia to severe plegia can be developed in most patients [2,13–15].

Advanced imaging techniques have led us to make rapid diagnose and treatment of these fractures. In case of emergency, bone window definition of CT, especially axial CT, is very helpful for evaluation of the fractures and free fragments if present, in the spinal canal and MRI which is now gold standard to evaluate the spinal cord injury [1–4,15–27].

TLBFs are generally unstable fractures and [28] surgery is typically required to restore the spinal canal and vertebral alignment [3,28–30]. Surgery decompresses the spinal cord and corrects the vertebral column alignment by using laminectomy and applying transpedicular screws [30]. Surgical procedures have been further developed based on technological advancements. Dicks' internal fixators (providing posterior reduction, distraction, and stabilization), universal spinal systems, cancellous bone graft techniques defined by Daniaux, and transpedicular screw systems are examples of such surgical advancements [31].

Spontaneous resorption of bone fragments in the spinal canal with or without instrumentation has been reported in some cases [3,30] and also surgical and conservative treatment strategies for patients without neurologic deficits have been discussed extensively in the literature [3,31–33].

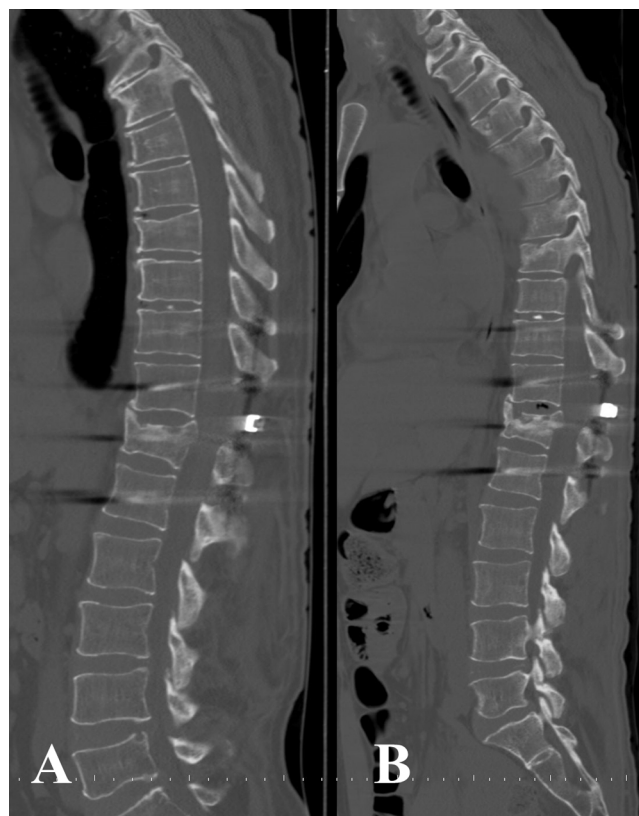
This study compared the two groups of patients in whom either reduction of free bone fragments was performed or not in addition to laminectomy and posterior instrumentation following TLBFs with respect to clinical and radiological outcomes at one-year follow-up after surgery.

## 2. Materials and methods

This retrospective analysis consisted of 40 patients who were admitted to the emergency department between 2011 and 2013 and diagnosed with unstable TLBFs secondary to trauma to the spine. All the patients were treated with decompression and posterior instrumentation.

Patients were divided into two groups; each of which included 20 patients. The first group (group I) had total laminectomy and posterior stabilization and the group II had the same surgical treatment with the reduction of free bone fragments.

Pre- and postoperative Benzel-Larson Grading (Table 1) [34] and American Spinal Injury Association (ASIA) Classification were examined by using axial and multiplanar reconstructed



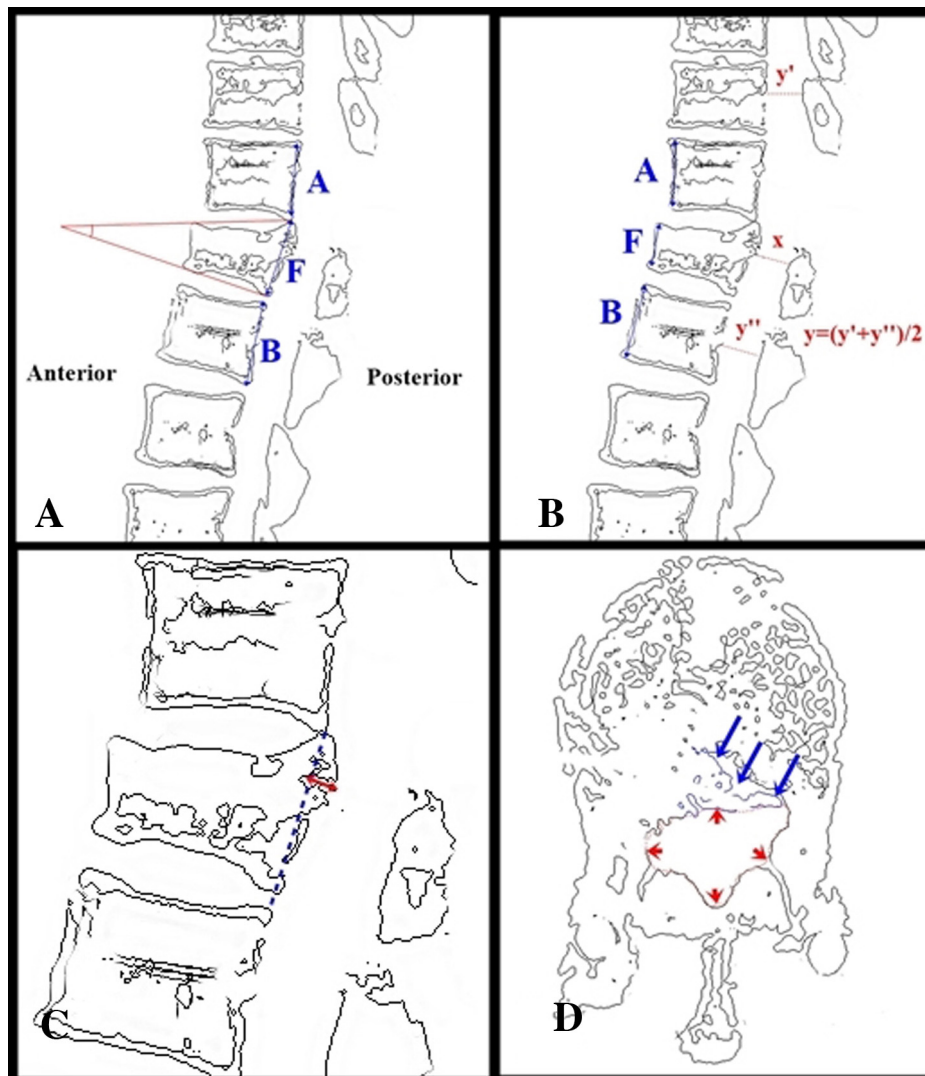
**Image 1 – Sagittal MPR image in CT analysis of one patient from each group. (a) Sagittal MPR image in CT analysis of a patient with reduction of free fragments. (b) Sagittal MPR image in CT analysis of a patient without reduction of free fragments.**

CT images (Image 1). The clinical improvement ratio was determined by subtracting the preoperative Benzel-Larson Grading and American Spinal Injury Association (ASIA) Classification values from the postoperative values.

In CT analyses, the formula  $2F/(A + B) \times 100$  was used to calculate the degree of the vertebra compression; where  $F$  is the height of the fractured vertebral body,  $A$  is the height of the upper vertebral body, and  $B$  is the height of the lower vertebral body (Image 2a and b). The formula,  $\alpha = (1 - x/y) \times 100$  was used

**Table 1 – Benzel-Larson neurological grading system of thoracic and lumbar spine injuries with regard to myelopathic function.**

Grade	Description
I	Complete functional neural transection: no motor or sensory function
II	Motor complete: no voluntary motor function with preservation of some sensation
III	Motor incomplete – nonfunctional: minimal nonfunctional voluntary motor function
IV	Motor incomplete – functional (nonambulatory): some functional motor control that is useful but not sufficient for independent walking
V	Motor incomplete – functional (limited ambulation): walking with assistance or unassisted but with significant difficulty that limits patient mobility
VI	Motor incomplete – functional (unlimited ambulation): difficulty with micturition; significant motor radiculopathy; discoordinated gait
VII	Normal: neurologically intact or minimal deficits that cause no functional difficulties



**Image 2 – Schematic of radiologic measurements.** (a) Kyphotic angle: the angle that connects the lines passing through superior and inferior endplates of vertebra (lost height due to trauma; red lines). Composition of posterior section of vertebra (blue lines):  $2F/(A + B) \times 100$  F to give the height of the fractured vertebral body. Here, A is the height of the upper vertebral body, and B is the height of the lower vertebral body. (b) Composition of anterior section of vertebra (blue lines):  $2F/(A + B) \times 100$  F. The height of the fractured vertebral body, where A is the height of the upper vertebral body, and B is the height of the lower vertebral body. Compromise ratio in the canal diameter (red lines):  $\alpha = (1 - x/y) \times 100$ . Here  $\alpha$  is the percentage of canal compromise, x is the narrowest mid-sagittal diameter of the spinal canal at the level of injury, and y is the average mid-sagittal diameter of the first upper level. The (y') and lower level (y'') are measured in multiplanar reconstruction images in CT. (c) The site with maximum posterior displacement in the vertebra fragment canal (blue dotted line) that connects the upper posterior corners of a lower vertebra corpus and a lower posterior of an upper vertebral body according to the vertebra with height loss (red line). (d) Canal area compromise ratio in axial CT analyses (red dotted line):  $\alpha = (1 - x/y) \times 100$ . Here  $\alpha$  is the percentage of canal compromise, x is the narrowest mid-sagittal diameter of the spinal canal at the level of injury, and y is the average mid-sagittal area of the first upper level (y') and lower level (y'') that can be measured in multiplanar reconstruction images in CT. Free fragments (blue arrows) can also be observed. (For interpretation of the references to color in this figure legend, the reader is referred to the web version of this article.)

separately to calculate canal compromise in sagittal Multiplanar reformatting (MPR) images and diameter in axial CT sections. Here,  $\alpha$  is the percentage of canal compromise, and x is the narrowest mid-sagittal diameter or area of the spinal canal at the level of injury. Term y is the average mid-sagittal diameter of the first upper level and the first lower level that can be

measured in multiplanar CT (Image 2a and d). The fractured vertebral body angle of kyphotic deformity was measured as the angle between the margin of the upper level vertebral body and the margin of the lower vertebral body (Image 2a). Furthermore, the site of the highest posterior displacement was measured in the canal of the vertebra fragment by using the line connecting

the lower posterior corners of an upper vertebral body and the upper posterior corners of a lower vertebral body (Image 2c). The spinal canal was measured, where the fracture had been occurred, between upper stable vertebral body and lower stable vertebral body that did not coincide the neural foramen. Patient age, sex, level of injury, type of injury, surgical instrumentation, and spinal canal intervention were all recorded during enrollment.

### 2.1. Inclusion and exclusion criteria

Cases were retrospectively evaluated. The following cases were excluded: patients under the age 18, patients with a canal diameter of  $\leq 30\%$ , patients who were evaluated as stable fractures and conservatively followed-up, patients who underwent more than 3 level posterior spinal instrumentation and were not implanted with transpedicular screws at the fracture level, patients who underwent posterior segmental instrumentation, anterior corpectomy, and cage applications, patients who did not undergo decompressive laminectomy at the fracture level; patients who had fractures at three or more levels; and patients who were operated on after 24 h following the trauma. The clinical status of the patients were not been considered while the groups had been created. The indications for surgical treatment were based on the Denis criteria [35].

### 2.2. Medical treatment

Both groups were given a 30 mg/kg bolus of methylprednisolone within 15 min. A 5.4 mg/kg dose was continued in the next 23 h [26]. Medical therapy was performed in both groups except for those included in Benzell-Larson grade 7 [5].

### 2.3. Surgical technique

The surgical technique has been well-defined and we here mention shortly. All patients were taken to the operating room for immediate surgery after the diagnostic work-up was completed in the emergency department. Paravertebral muscles were dissected bilaterally and at the fracture level total laminectomy together with minimal facetectomy were performed to all patients. However; partial laminectomies were performed at the upper and lower stable (no fractures observed) levels and the nerve roots were decompressed bilaterally. In the group II, free bone fragments in the spinal canal were removed or reduced. Transpedicular screws were attached to one upper and two lower levels of the fracture site. The system was fixed with rods in vertical direction and the bone fragments from the spinal canal which was followed by the application of autologous and allogenic bone for the supporting of the system.

### 2.4. Demographic data

A total of 40 patients; 24 males and 16 females met our inclusion criteria. Tables 2 and 3 present the demographic data.

### 2.5. Radiological studies

We included patients who underwent multidetector computed tomography (MDCT) analysis at 0.5 mm cross-section

**Table 2 – Distribution of patient groups according to age.**

Age	Female	Male	Total
Group 1	33.8 (n = 7)	40.2 (n = 13)	37.96 (n = 20)
Group 2	39.8 (n = 9)	38.3 (n = 11)	38.98 (n = 20)

**Table 3 – Distribution of groups according to levels (multiple fractures in 7 patients).**

Levels	L2	L1	T12	T11
Group 1 (n = 20)	1	10	11	3
Group 2 (n = 20)	3	13	6	–

**Table 4 – Average radiologic value of CT measurements at the end of one year.**

	Mean (%)	N
Height loss ratio in vertebra posterior (Group II)	12.7392	20
Height loss ratio in vertebra posterior (Group I)	15.7469	20
Height loss ratio in vertebra anterior (Group II)	35.9085	20
Height loss ratio in vertebra anterior (Group I)	46.2377	20
Ratio of spinal canal compromise at the narrowest site (Group II)	50.6923	20
Ratio of spinal canal compromise at the narrowest site (Group I)	48.6154	20
Kyphotic angle (Group II)	16.7023	20
Kyphotic angle (Group I)	18.8323	20

intervals in supine position at the end of the first postoperative year. Vertebra compression ratios, spinal canal compromise ratios, kyphotic angle, and degree of the posterior displacement were measured on axial cross-sections and sagittal multiplanar reconstruction images (Image 2) in both groups and parameters were compared at one-year follow-up after surgery (Table 4).

### 2.6. Statistical analysis

NCSS (Number Cruncher Statistical System) 2007&PASS (Power Analysis and Sample Size) 2008 Statistical Software (Utah, USA) programme were used for statistical analysis. We used a t-test for paired data, and the “p” value less than 0.05 was considered to be statistically significant.

## 3. Results

The mean age of patients in both groups was similar; 37.96 and 38.98 years in the group I and II, respectively and the majority were male (Table 2). Most fractures occurred at the level of T<sub>12</sub> and L<sub>1</sub> and in 4 in the group I and in 3 in the group II had fractures at more than one level (Table 3).

Analysis comparison between the both group showed no significant correlation in terms of all parameters (Table 5). At the end of the first year, axial CT images and sagittal MPR images of the patients showed no significant difference between control CT measurements and improvement levels of both groups who underwent surgical treatment (Table 6, Graph 1).



**Table 5 – Statistical correlation between the measurements of both groups at the end of one year.**

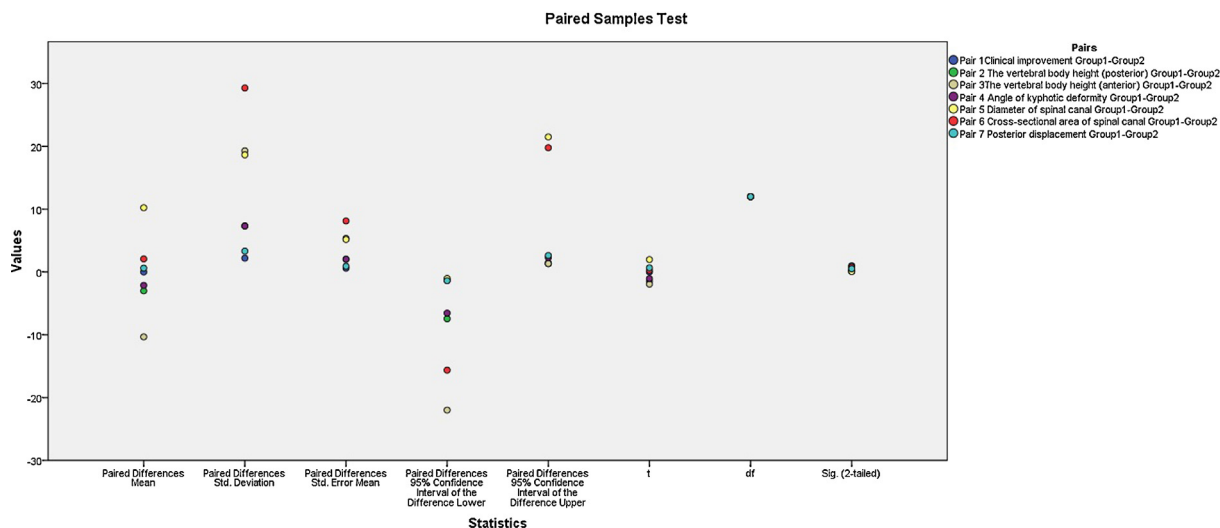
Group I–II	N	Sig.
Clinical improvement	20	.224
Height loss ratio in vertebra posterior	20	.282
Height loss ratio in vertebra anterior	20	.127
Kyphotic angle	20	.565
Ratio of compromise in diameter of spinal canal at the narrowest site	20	.196
Ratio of compromise in area of spinal canal at the narrowest site	20	.561
Maximum spinal displacement to canal in bone fragment	20	.861

Using the Benzel-Larson scores for group 1, we found no change in 5 patients, 7 patients in stage 1 recovery, and 8 patients in stage 2 or above. In group 2, no change was seen in 6 patients, 7 patients in stage 1, and 7 patients in stage 2 or above. There was no statistical difference in clinical recovery between the groups I and II ( $p > 0.05$ ).

Using the ASIA scores for group 1, we found no change in 8 patients, 9 patients in stage 1 recovery, and 3 patients in stage 2 or above. In group 2, no change was seen in 8 patients, 10 patients in stage 1, and 2 patients in stage 2 or above. There was no statistical difference in clinical recovery between the groups I and II ( $p > 0.05$ ).

Using the ASIA scores for group 1, we found no change in 5 patients which were classified as ASIA A and 9 patients classified as ASIA B. 4 of them showed improvement in motor strength and sensorial examination that increased one stage in status. 2 patients showed full setup and the status increased from ASIA D2 to E. 12 of the 20 patients showed no improvement in gaita incontinence and 1 patient was followed-up with trans urethral catheter (Table 7).

Using the ASIA scores for group 2, we found no change in 6 patients which were classified as ASIA A and 8 patients classified as ASIA B. 5 of them showed improvement in motor strength and sensorial examination that increased one stage in status. 2 patients showed full setup and the status increased from ASIA D2 to E. 12 of the 20 patients showed no

**Graph 1 – Statistical difference between the measurements of both groups at the end of one year.****Table 6 – Statistical difference between the measurements of both groups at the end of one year.**

Paired samples test		Paired differences					t	df	Sig. (2-tailed)
		Mean	Std. deviation	Std. error mean	95% Confidence interval of the difference				
					Lower	Upper			
Pair 1	Clinical improvement (Group I–II)	.00000	2.19848	.60975	–1.32853	1.32853	.000	20	1.000
Pair 2	Posterior wall height loss (Group I–II)	–3.00769	7.34338	2.03669	–7.44525	1.42987	–1.477	20	.165
Pair 3	Anterior wall height loss (Group I–II)	–10.32923	19.29134	5.35045	–21.98687	1.32841	–1.931	20	.078
Pair 4	Kyphotic angle (Group I–II)	–2.13000	7.30809	2.02690	–6.54623	2.28623	–1.051	20	.314
Pair 5	Spinal canal diameter (Group I–II)	10.23077	1865098	5.17285	–1.03990	21.50144	1.978	20	.071
Pair 6	Spinal canal area (Group I–II)	2.07692	29.29579	8.12519	–15.62635	19.78019	.256	20	.800
Pair 7	Maximum displacement in canal (Group I–II)	.61615	3.32123	.92114	–1.39084	2.62315	.669	20	.516

**Table 7 – Preoperative and postoperative BL and ASIA scores difference for the first 1 year in group 1.**

Group 1	Benzel-Larson preoperative grade	Benzel-Larson postoperative grade (1 year)	ASIA preoperative grade	ASIA postoperative grade (1 year)
1	1	1	A	A
2	1	1	A	A
3	1	1	A	A
4	2	3	B	B
5	2	3	B	B
6	3	4	B	C
7	3	4	B	C
8	3	4	B	C
9	1	1	A	A
10	1	1	A	A
11	3	5	B	D
12	3	4	B	C
13	3	5	B	D
14	3	5	C	D
15	4	6	C	D
16	4	6	C	D
17	5	7	D	E
18	5	6	D	D
19	3	6	B	D
20	5	7	D	E

**Table 8 – Preoperative and postoperative BL and ASIA scores difference for the first 1 year in group 2.**

Group 2	Benzel-Larson preoperative grade	Benzel-Larson postoperative grade (1 year)	ASIA preoperative grade	ASIA postoperative grade (1 year)
1	1	1	A	A
2	1	1	A	A
3	1	1	A	A
4	1	1	A	A
5	2	2	A	A
6	1	1	A	A
7	2	4	B	C
8	2	3	B	B
9	3	4	B	C
10	3	4	B	C
11	3	4	B	C
12	3	4	B	C
13	3	6	B	D
14	3	5	B	D
15	4	6	C	D
16	4	6	C	D
17	4	6	C	D
18	5	6	D	D
19	5	7	D	E
20	5	7	D	E

improvement in gaita incontinence and two patients were followed-up with trans urethral catheter (Table 8).

We observed superficial wound infection in 2 cases. One had deep vein thrombosis, and one had sacral decubitus that was treated by wound dressing.

#### 4. Discussion

The primary goal of surgery in TLBFs is to eliminate the compression of the neural structures, to restore anatomic alignment and to correct if possible, deformity in spinal

vertebra [5]. Due to the technical advancements including the development of less invasive methods, optimal surgical approaches to these clinical conditions have been discussing during the last decade [6].

Neurologic deficits occur in 50–60% in TLBFs and can progress from simple paresthesia to hemiplegia [2,3]. A traumatized spine accompanied by a neurologic deficit is generally a complicated condition due to pathomechanical and biological factors. Since the mechanism(s) of spinal cord injury has not been understood clearly, it is very difficult to choose the best surgical approach which cannot guarantee the recovery of the neurologic deficits. While some centers

claimed that anterior decompression is superior to other surgical approaches in terms of clinical improvements, but some others did not find any significant differences among the surgical approaches [6–11,36]. However, the common notion is that surgical decompression still continues to be the best treatment option today [6].

Yan et al. [12], reported that free bone fragments in the spinal canal is the main reason for the neurologic damage and removing the free bone fragments decompresses the neuronal tissue which make recovery faster. In their retrospective study, Deng et al. reported that posterior short segment stabilization, posterior laminectomy, and reduction of bone fragments in TLBFs were adequate to eliminate the tension on the neural tissues [2]. In a meta-analysis of 275 patients, Boerger et al. suggested that total laminectomy is not adequate to improve neurologic deficits and this claim is supported by a meta-analysis of 733 patients which found that the best results is possible the addition of the posterior stabilization to laminectomy [6,13]. Experimental and clinical studies underline that acute decompression is beneficial for partial neurologic deficits [14–17], and furthermore class I and class II clinical studies disclosed decompressive treatment has a significant role in neurologic improvement [36].

Timing of surgery is still continues to be an enigma. Cengiz et al. reported that neurologic improvement was not affected in patients who underwent surgery within a period of 72 h or longer [18], while Li et al. reported that decompression performed in the first 24 h was adequate and if performed in the first 8 h, secondary neuronal injury can be reversed [7].

It is likely that timing of the surgery depends on the neurological situation, the severity of the trauma, accompanying systemic traumas and the number of the fractured vertebrae. Nevertheless, the early surgery seems to be optimal as soon as the clinical condition of the patient is stabilized [37–40]. Roy-Camille et al. [39] reported that the surgical treatment must be done as quickly as possible. If the cord injury is incomplete and neurological conditions are not worsening, then the surgery can be done in 24–48 h to avoid bleeding. If a complete cord injury has occurred, then urgent surgical decompression must be done. Urgent decompression has been reported to increase neurological recovery. In our study, we observed neurologic improvement in all patients who underwent urgent spinal decompression in the first 24 h ( $p > 0.005$ ). Thus, cases performed more than 24 h after injury were excluded from our study.

The choice of the surgical procedures in thoracolumbar vertebrae fractures remains unclear [16,22,38,39]. The type of the fracture, stability, the stenosis of the spinal canal and the neurological situation of the patient are important factors for choosing the best surgical procedure [5–11,38–41]. Unstable corpus fractures must be treated with both anterior and posterior approaches. Most reports state that there is no difference in recovery between the anterior and posterior procedures in incomplete spinal cord injury but sufficient spinal cord decompression can be done with anterior procedures. However, risk of major vein and visceral organ injuries is high and technical difficulties regarding to the anterior surgical interventions are drawbacks. On the other hand, the posterior procedures rarely provide sufficient cord decompression with fewer complications. So that the majority

of spinal surgeons are performing posterior approach because of easy to perform in addition to the above advantages.

Some authors suggest that combined anterior and posterior approaches should be performed together in order to have sufficient decompression and for the stability of the spine [4,5,19,21,22,42]. Combined approach in severe TLBFs with  $\geq 20\%$  canal compromise and  $\geq 50\%$  height loss is one of the most widely recognized surgical approach. This approach most effectively decompresses the spinal canal, leads to surgeon to recover the stability [5,19]. Different notions have also been reported in the literature with respect to the type of surgical approaches. Oprel et al. reported that a single posterior approach is more effective compared to a combined approach in selected patients [4]. Danisa et al. compared posterior and combined approaches and found no significant difference [20]. Recent studies report that anterior, posterior, or combined approaches are not superior to one another [5,19,21,22]. Our patients had an average posterior vertebra height loss of 8.5–15.7% and canal compromise of 50.6–48.6% that required decompression by total laminectomy. Similar to Kim et al., we believe that posterior approaches are easier, more reliable than anterior approaches, and are adequate for canal decompression and restoration [5].

Kyphotic angulation is another point that a clinician should be aware of and it can progress at the long-term follow-up [42]. It has been reported that angulation is less common in patients who had long segment stabilization with an anterior approach [1]. Dvorak et al. shown that the average degree of preoperative kyphosis,  $25.4 \pm 18.4^\circ$ , improved to  $7.5 \pm 15.3^\circ$  after anterior approach [24]. In the follow-up, the degree of kyphosis further improved to  $10.4 \pm 13.2^\circ$ . Kaneda et al. used a titanium mesh to correct kyphosis and reported that the plate range was  $6^\circ$  and  $10^\circ$  at the last follow-up [24]. Reinhold et al. compared posterior, anterior, and combined systems and observed that the combined system was superior to others when it is followed up with the Cobb angle [6]. In our study, there was no statistical difference between the groups in terms of kyphotic angulation ( $p > 0.005$ ).

Wesner et al. performed a follow-up analysis of TLBF patients treated with an internal fixation and spondylosaplasty technique for a period of 12–30 months [25]. Their analysis examined canal diameter, kyphotic angulation, and vertebral column height. In that study, the spinal canal reconstructed itself up to 91%. Similar to the above study (25), we found no statistically significant difference between the groups who did or did not have intracanal intervention at the end of one year ( $p > 0.005$ ). Although we found no significant differences in terms of both radiologic and clinical improvement at one-year follow-up, we prefer not to retropulse free bone fragments because any unnecessary intervention can increase the amount of injury.

## 5. Conclusion

This retrospective analysis showed no significant difference between the two surgical approaches at one-year follow-up. The reduction of free bone fragments extends the time of surgery and can cause additional complications. Based on the results of this study, we believe that there is no need to reduct

the free bone fragments inpatients with unstable TLBFs and further studies are necessary to better evaluate our results.

### Conflict of interest

None declared.

### Acknowledgement and financial support

None declared.

### Ethics

The work described in this article has been carried out in accordance with The Code of Ethics of the World Medical Association (Declaration of Helsinki) for experiments involving humans; Uniform Requirements for manuscripts submitted to Biomedical journals.

### REFERENCES

- [1] Lee GJ, Lee JK, Hur H, Jang JW, Kim TS, Kim SH. Comparison of clinical and radiologic results between expandable cages and titanium mesh cages for thoracolumbar burst fracture. *J Korean Neurosurg Soc* 2014;55(3):142–7.
- [2] Deng Z, Zou H, Cai L, Ping A, Wang Y, Ai Q. The retrospective analysis of posterior short segment pedicle instrumentation without fusion for thorocolumbar burst fracture with neurological deficit. *Sci World J* 2014; 457634.
- [3] Wessberg P, Wang Y, Irstam L, Nordwall A. The effect of surgery and remodelling on spinal canal measurements after thoracolumbar burst fractures. *Eur Spine J* 2001;10 (Suppl. 1):55–63.
- [4] Oprel PP, Tuinerbreijer WE, Patka P. Combined anterior-posterior surgery versus posterior surgery for thorocolumbar burst fractures: a systematic review of literature. *Open Orthop J* 2010;4:93–100.
- [5] Kim MS, Eun JP, Park JS. Radiological and clinical results of laminectomy and posterior stabilization for severe thoracolumbar burst fracture: surgical technique for one stage operation. *J Korean Neurosurg Soc* 2011;50(Suppl. 3):224–30.
- [6] Reinhold M, Knop C, Beisse R, Audigé L, Kandziora F, Pizanis A, et al. Operative treatment of 733 patients with acute thoracolumbar spinal injuries: comprehensive results from the second, prospective, internet-based multicenter study of the Spine Study Group of the German Association of Trauma Surgery. *Eur Spine J* 2010;19:1657–76.
- [7] Li Y, Walker CL, Zhang YP, Shields CB, Xu XM. Surgical decompression in acute spinal cord injury: a review of clinical evidence, animal model studies, and potential future directions of investigation. *Front Biol (Beijing)* 2014;9 (Suppl. 2):127–36.
- [8] Bradford DS, McBride GG. Surgical management of thoracolumbar spine fractures with incomplete neurologic deficits. *Clin Orthop* 1987;218:201–16.
- [9] Ghanayem AJ, Zdeblick TA. Anterior instrumentation in the management of thoracolumbar burst fractures. *Clin Orthop* 1997;335:89–100.
- [10] Kostuik JP. Anterior fixation for burst fractures of the thoracic and lumbar spine with or without neurological involvement. *Spine* 1988;13(Suppl. 3):286–93.
- [11] McAfee PC, Bohlman HH, Yuan HA. Anterior decompression of traumatic thoracolumbar fractures with incomplete neurological deficit using a retroperitoneal approach. *J Bone Joint Surg Am* 1985;67(Suppl. 1):89–104.
- [12] Yan YB, Qi W, Wu ZX, Qiu TX, Teo EC, Lei W. Finite element study of the mechanical response in spinal cord during the thorocolumbar burst fracture. *PLoS ONE* 2012;7(Suppl. 9): e41397.
- [13] Boerger TO, Limb D, Dickson RA. Does 'canal clearance' affect neurological outcome after thoracolumbar burst fractures? *J Bone Joint Surg Br* 2000;82(Suppl. 5):629–35.
- [14] Carlson GD, Gorden CD, Oliff HS, et al. Sustained spinal cord compression: part I: time-dependent effect on long-term pathophysiology. *J Bone Joint Surg Am* 2003;85A(1):86–94.
- [15] Dimar JR, Glassman SD, Raque GH, Zhang YP, Shields CB. The influence of spinal canal narrowing and timing of decompression on neurologic recovery after spinal cord contusion in a rat model. *Spine* 1999;24(Suppl. 16):1623–33.
- [16] Fehlings MG, Perrin RG. The role and timing of early decompression for cervical spinal cord injury: update with a review of recent clinical evidence. *Injury* 2005;36(Suppl. 2): B13–26.
- [17] Kaneda K, Abumi K, Fujiya M. Burst fractures with neurologic deficits of the thoracolumbar–lumbar spine. Results of anterior decompression and stabilization with anterior instrumentation. *Spine* 1984;9(Suppl. 8):788–95.
- [18] Cengiz SL, Kalkan E, Bayir A, Ilik K, Basefer A. Timing of thoracolumbar spine stabilization in trauma patients; impact on neurological outcome and clinical course. A real prospective (rct) randomized controlled study. *Arch Orthop Trauma Surg* 2008;128(Suppl. 9):959–66.
- [19] Sayer FT, Kronvall E, Nilsson OG. Methylprednisolone treatment in acute spinal cord injury: the myth challenged through a structured analysis of published literature. *Spine J* 2006;6:335–43.
- [20] Danisa OA, Shaffrey CI, Jane JA, Whitehill R, et al. Surgical approaches for the correction of unstable thoracolumbar burst fractures: a retrospective analysis of treatment outcomes. *J Neurosurg* 1995;83(Suppl. 6):977–83.
- [21] Lu DC, Lau D, Lee JG, Chou D. The transpedicular approach compared with the anterior approach: an analysis of 80 thoracolumbar corpectomies. *J Neurosurg Spine* 2010;12:583–91.
- [22] The National SCI Statistical Center. Spinal Cord Injury, Facts and Figures at a Glance. Birmingham: University of Alabama; 2008.
- [23] Dvorak MF, Kwon BK, Fisher CG, Eiserloh 3rd HL, Boyd M, Wing PC. Effectiveness of titanium mesh cylindrical cages in anterior column reconstruction after thoracic and lumbar vertebral body resection. *Spine (Phila Pa 1976)* 2003;28:902–8.
- [24] Kaneda K, Taneichi H, Abumi K, Hashimoto T, Satoh S, Fujiya M. Anterior decompression and stabilization with the Kaneda device for thoracolumbar burst fractures associated with neurological deficits. *J Bone Joint Surg Am* 1997;79:69–83.
- [25] Wesner F, Hutzelmann A, Freund M, Besch L, Riemann U, Egbers HJ, et al. CT morphology of fractured thoracolumbar vertebrae after transpedicular spongiosaplasty and use of internal fixator. *ROFO* 1997;167(Suppl. 3):234–9.
- [26] Nesathurai S. Steroids and spinal cord injury: revisiting the NASCIS 2 and NASCIS 3 trials. *J Trauma Inj Infect Crit Care* 1998;45(Suppl. 6):1088–93.
- [27] Wilcox RK, Boerger TO, Hall RM, Barton DC, Limb D, Dickson RA. Measurement of canal occlusion during the thoracolumbar burst fracture process. *J Biomech* 2002;35:381–4.



- [28] Kim GW, Jang JW, Hur H, Lee JK, Kim JH, Kim SH. Predictive factors for a kyphosis recurrence following short-segment pedicle screw fixation including fractured vertebral body in unstable thoracolumbar burst fractures. *J Korean Neurosurg Soc* 2014;56(3):230–6.
- [29] Denis F. The three column spine and its significance in the classification of acute thoracolumbar spinal injuries. *Spine* 1983;8:817–31.
- [30] Leferink VJ, Nijboer JM, Zimmerman KW, Veldhuis EF, ten Vergert EM, ten Duis HJ. Burst fractures of the thoracolumbar spine: changes of the spinal canal during operative treatment and follow-up. *Eur Spine J* 2003;12 (Suppl. 3):255–60.
- [31] Daniaux H. Technik und erste Ergebnisse der transpedikulären Spongiosa plastic bei Kompressions brüchenim Lenden wirbelsäulenbereich. *Acta Chir Austriaca* 1982;43:79.
- [32] Aebi M, Etter C, Kehl T, Thalgot J. Stabilization of the lower thoracic and lumbar spine with the internal spinal skeletal fixation system. Indications, techniques, and first results of treatment. *Spine* 1987;12:544–51.
- [33] Dick W. Osteosynthese schwerer Verletzungen der Brust und Lendenwirbelsäule mit dem Fixateur interne. *Langenbecks Arch Chir* 1984;364:343–6.
- [34] Kaya RA, Aydin Y. Modified transpedicular approach for the surgical treatment of severe thoracolumbar or lumbar burst fractures. *Spine J* 2004;4(2):208–17.
- [35] Ghobrial GM, Jallo J. Thoracolumbar spine trauma: review of the evidence. *J Neurosurg Sci* 2013;57(2):115–22.
- [36] Zhang S, Thakur JD, Khan IS, Menger R, Kukreja S, Ahmed O, et al. Anterior stabilization for unstable traumatic thoracolumbar spine burst fractures. *Clin Neurol Neurosurg* 2015;130:86–90.
- [37] Kang MS, Shin YH, Lee CD, Lee SH. Delayed neurological deficits induced by an epidural hematoma associated with a thoracic osteoporotic compression fracture. *Neurol Med Chir (Tokyo)* 2012;52(9):633–6.
- [38] McCormack T, Karaikovic E, Gaines RW. The load sharing classification of spine fractures. *Spine* 1994;19(15):1741–4.
- [39] Roy-Camille R, Saillant G, Mazel C. Plating of thoracic, thoracolumbar and lumbar injuries with pedicle screw plates. *Orthop Clin North Am* 1986;17:147–59.
- [40] Öner FC, Van Gils AP, Faber JA, Dhert WJ, Verbout AJ. Same complication of common treatment schemes of thoracolumbar spine fractures can be predicted with magnetic resonance imaging: prospective study of 53 patient with 71 fractures. *Spine* 2002;27:629–36.
- [41] Sasso RC, Cotler HB. Posterior instrumentation and fusion for unstable fractures and fracture dislocations of the thoracic and lumbar spine. *Spine* 1993;18:45–60.
- [42] Grossbach AJ, Dahdaleh NS, Abel TJ, Woods GD, Dlouhy BJ, Hitchon PW. Flexion-distraction injuries of the thoracolumbar spine: open fusion versus percutaneous pedicle screw fixation. *Neurosurg Focus* 2013;35(2):E2.