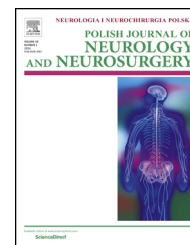


Available online at www.sciencedirect.com

ScienceDirect

journal homepage: <http://www.elsevier.com/locate/pjnns>

Case report

The use of mechanical thrombectomy in the treatment of basilar artery occlusion – case report



Daniel Knap^a, Maciej Honkowicz^{b,*}, Tomasz Kirmes^b, Marcin Koroński^b,
Marzena Kysiak^b, Mateusz Bukański^b, Dominik Sieroń^c, Izabela Dymon^d,
Jan Baron^a

^a Department of Radiology and Nuclear Medicine, Medical University of Silesia, Katowice, Poland

^b Medical Scientific Society Under the Department of Radiology and Nuclear Medicine, Medical University of Silesia, Katowice, Poland

^c District Hospital of Orthopedics and Trauma Surgery, Piekary Slaskie, Poland

^d Department of Neurology, Medical University of Silesia, Katowice, Poland

ARTICLE INFO

Article history:

Received 23 September 2014

Accepted 16 July 2015

Available online 29 July 2015

Keywords:

Stroke

Interventional radiology

Thrombectomy

Embolectomy

ABSTRACT

Occlusion of the basilar artery (BAO) is a rare cause of stroke, making up approximately 1% of all cases. Ischemic stroke within the basilar artery is associated with serious complications and high mortality (75–91%). BAO may occur initially in the form of mild prodromal symptoms with neurological disorders, the consequences of which can lead to death. For these reasons, BAO requires rapid diagnosis and treatment. We report the case of a 26-year-old man who suffered basilar artery occlusion and was treated with endovascular therapy. The patient was disqualified from intra-venous thrombolysis and endovascular treatment due to exceeding the therapeutic time window. Despite this, due to the location of ischemia and age of the patient, it was decided to proceed with a mechanical thrombectomy (TM). Vessel patency was restored using the Solitaire FR stent. Treatment continued with antiplatelet therapy. Despite a significant overshoot of the time window the procedure was successful and complete recanalization was achieved. During hospitalization, significant neurological symptom reductions were observed. There is no accurate data on which method of treatment of ischemic stroke is best for BAO. Expectations about the effectiveness of endovascular techniques are high.

© 2015 Polish Neurological Society. Published by Elsevier Sp. z o.o. All rights reserved.

Introduction

The basilar artery arises from the combination of the two vertebral arteries at the junction between the medulla oblongata and the pons. BA gives numerous branches to

vascularize the brain, they are: anterior inferior cerebellar artery, artery branches to the pons, vestibular artery, superior cerebellar artery and posterior cerebral artery. Occlusion of the basilar artery is a rare cause of stroke, being approximately 1% of all cases [1]. Ischemic stroke in the territory of the basilar artery is associated with serious complications and high

* Corresponding author at: Ropica Polska 560, 38-300 Gorlice, Poland. Tel.: +48 601 085 873.

E-mail address: m.honkowicz@gmail.com (M. Honkowicz).

<http://dx.doi.org/10.1016/j.pjnns.2015.07.004>

0028-3843/© 2015 Polish Neurological Society. Published by Elsevier Sp. z o.o. All rights reserved.

mortality (75–91%) [2]. Among the risk factors of basilar artery occlusion are: age, sex, hypertension, diabetes, smoking, hyperlipidemia, coronary artery disease, previous ischemic stroke and oral contraception [3]. BAO may present as mild prodromal symptoms, such as dizziness, headache, nausea and vomiting [3]. Other symptoms that may follow are: nystagmus, alternating syndrome, cerebellar syndrome, bulbar syndrome, circulatory and respiratory disorders, which can consequently lead to death. For these reasons, BAO requires rapid diagnosis and treatment. Recanalization of the obstructed vessel is the aim of therapy but there is no accurate data on which method of treatment of ischemic stroke is best in cases of BAO.

Case report

Symptoms

A 26-year-old patient was admitted to Hospital on 9 March 2012 at 2:45 PM. The patient was urgently transferred from another hospital (after undergoing a head MRI-DWI and being diagnosed with a brain stem ischemic stroke), in order to undergo a mechanical thrombectomy. Medical history revealed a plane journey the day before, followed by malaise and neck pain beginning in the evening. The patient woke up around 2 AM with weekend limbs (right side) and while trying to get up fell down. The patient probably suffers from epilepsy – he has been taking Amizepine since he was 3 years old, past medical history also includes hyperlipidemia IIa and hypertension. The patient has a family history, his father also suffered a ischemic stroke. Neurological examination at the time of admission stated: the patient is conscious, somnolent, understands and follows simple commands, meningeal signs absent, anartria with features of lockjaw, a tendency to turn the head and the eyes to the left, peripheral paresis of the right VII nerve, central paresis of the IX, X, XII nerve on the right side, plegia of the right leg with increased spastic muscle tone, right-sided hypoaesthesia, bilateral Babinski, NIHSS of 14 points, GCS 14 points. During the follow-up in A&E, a progression of neurological symptoms was observed – paresis of the left limbs of level 3 on Lovette's scale, NIHSS 18 points. Saturation: 96%; BP: 175/100 mmHg, body temperature: 36.9 °C.

Investigations

In order to confirm the diagnosis, the patient underwent a head CT (in transverse planes after intravenous administration of 95 mL Iomeron 350) at 3 PM (15 min after admission). The scan revealed a deficit of contrast in a segment of the basilar artery, of approximately 2 cm of length. The patient was disqualified from intravenous thrombolysis treatment due to exceeding the therapeutic time window (the duration of symptoms exceeded 4.5 h) and because of the inability to clearly determine the time of the onset of symptoms. Initially, mechanical thrombectomy was also abandoned, also due to exceeding the time window (time over 15 h). At 4:40 PM cerebrovascular digital subtraction angiography (DSA) was performed which showed basilar artery occlusion throughout its entire length including the branches (Figs. 1–3).

The treatment

Despite contraindications, the patient underwent a mechanical thrombectomy procedure, which started at 5:20 PM. The procedure was carried out with a catheter entering the right femoral artery using the Seldinger method. A microcatheter was introduced coaxially, through which a thrombectomy Solitaire FR device was placed in the artery. The stent was inflated above the thrombus, without complete release. Then, together with the thrombus, it was pulled through the guiding catheter. During the procedure constant washing with a heparin solution in normal saline was performed, while guiding both the catheter and microcatheter. We managed to get patency in the closed segment of the basilar artery. During the procedure an Abciximab infusion was administered, which continued in the neurology ward. The procedure was performed under general anesthesia.

Control after treatment

A control DSA performed after treatment revealed the left vertebral artery and the basilar artery with its branches. The posterior brain artery was non-contrasting in the DSA but was visible in an angiography of the right common carotid artery. The primary efficacy endpoint of cerebrovascular recanalization was assessed using the TICI scale (Thrombolysis in Cerebral Infarction: 0 – no flow; 1 – the contrast agent fills segment beyond embolic trace reperfusion; 2a – partial reperfusion, 2/3 of the total area of proper vascularization; 2b – a total reperfusion but slower filling; 3 – complete reperfusion), a score of 3 was achieved. The next day a control angio-CT of the head was performed, which showed an unobstructed basilar artery throughout its course. Segmental occlusions of the BA were visible in the middle part (6.6 mm of length) and also just before the upper cerebellar branch (3 mm of length). A head CT without contrast describes the findings as hypodense, ischemic, 28 mm in diameter in the left cerebellar hemisphere and 11 mm in diameter in the left side of the brain stem. A head MRI was performed – SE/T1, T2, FLAIR, DWI sequences in transverse planes; T2 and FLAIR CUBE sequences in sagittal planes (layer thickness: 5 and 3 mm). Within the central and left part of the pons, ischemic changes (subacute/chronic) were revealed and similar changes, but of a settled character, were revealed within the lower medial part of the cerebellar hemisphere (Figs. 4 and 5).

The patient's condition after treatment

On the first day after treatment a neurological examination showed dysarthria, peripheral paresis of the right VII cranial nerve, central paresis of the IX, X, XII cranial nerves on the right side, tetraplegia with paresis of the right limbs (0/1 on Lovette's scale in the upper limb, 2 on Lovette's scale in the lower limb), paresis of the left limbs (3 on Lovette's scale), right-sided hypoaesthesia, bilateral positive Babinski. The patient's condition assessed in NIHSS was rated at 16 points. On 28th March 2012 the patient was discharged from the ward and moved to the Department of Neurological Rehabilitation SP CSK, still presenting mild dysarthria, minor peripheral paresis of the right VII cranial nerve and a retreating pyramidal syndrome of the right hand, paresis of the right upper limb

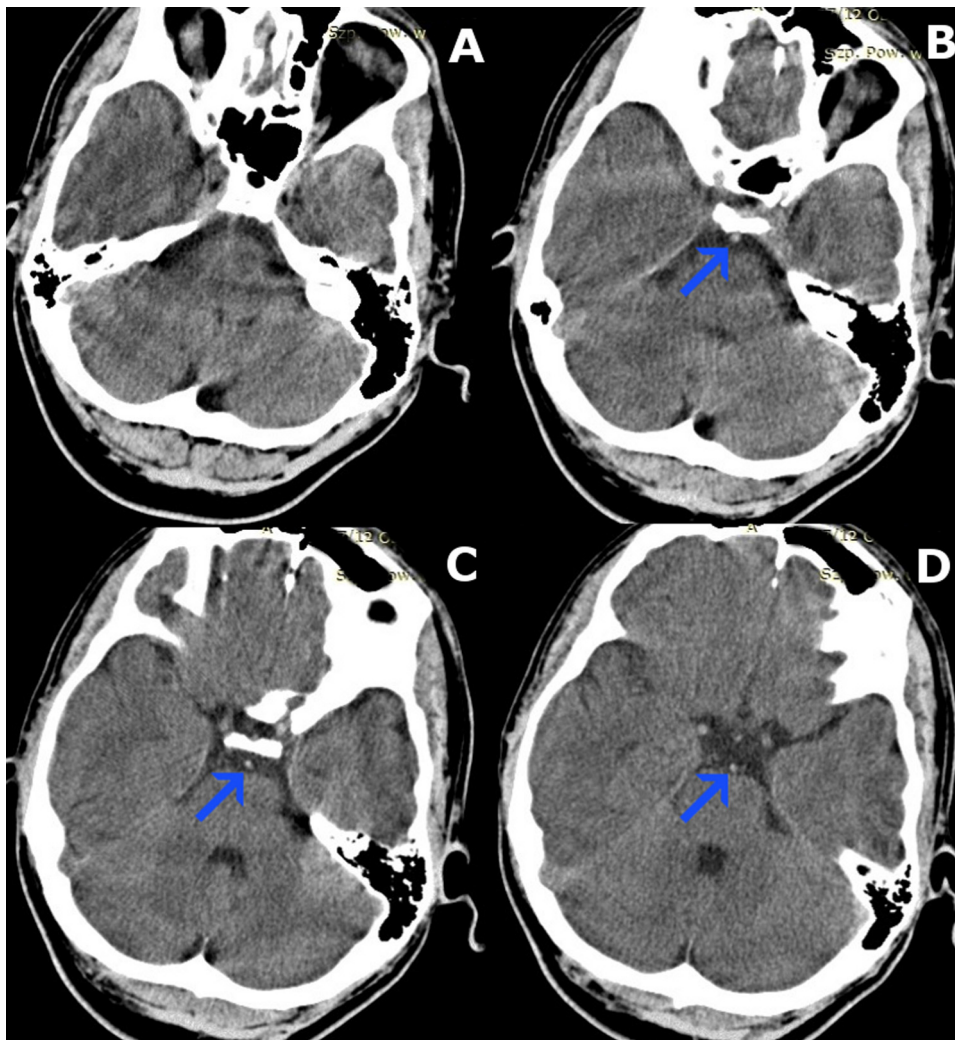


Fig. 1 – Computed tomography angiography (CTA). (B, C, D) Immediately after the onset of symptoms in municipal hospital, showing relative hyperdense basilar artery as compared to the middle cerebral arteries signifying acute thrombosis (arrowhead).

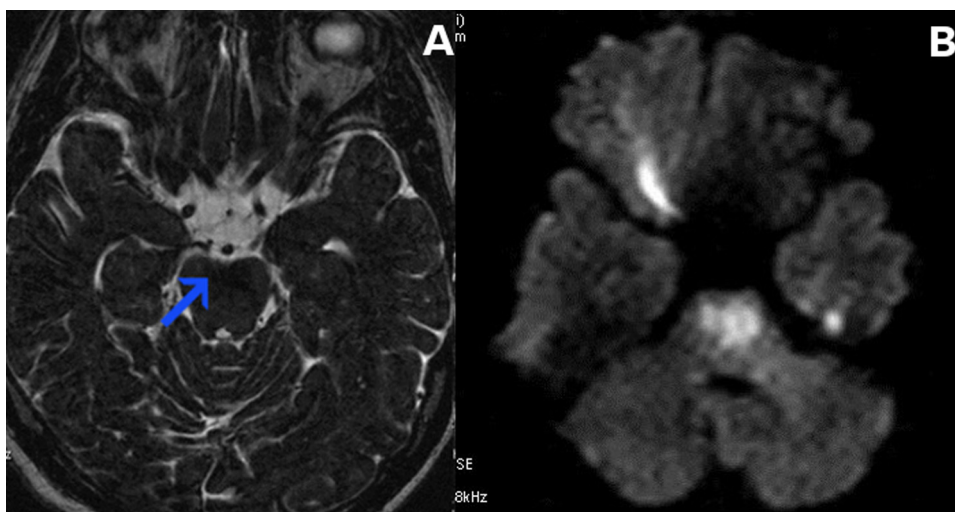


Fig. 2 – T2-weighted magnetic resonance imaging (T2-MRI) (A), diffusion weighted magnetic resonance imaging (DWI-MRI) (B). Image shows ischemic of the brainstem.

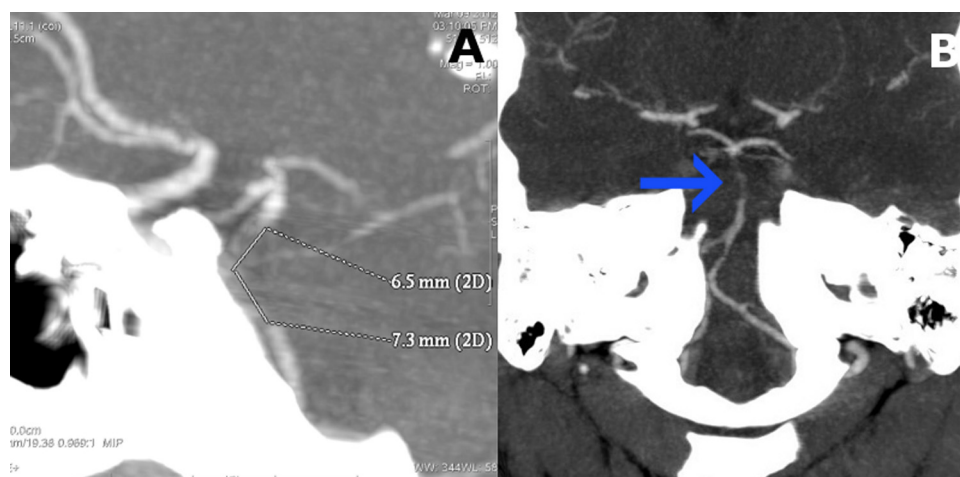


Fig. 3 – Computed tomography angiography (CTA). (A) No contrast enhancement in upper segment of the basilar artery, over the length of ca. 13.8 mm. (B) This points to a basilar artery occlusion or critical stenosis due to thrombosis (arrowhead).

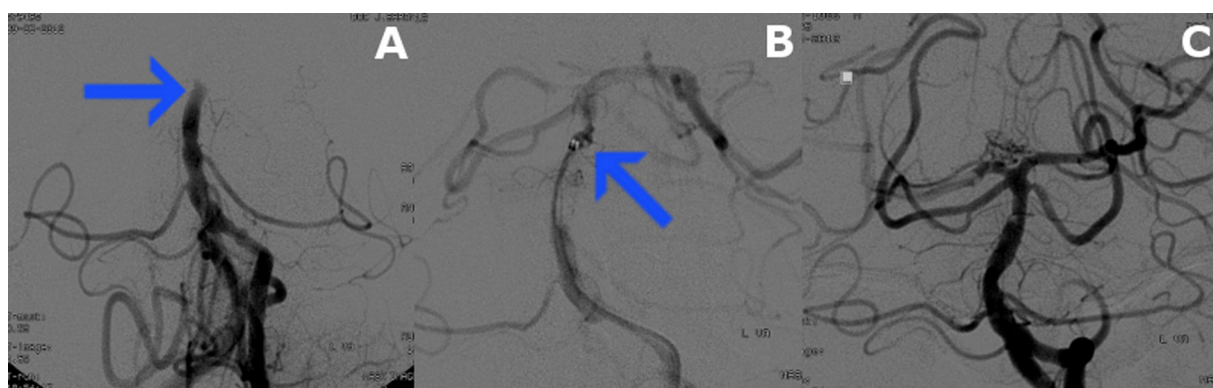


Fig. 4 – Digital subtraction angiography (DSA). (A) Basilar artery occlusion – status before the treatment (arrowhead). (B) Solitaire FR device in basilar artery – during the treatment (arrowhead). (C) Obtain a patency closed segment basilar artery – status after the treatment.

(2 on Lovette's scale) and a paresis of the right lower limb (3 on Lovette's scale), with an NIHSS score of 7 points. During hospitalization the patient's condition was stable, physical rehabilitation and speech therapy were implemented. Withdrawal of the right lower limb paresis was observed, followed by withdrawal of paresis of the proximal part of the right upper limb. Improved articulation and swallowing was achieved, feeding through a nasogastric tube was stopped. The patient was mobilized and was able to walk with assistance. The patient was discharged from the Department of Neurological Rehabilitation on 28th of May 2012, with a trace of distal upper limb paresis on the right side. Neurological symptoms assessed using the NIHSS scale were rated at 0/1 points, on the modified Rankin scale the patient scored 1 point.

Control MRI after 22 weeks after ischemic stroke

The MRI examination was performed using a Spectra 3.0 T in TSE (T1W, T2W), FLAIR, DWI and SWI sequences in sagittal, frontal and transverse planes, before and after contrast reinforcement (Omniscan). The scans revealed an area in the brainstem of high signal in T2 sequences, without enhancement after contrast. This may suggest post-stroke

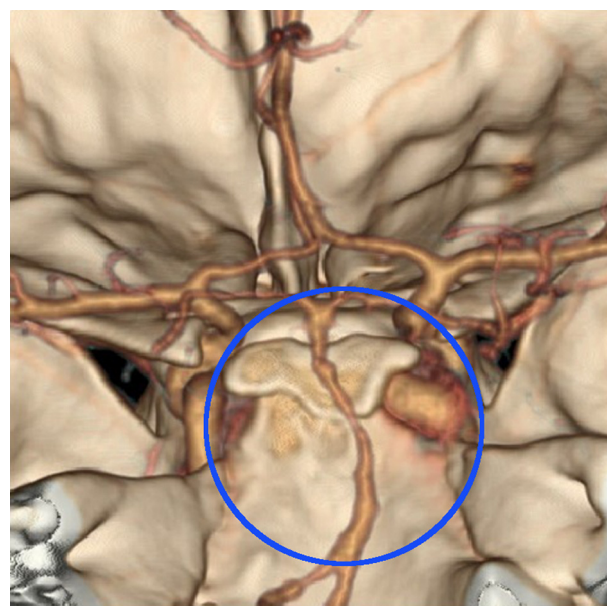


Fig. 5 – 3D Computed tomography angiography (3D-CTA). Obtain a patency closed segment basilar artery – status after the treatment (circle).

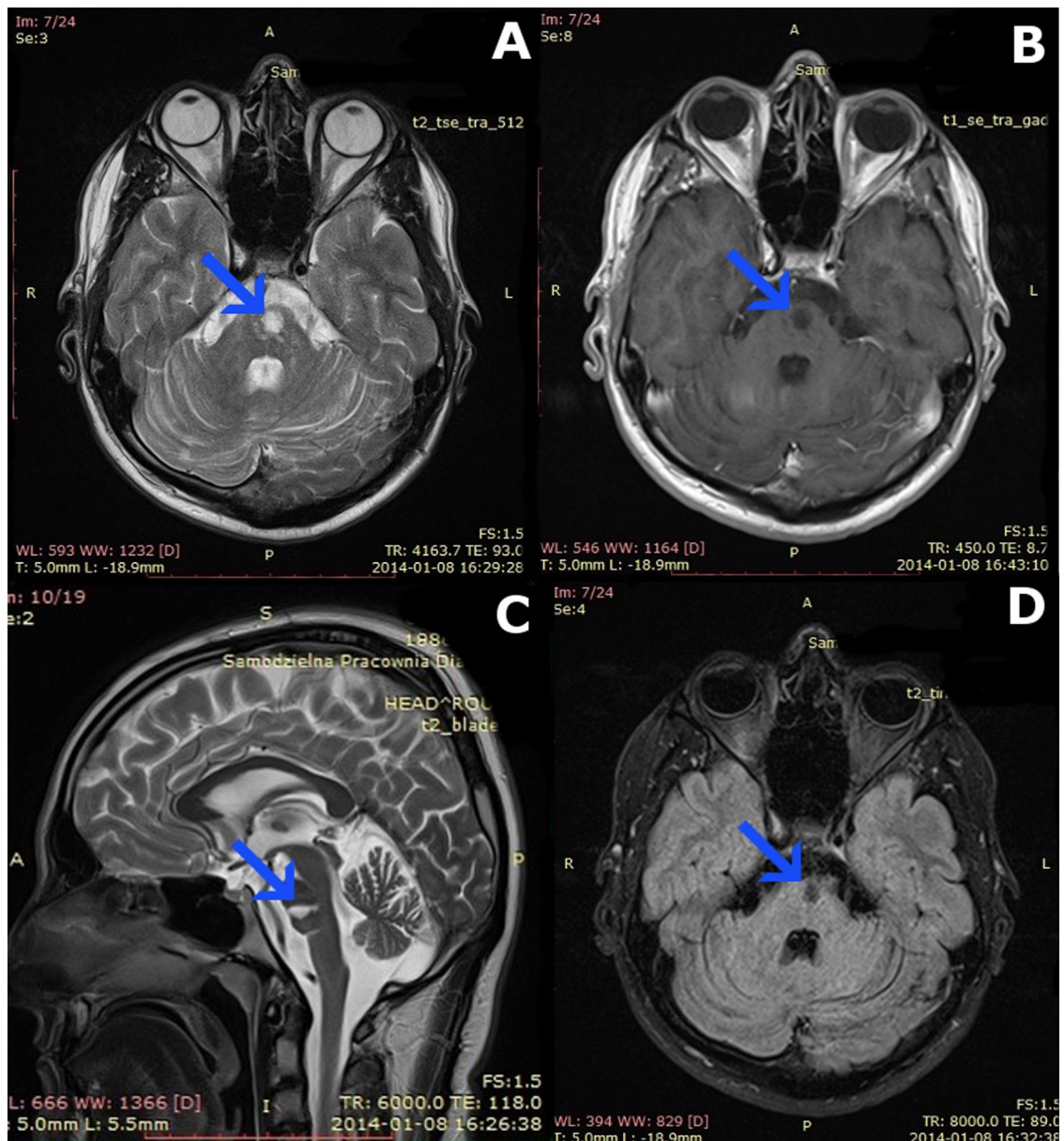


Fig. 6 – Magnetic resonance imaging (MRI). Control MRI after 22 weeks after ischemic stroke. (A, B, C, D) Post-stroke changes in the brain stem (arrowhead).

changes. In the lower part of the left cerebellar hemisphere a post-stroke area of approximately 18 mm in size was visualized. An enlarged fluid space was shown in this area, adjacent to the cerebellum, approximately 17 mm × 19 mm × 13 mm in size. Mild atrophy was visualized within the infratentorial structures. No focal lesions were revealed in the supratentorial structures. The ventricular system of the brain was symmetrical, non-dilated and non-displaced. There was no abnormal accumulation of contrast (Fig. 6).

Discussion

Ischemic stroke is the third leading cause of mortality in developed countries. Occlusion of the basilar artery is a

relatively rare case, making up approximately only 1% of all cases [1].

An analysis of clinical symptoms in course of basilar artery thrombosis, with or without an accompanying thrombosis of vertebral arteries, is found in available medical literature. Among these clinical symptoms are: hemiplegia, abnormal control of limb or body movement, confusion, vomiting, ataxia, headache, tetraparesis, disturbance in the field of vision, nystagmus, hemiparesis, surface and deep sensory disturbance, emotional lability [4]. Our patient experienced some of the symptoms listed above.

In cases of anterior inferior cerebellar artery and superior cerebellar artery occlusion, closure syndrome often occurs [5]. Prodromal symptoms such as dizziness, headache, nausea and vomiting occur in up to two-thirds of patients [3].

Stroke in young adults (before 45 years of age) represents merely 5–12% of all ischemic strokes. Consequences of stroke are enormous for young patients quality of life. Determination of risk factors is important for the strategy of treatment and secondary prevention. The most common risk factors of ischemic stroke in young adults are: cardioembolism (atrial fibrillation, patent foramen ovale, ischemic heart disease, cardiomyopathy, infective endocarditis, rheumatic valvular disease, mitral valve prolapse, atrial myxoma), other determined etiology (artery dissection, Moyamoya disease, migrainous infarction, essential thrombocythemia, hypercoagulable state, pregnancy-eclampsia, drugs, antiphospholipid syndrome, hyperhomocysteinemia, oral contraceptive, radiation angiopathy) and undetermined etiology. Non-modifiable risk factors for stroke in young patients are: sex, previous ischemic stroke or family history of stroke. Stroke in young adults between 20 and 30 years of age occurs more often in female patients and over 35 years of age in male patients. Some suggest that male sex carries the risk of more extensive ischemic changes in the brain, as well as worse response to treatment [6]. Greater overall mortality after endovascular procedures is observed in women [7]. Potentially modifiable risk factors for stroke are: hypertension, hyperlipidemia, diabetes, smoking and alcohol [8–11]. In our patient, 3 of the above risk factor were found (hypertension, hyperlipidemia and family history of stroke).

Ischemic stroke within the vasculature of the basilar artery is associated with severe complications, high risk of death or permanent disability. The main factor determining the prognosis and treatment efficacy is the time from the onset of symptoms to the implementation of therapeutic procedures. However, there are reports of effective basilar artery recanalization treatments significantly exceeding the therapeutic time window [12]. The most important factor determining the qualification of the patient for intravascular surgery is the time from the onset of stroke symptoms to the implementation of treatment: a maximum of 6 h for areas of carotid artery vascularization and 15 h for posterior circulation of the vertebral arteries and the basilar artery [6]. Other important criteria include age, neurological deficits at the time of qualification (less than 5 points and more than 25 points on the NIHSS scale) and a medical history which may suggest the cause of stroke.

Among endovascular techniques, mechanical thrombectomy using a Solitaire FR stent has proven to be the most effective [13]. It allows to quickly and safely restore blood flow through the basilar artery [2,14]. Numerous reports [1] indicate a high percentage of successful recanalization and good effects (mRS \leq 2) compared to other methods of mechanical thrombectomy and even in comparison with targeted thrombolysis [6]. Cardiovascular stents are also used in the treatment of basilar artery occlusion [1]. The extended time between hospital admission and the endovascular treatment did not affect the clinical success of our case.

Conclusion

Saving a patient with basilar artery occlusion is a difficult challenge. The last years have brought significant changes for patients suffering from BAO. In the past, the disease inevitably leads to disability and death. Survival rates of patients with

BAO are very low, even in group of patients who underwent endovascular treatment, and their return to independent functioning is very limited. Our case shows that the BAO tragic outcome may be avoided. The patient can return to full independence in everyday life, which is very rare in case of this disease.

Currently techniques for effective aid and for lengthening the time window are being developed. Intravenous thrombolysis with a very short time window of 4.5 h, which was used for a long time in the past, did not allow effective treatment. Endovascular techniques allow lengthening of the time window, especially mechanical thrombectomy, which enables effective treatment for up to 15 h.

Our case study of a patient with BAO shows medicinal value of treatment in an even longer time window.

Complete basilar artery patency may allow the patient full recovery and good social functioning. Recanalization achieved by mechanical thrombectomy with a Solitaire FR stent seems to be the best therapeutic option. However, we still need many more randomized studies to confirm these findings.

It is necessary to raise public awareness of the problem of stroke and their new treatments to allow patients to reach past the hospital. Also, adequate training of medical staff and increase the number of centers specialized in the treatment of cerebrovascular endovascular should improve the grim statistics stroke units in Poland. The inspiration for these activities can be seen in the vicinity example, namely the success of both social and medical in invasive cardiology. The high hopes being placed that the history and success of interventional radiology will be similar.

Conflict of interest

The authors wish to confirm that there are no known conflicts of interest.

Acknowledgements and financial support

The authors would like to acknowledge staff of the Department of Neurology and the Department of Radiology and Nuclear Medicine at Medical University of Silesia for patients data and all the assistance provided.

Our study was not financed by external funding.

Ethics

The work described in this article has been carried out in accordance with The Code of Ethics of the World Medical Association (Declaration of Helsinki) for experiments involving humans; Uniform Requirements for manuscripts submitted to Biomedical journals.

REFERENCES

- [1] Mattle HP, Arnold M, Lindsberg PJ, Schonewille WJ, Schroth G. Basilar artery occlusion. *Lancet Neurol* 2011;10:1002–14.

- [2] Yu W, Binder D, Foster-Barber A, Malek R, Smith WS, Higashida RT. Endovascular embolectomy of acute basilar artery occlusion. *Neurology* 2003;61:1421–3.
- [3] Voetsch B, DeWitt LD, Pessin MS, Caplan LR. Basilar artery occlusive disease in the New England Medical Center Posterior Circulation Registry. *Arch Neurol* 2004;61(4): 496–504.
- [4] Von Campe G, Regli F, Bogousslavsky J. Heraldng manifestations of basilar artery occlusion with lethal or severe stroke. *J Neurol Neurosurg Psychiatry* 2003;74:1621–6.
- [5] Piotin M, Blanc R, Kothimbakam R, Martin D, Ross IB, Moret J. Primary basilar artery stenting: immediate and long-term results in one patient. *AJR* 2000;175:1367–9.
- [6] The Polish Neurological Society, the Polish Society of Neurosurgeons. Postepowanie w udarze mózgu. Wytyczne Grupy Ekspertów Sekcji Chorób Naczyniowych PTN. *Neurol Neurochir Pol* 2012;46(1):28.
- [7] Meyers PM, Schumacher HC, Connolly Jr ES, Heyer EJ, Gray WA, Higashida RT. Current status of endovascular stroke treatment. *Circulation* 2011;123:2591–601.
- [8] Nedeltchev K, der Maur TA, Georgiadis D, Arnold M, Caso V, Mattle HP, et al. Ischaemic stroke in young adults: predictors of outcome and recurrence. *J Neurol Neurosurg Psychiatry* 2005;76:191–5.
- [9] Bell R. Stroke in young adults. *Intern Med* 1995;16:39–46.
- [10] Putaala J, Metso AJ, Metso TM, Konkola N, Kraemer Y, Haapaniemi E, et al. Analysis of 1008 consecutive patients aged 15 to 49 with first-ever ischemic stroke: the Helsinki young stroke registry. *Stroke* 2009;40(4):1195–203.
- [11] Tan KS, Navarro JC, Wong KS, Huang YN, Chiu HC, Pongvarin N, et al. Clinical profile, risk factors and aetiology of young ischaemic stroke patients in Asia: a prospective, multicentre, observational, hospital-based study in eight cities. *Neurol Asia* 2014;19(2):b117–27.
- [12] Wengui Y, Varoujan K, Fisher M. Endovascular recanalization of basilar artery occlusion 80 days after symptom onset. *Stroke* 2007;38:1387–9.
- [13] Kobayashi A. Endovascular approaches for acute ischaemic stroke: the current evidence and organizational issues. *Postep Kardiol Inter* 2012;8, 3(29):216–9.
- [14] Papanagiotou P, Roth C, Walter S, Behnke S, Politi M, Fassbender K, et al. Treatment of acute cerebral artery occlusion with a fully recoverable intracranial stent: a new technique. *Circulation* 2010;121:2605–6.